Volume : 5 | Issue : 5 | May 2016 • ISSN No 2277 - 8179 | IF : 3.508 | IC Value : 69.48

Research Paper

Caesarean Scar Pregnancy : An Uncommon Ectopic Implantation – A Case Report

Medical Science

KEYWORDS : Caesarean scar pregnancy, hysterectomy, catastrophic consequences

Suman Poddar	RMO cum Clinical Tutor, RG Kar Medical College, Kolkata
Rituparna Dutta	PGT, RG Kar Medical College, Kolkata
Indrani Dasgupta	PGT, RG Kar Medical College, Kolkata
Fuleswari Mahata	PGT, RG Kar Medical College, Kolkata

ABSTRACT

Caesarean scar pregnancy estimates about 1 in 2000 pregnancies. A post-caesarean pregnancy case was referred from rural hospital following 1st trimester failed medical termination with minimum symptoms. Diagnostic dilemma was created by different ultrasonography reports. Scar pregnancy was detected on laparoscopy at about-to-rupture stage. Hysterectomy was done unfortunately due to operative complication. Histopathological report confirmed product of conception within scar tissue. Timely intervention saved our case from catastrophic consequences.

INTRODUCTION

Implantation within prior caesarean section (CS) scar is an uncommon ectopic presentation but carries significant risks of catastrophic outcome due to rupture if not detected early. Since the first case of caesarean scar pregnancy (CSP) was reported in English medical literature in 1978[1], the most recent reviews cite the incidence to approximately 1 in 2000 pregnancies[2].

We are reporting our CSP case which was diagnosed at a stage threatening to rupture on laparoscopy following failed 1st trimester MTP & dilemma created by three different USG reports.

CASE PRESENTATION

A 31-year-old P_{1+0} lady was referred from a rural hospital as failed 1st trimester MTP case with suspected cornual implantation as per attached USG document. She had one living issue delivered by lower segment caesarean section seven months back due to oligohydramnios. MTP kit was prescribed by some unskilled practitioner in village after urine pregnancy test positive at 6 weeks gestation.

The patient was haemodynamically stable at our hospital emergency. Another USG done outside on the same day reported bulky uterus with a heterogenous SOL in lower uterine half with increased vascularity noted in left cornual area. Transabdominal scan done at our hospital revealed intrauterine gestation (6w2d) bulging through lower half of uterus with no cardiac pulsation.

With such diagnostic dilemma, laparoscopic evaluation was planned where a bluish mass with thinned out membrane protruding from lower segment of uterus was seen. Laparotomy decision was taken. On opening abdomen, a single approx. 5 x 7 cm mass was detected at about-to-rupture stage protruding from scar of previous caesarean section involving almost lower half of body of uterus upto cervix (Fig. 1).

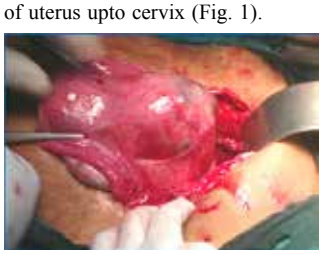

Fig. 1: Sac with thinned out surface protruding from CS scar area

Bladder flap was lowered down carefully, as the bladder was elevated significantly. Conservative surgery in the form of wedge excision was done initially. But wound / gap created was too large to close, edges were too friable & bleeding started; decision for hysterectomy was taken unfortunately after party counseling & consent as necessary procedure. Post-operative period was uneventful. Histopathological examination of the specimen revealed products of conception surrounded by scar tissue with chronic non-specific cervicitis (Fig. 2).

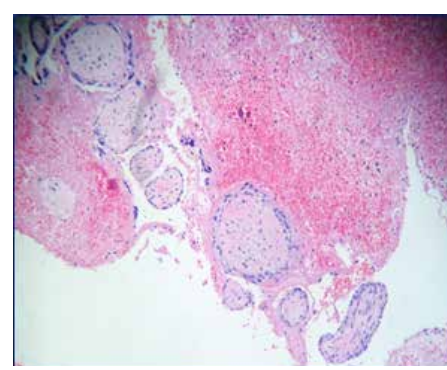

Fig. 2: HP showing syncytotrophoblast & cytotrophoblast within myometrium

DISCUSSION

There are two different types of CSPs. The first is an implantation on the prior CS with progression towards the cervicoisthmic space or the uterine cavity. The second is a deep implantation into a CS defect growing towards the bladder and abdominal cavity, a type that is more prone to rupture.

Very few cases reported in the literature progressed beyond 1st trimester[3] probably due to catastrophic consequences arising out of rupture in later months. There is also a danger of bladder invasion by the growing placenta. Our case was also in late 1st trimester and on the verge of rupture.

The exact etiology is not well known. The most probable explanation is trophoblastic invasion through microtubular tract into myometrium[4]. Hypothesis suggests that apart from prior caesarean scar, microscopic tracts can also stem from curettage, operative hysteroscopy, myomectomy, manual removal of placenta etc.

Volume : 5 | Issue : 5 | May 2016 • ISSN No 2277 - 8179 | IF : 3.508 | IC Value : 69.48

Ultrasound is the first-line diagnostic tool for CSP. The following ultrasound criteria[5] have been put forward for the diagnosis of a CSP:

- The uterine cavity is empty.
- The gestational sac is located anteriorly at the level of the internal os, covering the visible or presumed site of caesarean section scar.
- Doppler study suggests a functional placental circulation (Increased vascularity by colour flow evaluation, a peak velocity greater than 20 cm/s and a pulsatility index < 1 on pulsed Doppler).
- There is no 'sliding organ sign' which is the inability to displace the gestational sac from its level at the internal os with gentle pressure applied to the transvaginal probe.

In our case, USG was of prime importance before prescribing MTP kit. Afterwards also USG expertise was poor creating a diagnostic dilemma. Diagnostic laparoscopy, as in our case, has been often used for the diagnosis.

No consensus regarding preferred mode of treatment has been established till date, probably due to rarity of this condition. Options include systemic or local injection of methotrexate, either alone or combined with curettage or hysteroscopic removal; wedge resection of isthmic segment is another method.[6,7] Hysterectomy is also an acceptable and sometimes necessary option.[2] In our case, expectant or medical method was not thought of as sac was detected at the point of rupture with thinned out bluish membrane. Wedge resection & repair was tried but hysterectomy was done as a necessary procedure.

CONCLUSION

Literature regarding exact patho-physiology of caesarean scar pregnancy is lacking. More availability and expertise of USG are necessary specially in post-caesarean case monitoring.

Without a high index of suspicion and early diagnosis, like other ectopic pregnancies, this abnormal implantation can lead to early scar rupture and/or hysterectomy with subsequent significant maternal morbidity.

There is no universal agreement regarding best treatment protocol. More case reports are required and senior clinicians must be involved in making appropriate management plan and follow up.

REFERENCES

1. Larsen, J.V., Solomon, M.H. (1978). Pregnancy in a uterine scar sacculus: an unusual cause of postabortal haemorrhage. South African Medical Journal, 53, 142–3.
2. Sadeghi, H., Rutherford, T., Rackow, B.W. (2010). Caesarean scar ectopic pregnancy: case series and review of the literature. Am J Perinatol, 27, 111.
3. Jurkovic, D., Hillaby, K., Woelfer, B., Lawrence, A., Salim, R., Elson, C.J. (2003). First trimester diagnosis and management of pregnancies implanted into the lower uterine Caesarean section scar. Ultrasound Obstet Gynecol, 21, 220–7.
4. Godin, P.A., Bassil, S., Donnez, J. (1997). An ectopic pregnancy developing in a previous caesarean section scar. Fertil Steril, 67, 398–400.
5. Seow, K.M., Huang, L.W., Lin, Y.H. (2004). Caesarean scar pregnancy: issues in management. Ultrasound Obstet Gynecol, 23, 247.
6. Wang, J.H., Xu, K.H., Lin, J. (2009). Methotrexate therapy for caesarean section scar pregnancy with and without suction curettage. Fertil Steril, 92, 1208.
7. Yang, Q., Piao, S., Wang, G. (2009). Hysteroscopic surgery of ectopic pregnancy in the caesarean section scar. J Minim Invasive Gynecol, 16, 432.