ORIGINAL RESEARCH PAPER

Volume-8 | Issue-1 | January-2019 | PRINT ISSN No 2277 - 8179

INTERNATIONAL JOURNAL OF SCIENTIFIC RESEARCH

CASE REPORT: A RARE CASE OF VENTRICULAR TACHYCARDIA FOLLOWING VIPER BITE.

General Medicine

Lt Col Dr. N Rishikanta Classified Specialist (Internal Medicine), 166 Military Hospital

Maj Dr. Vipin Sukumaran* Graded Specialist (Anaesthesiology), 168 Military hospital *Corresponding Author

ABSTRACT

Snakebite is a frequently encountered health problem in rural areas of india. Viper bite usually leads to bleeding disorders and nephrotoxicity. Cardiac manifestations are rare manifestation of Viper's bite. The most common cause of cardiac toxicity is direct toxic effects of snake venom on myocardium. A young male who presented with snake bite developed ventricular tachycardia and cardiac arrest. He was succefully treated by anti snake venom and antiarrhythmic drugs. Subsequently, he was discharged from hospital in a healthy condition.

KEYWORDS

Snake bite, Ventricular tachycardia

Introduction

Snake bite is a common medical emergency encountered in rural parts of our country and Armed Forces personal serving in field areas due to deployment in areas where snakes are found in plentiful. As many as 2,00,000 snake bites occurs annually and 50,000 people die from snake bite every year in India [1]. Manifestations of venomous bite may range from mild local symptoms to life threatening coaguloapathy, haemorrhagic manifestations, acute kidney injury, cardiotoxicity and neurotoxicity [2,3,4]. Neurotoxic envenomation may lead to respiratory paralysis requiring ventilatory support together with ASV. Cardiac involvement in snake bite is a rare presentation and usually presents as hypotension, arrhythmias, myocardial infarction, ST segment changes and QRS prolongation [5,6]. Life threatening arrhythmias are relatively uncommon. The cause of cardiotoxicity is basically due to direct effect of toxin on the myocardium, coagulation abnormalities and vasospasm induced by the toxin [7]. One case of venomous snake bite presenting with ventricular tachycardia is being reported in a military hospital in Northern sector of our country.

Case report

A 32 years old male with no medical co-morbidities was brought to the Accident & Emergency department of a peripheral army Hospital with alleged history of snake bite over the left foot. The snake ran away after biting the patient. The patient reported to the A& E department within 45 minutes of the bite with severe giddiness and inability to walk. On local examination the patient had swelling over medial aspect of left foot and two fang marks were visible over the region. On general examination patient was restless with cold peripheries. His Blood pressure was not recordable with a feeble pulse and rate of 170/minute. His respiratory rate was of 30 per minute and room air Oxygen saturation was 88%. He was immediately started on IV fluids, Oxygen with face mask and was shifted to the ICU. An ECG done revealed monomorphic ventricular tachycardia with a ventricular rate of 168 per minute. He was immediatetly given a bolus dose of Injection Amiodarone 200 mg slow IV which resulted in reversal to sinus rhythm within few minutes. Further evaluation revealed a deranged 20 minutes WBCT and a deranged INR of 1.8 suggestive of vasculotoxicity due to possible viper bite. He wa immediately started on ASV.

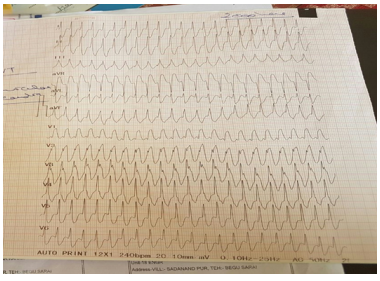

Figure 1: Shows initial rhythm of monomorphic ventricular tachycardia in the patient on presentation

The patient however had a severe anaphylaxis to the ASV and was immediately managed with Inj Adrenaline, Inj Hydrocortisone 200mg, Inj Avil and Inj Ranitidine Adrenalin. His PT INR worsen to 2.4 over the next 2 hours. He continued to have reaction to ASV despite repeated doses of Inj Adrenaline. Finally he was given 200 ml of ASV under the cover of Inj Adrenallin infusion at the rate of 0.6ml/kg/hr and 4 units of FFP for the deranged INR. Inj Amiodarone infusion was continued at the rate of 1mg/min for 8 hours and then at the rate of 0.5mg/min for next 16 hours. Various other parameters like Liver function tests, Renal function tests, D-Dimer and FDP were normal.

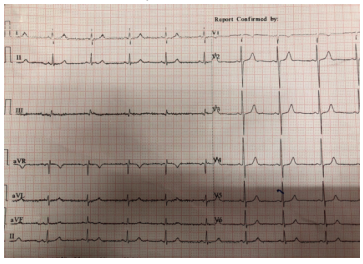

Figure 2: Shows ECG with Normal sinus rhythm in the same patient 4 hours after initiation of Anti snake venom and Inj Amiodarone infusion

Discussion

Snake Bite is a frequently encountered health hazard in tropical and subtropical countries. It is more commonly found in rural areas. In the setting of Armed forces in india it usually affects troops serving in field areas. Approximately 450 species of snakes found worldwide are considered to be poisonous. Among those 52 poisonous species are found in India. The most common poisonous snakes found in india are Ophiophagus hannah (king cobra), Naja naja (common cobra), Daboia ruselli (Russell's viper), Bungarus caeruleus (krait) and Echis carinatae (saw-scaled viper) [8,9].

Snake venom is known to mankind from ancient times and is described as a poison in mythical books. The snake venom contains various enzymes like digestive hydrolases, hyaluronidase, L-amino acid oxidase, 5'-nucleotidase, DNAase, Nucleosidase, phospholipase A2, and peptidases. It also contains hemorrhagins, neurotoxins and cardiotoxins. Venomous snakes are classified by the type of their toxin and the organ system affected by the toxin. But it has been noticed that the poison of most venomous snakes affects multiple organ systems [10].

Viper is one of the most common poisonous species of snake found in india. The bite of a viper normally leads to coagulopathy but other clinical manifestations like local swelling, local necrosis, neurotoxicity, nephrotoxicity, cardiac effects and myotoxicity also occur [11]. Viper venom contains various procoagulants which activate the clotting cascade in other animals. Phospholipase A2 is the most common venom enzyme which can be found in a viper's venom.

It is responsible for most of the complications associated with viper bite [12]. Cardiovascular complications following viper bite are rarely reported in the past. One study from India by Nayak KC et al indicates hypotension, ST segment changes, acute myocardial infarction and hyperkalemia following viper bite [13].

In a study conducted by Ramakrishna CD et al from pariyaram medical college, kerala it was found that among 200 patients of snake bite treated, heart rate disturbance was present in 16.5 percent out of which 13.5% had tachycardia and 3% had bradycardia. Ventricular tachycardia was found only in one patient among the 200 patients [14]. In a study conducted by Reid et al description has been given about the systemic effects of viper bite [15]. A case report presented by Virmani SK showed atrial fibrillation in an elderly woman with snake bite. She was treated with xylocaine and anti snake venom. Serial ECG showed reversal to sinus rhythm in 48 hours [16]. Case report by Thillainathan et al showed viper bite leading to ECG changes suggestive of myocardial infarction and atrial fibrillation. This was mainly due to coronary vasospasm [17].

In our case report it is highly possible that direct toxic effect of snake venom would have damaged the myocardium and would have triggered the ventricular tachycardia. Components of snake venom are shown to interfere with the electrophysiological properties of cardiac conduction system and trigger various life threatening arrhythmias. Modifications of Cardiac cell membrane conduction properties by toxins will lead to arrhythmias [18,19]. In majority of the cases of snake bite it is noticed that the sympathetic response to fear of death is responsible for cardiac rhythm disturbances [8].

Conclusion

A patient with viper can have cardiac complications in addition to the coagulopathy and local manifestations. Cardiac rhythm abnormalities occur following viper bite as a result of direct effect of toxin on myocardium or due to interference of toxin with the electrophysiological properties of cardiac cell membrane. Every Clinician should be aware of this rare complication while treating a case of snake bite. In our patient the life threatening ventricular tachycardia and cougulopathy was managed timely with Intravenous antiarrhytmic drugs and ASV with an uneventful recovery.

REFERENCES

1. Warrell DA. *Guidelines for the clinical management of snake-bites in the south-east Asia region*. New Delhi: World Health Organization, Regional Office for South East Asia, 2005, pp. 1–67.
2. Warrell DA. Snake venoms in science and clinical medicine. 1. Russell's viper:biology, venom and treatment of bites. *Trans R Soc Trop Med Hyg* 1989; 83(6): 732–740.
3. Cherifi, F. and Laraba-Djebari, F. (2013) Isolated Biomolecules of Pharmacological Interest in Hemostasis from Cerastes Cerastes Venom. The Journal of Venomous Animals and Toxins Including Tropical Diseases, 19, 11.
4. Reid, H.A. (1975) Bites and Stings in Travellers. Postgraduate Medical Journal, 51, 830-837.
5. Brown, R. and Dewar, H.A. (1965) Heart Damage following Adder Bite in England. British Heart Journal, 27, 144-147.
6. Blondheim, D.S., Plich, M., Berman, M., Khair, G., Tzvig, L., Ezri, J. and Marmor, A.T. (1996) Acute Myocardial Infarction Complicating Viper Bite. The American Journal of Cardiology, 78, 492-493.
7. Maduwage, K. and Isbister, G.K. (2014) Current Treatment for Venom-Induced Consumption Coagulopathy Resulting from Snakebite. PLoS Neglected Tropical Diseases, 8, e3220.
8. Kasturiratne, A., Wickremasinghe, A.R., de Silva, N., Gunawardena, N.K., Pathmeswaran, A., Premaratna, R., Savioli, L., Lalloo, D.G. and de Silva, H.J. (2008) The Global Burden of Snakebite: A Literature Analysis and Modelling Based on Regional Estimates of Envenoming and Deaths. PLoS medicine, 5, e218.
9. Kang, S., Moon, J. and Chun, B. (2016) Does the Traditional Snakebite Severity Score Correctly Classify Envenomated Patients? Clinical and experimental emer- gency medicine, 3, 34-40.
10. Hung DZ, Wu ML, Deng JF, Lin-Shiau SY. Russell's viper snakebite in Taiwan: differences from other Asian countries. Toxicon 2002; 40: 1291-8.
11. Kularatne SA. Epidemiology and clinical picture of the Russell's viper (Daboia russelii russelii) bite in Anuradhapura, Sri Lanka: a prospective study of 336 patients. Southeast Asian J Trop Med Public Health 2003; 34: 855-62.
12. Warrel DA. Injuries, envenoming, poisoning and allergic reactions caused by animals. In: Ledingham JGG, Warrel DA, editors. Concise Oxford textbook of medicine. New York: Oxford University Press, 2000: 1889-901.
13. Nayak KC, Jain AK, Sharda DP, Mishra SN. Profile of cardiac complications of snake bite. Indian Heart J 1990; 42: 185-8.
14. Ramakrishna C.D. and Kanattu, P.S. (2017) A Study of Car- diac Profile in Patients with Snake En- venomation and Its Complications. Inter- national Journal of Clinical Medicine, 8, 167-177.
15. Reid, H.A. (1975) Bites and Stings in Travellers. Postgraduate Medical Journal, 51, 830-837.
16. SK Virmani. Cardiac involvement in snake bite. Med J Armed Forces India. 2002;58(2):156-57.
17. Thillainathan S, Priyangika D, Marasinghe I, Kanapathippillai K, Premawansa G. Rare cardiac sequelae of a hump-nosed viper bite. BMC Research Notes.2015;8:437.
18. Aravanis C, Ioannidis P, Ktenas J. Acute myocardial infarction and cerebrovascular accident in a young girl after a viper bite. Br Heart J. 1982;47:500–03.
19. Agarwal A, Kumar T, Ravindranath K, Bhat P, Manjunath C, Agarwal N. Sinus node dysfunction complicating viper bite. Asian Cardiovascular and Thoracic Annals. 2015;23(2):212-14.