Volume : 5 | Issue : 12 | December-2016 • ISSN No 2277 - 8179 | IF : 3.508 | IC Value : 78.46

Original Research Paper

CASE SERIES STUDY OF FOCAL LIVER LESIONS USING MDCT AND USG

Radiology

KEYWORDS: : Focal liver lesions , multi detector CT , ultrasound ,liver abscess , hepatocellular carcinoma, metastasis.

Dr B. Venkateswarlu Professor of Radiology ASRAM medical college, Eluru W.G.Dist, 534005, A.P

Dr. K.Durga Mounika Postgraduate of Radiology ASRAM Medical College , ELURU W.G.Dist, 534005, A.P

ABSTRACT

The aim of this study was to evaluate the role of ultrasound and MDCT in evaluation of focal liver lesions, to study the imaging spectrum of focal hepatic lesions, to study the relative prevalence of different focal hepatic lesions, and to correlate the ultrasound and CT findings with FNAC and/or follow up scans. Liver is the largest organ in the abdomen, having a number of important functions. There is no single test by which liver can be stated to be normal. Hence laboratory tests and imaging modalities are necessary for complete evaluation of structure and function of the liver.

INTRODUCTION

Characterization of various hepatic lesions is of great therapeutic and prognostic relevance and has thus been one of the focuses of multiple imaging research studies. With the widespread use of cross-sectional imaging, a growth in rate of incidentally detected focal liver lesions (FLL) has been observed. A reliable detection and characterization of FLL is critical for optimal patient management.

A tremendous development of new imaging techniques has taken place during these last few years. Maximizing accuracy of imaging in the context of FLL is paramount in avoiding unnecessary biopsies, which may result in post-procedural complications. Although it would appear that the most absolute method of diagnosing a hepatic lesion may be biopsy or pathologic examination of a resected specimen, the increased sensitivity of imaging techniques and the increasing experience among radiologists in interpreting these studies largely mitigate the need for this relatively high-risk procedure.

This study assess the usefulness of USG and MDCT scan in depicting the status of various focal liver lesions and correlate them with FNAC/Biopsy/Surgical findings/ Follow-up.

AIMS AND OBJECTIVES

1. Asses the role of ULTRASOUND in detection and characterization of these focal liver lesions.

2. Asses the role CECT in detection and characterization of focal lesions in liver.

3. To evaluate the sensitivity and specificity of ULTRASOUND and CT in these pathologies.

4. To assess which modality is more accurate in a particular pathology.

MATERIALS AND METHODS

Cases for the above-proposed study were collected from allure sitharamaraju academy of medical sciences Clinical history or physical examination suggestive of a focalliver lesion which is confirmed by ULTRASOUND/CT.

Focal liver lesion incidentally detected on abdominalULTRASOUND or CT.

The investigation was be performed with PHILIPS USGMACHINE HD 11XE & SIEMENS SOMATOM 40 SLICE CT.

OBSERVATIONS AND RESULTS

The total number of patients included in our study were 50(n - 50)

REPRESENTS AGE AND SEX DISTRIBUTION OF PATIENTS

Age	Sex					
	Female		Male		Total	
	Count	%	Count	%	Count	%
21-30	1	5.3%	1	3.2%	2	4.0%
31-40	2	10.5%	2	6.5%	4	8.0%
41-50	3	15.8%	12	38.7%	15	30.0%
51-60	9	47.4%	6	19.4%	15	30.0%
61-70	2	10.5%	7	22.6%	9	18.0%
71-80	2	10.5%	3	9.7%	5	10.0%
Total	19	100.0%	31	100.0%	50	100.0%

USG FREQUENCY OF 50 FOCAL LESIONS

USG	Frequency	Percent(%)
ABSCESS	16	30.0
METASTASES	10	20.0
HEMANGIOMA	9	18.0
CYST	6	12.0
HCC	5	10.0
HYDATID CYST	2	4.0
IHBRD WITH DIFFUSE LESION	2	4.0
Total	50	100.0

CT FREQUENCY OF 50 FOCAL LESIONS

CT	Frequency	Percent(%)
ABSCESS	16	32.0
METASTASES	11	22.0
HEMANGIOMA	10	20.0
HCC	5	10.0
CYST	3	6.0
HYDATID CYST	3	6.0
CHOLANGIO CARCINOMA	2	4.0
Total	50	100.0

FREQUENCY BASED ON FINAL GOLD STANDARD DIAGNOSTIC METHOD

GOLD STANDARD	Frequency	Percent(%)
ABSCESS	15	30.0

Volume : 5 | Issue : 12 | December-2016 • ISSN No 2277 - 8179 | IF : 3.508 | IC Value : 78.46

METASTASES	11	22.0
HEMANGIOMA	10	20.0
HCC	5	10.0
CYST	4	8.0
HYDATID CYST	3	6.0
CHOLANGIO CARCINOMA	2	4.0
Total	50	100.0

SONOGRAPHIC AND CT AAPPEARANCEOF FOCL LIVER LESIONS AMOEBIC ABSCESS

USG: All cases of amoebic abscess showed round or oval shape.Seven cases were hypoechoic with low level internal echoes and showed distal sonic enhancement. Remaning (four) lesions were hypoechoic/heteroechoic with dense internal echoes. Most are located in subdiaphragmatic region of right lobe. In one case there was a break in the abscess wall. The cystic nature of abscess was more easily appreciated on US than on CT in evolving abscess.

CT: Most of the lesions(nine) were hypodense (CT VALUE 14 – 22HU) and few(2) were heterodense .100% of lesions had enhancing wall.

Sensitivity and specificity of USG and CT for abscess in our study was 100% Ramamohan et al 1in(1989) his study of liver abscess, encountered more frequently amoebic liver abscess than PLA. On comparing the two lesions, they found that amoebic liver abscess is bigger in size, occur peripherally, predilection for right lobe but PLA is smaller in size and more frequent in left lobe.

PYOGENIC ABSCESS

USG : 90% pyogenic abscesses had round shape. Distal sonic enhancement was seen in two cases. Two cases showed echogenic foci with posterior reverberation artifact suggestive of gas. The abscess wall was thick and irregular in one case.

CT :Most of the lesions were hypoattenuating, one lesion was heterodense and showed peripheral thick enhancing wall.

Sensitivity and specificity of USG and CT for abscess in our study was 100%.



CECT abdomen showing multiple hypoechoic lesions with peripheral enhancement in both lobes of liver .

Dewbury K.C et al[2] found that an isolated focallesion in the right lobe of liver with a peripheral echo free halo, irregular central echo poor areas and with distal acoustic enhancement , is most likely to be an abscess in its early stageof formation . If repeat scan within a week shows progressivechanges , it is almost certain to be a liver abscess

METASTASIS

USG**:** The metastatic lesions from carcinoma rectum were hypoechoic with target pattern.The lesions from cervical carcinoma were hyperechoic in our study.

And the lesions from the stomach, breast, gall bladder and prostate were hypoechoic with few showing target pattern.Cystic metastases was seen in only one case in our study.

CT: Eight (73%) cases were hypoattenuating and the rest were heterogeneous. All the lesions showed enhancement on CECT.

Sensitivity and specificity of USG in our study were 91 % , 100% and of CT were and 100% , 100% respectively.

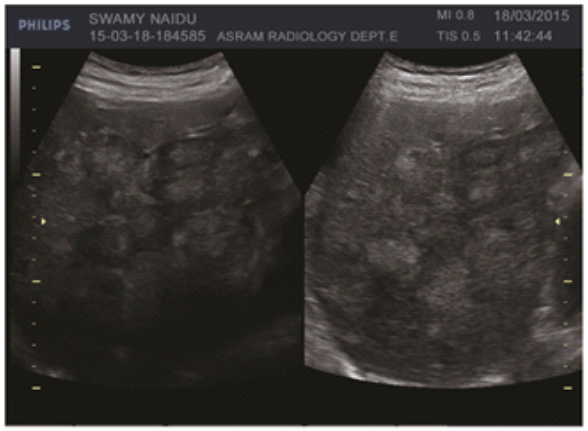

USG showing multiple round to oval hyperechoic lesions involving both the lobes of the liver showing target appearance.

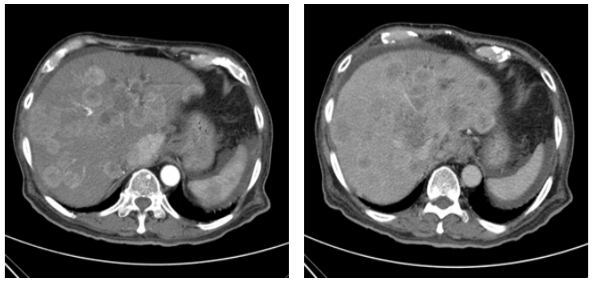

CECT shows Multiple Heterogeneously Iso to Hypodense lesions with progressive centripetal filling on contrast studies

Withers C.E and Wilson S.R[3] concluded in their study of sonographic patterns of metastatic liver disease that hypoechoic metastases is generally hypovascular and is the typical pattern seen in metastatic breast or lung cancer. The bulls eye or target pattern is characterized by a peripheral hypoechoic zone. The findings in our study were comparable to this observation.

HEMANGIOMA

USG: Sharply defined highly reflective round tumor with a homogeneous echopattern lesions larger than 2.5cms showing post acoustic enhancement.

CT : The lesion shows typical centripetal type of enhancement pattern on CECT study. Starts with peripheral nodular enhancement in the early phases and shows typical centripetal enhancement on delayed scan.

Sensitivity and specificity of USG for hemangioma in our study were 90% and 100 % respectively and of CT is 100% both.

Bree et al [4] (1983)studied solitary echogenic spot in the liver subsequently proved to be cavernous hemangioma in 26 asymptomatic patients without known neoplasms. Their echogenicity is due to multiple interfaces between the walls of cavernous sinuses and blood within them. The CT appearance of cavernous hemangiomas has been described as spherical

hypodense mass on native scan and on CECT within the first 4 min. There is a circumferential ring of increased density.[22] this gives edge enhancement with delayed central opacification. The tumor does not give edge enhancement exceeding to the surrounding liver. The angiographic appearance of cavernous hemangioma is diagnostic. No other hepatic lesion produces a ring like cluster of hypervascularity that persists into the late venous phase of the angiogram and up to 30 sec after injection. The diagnostic criteria should be in a patient without known neoplasm elsewhere, or who is asymptomatic, dynamic CT after sonography is suggested. If, CT is not characteristic, angiography and / or aspiration biopsy is suggested.

HEPATOCELLULAR CARCINOMA

USG**:** 60% HCCs were hypoechoic and 40% were heterogeneous .Calcification was not seen in any case on US. Sensitivity and specificity were 90% and 100 % respectively.

CT: 80 % HCCs were heterogeneous in density and 20% were hypodense. All the lesions showed early heterogeneous enhancement in early phases and showed early wash out in delayed phases.

Sensitivity and specificity was 100%. Chou R, Cuevas C, Fu R, Devine B, Wasson N, Ginsburg A, et al [5]. Imaging Techniques for the Diagnosis of Hepatocellular Carcinoma (2015) In conclusion, CT and MRI are associated with higher sensitivity than ultrasonography without contrast for detection of HCC; sensitivity is higher for MRI than for CT. For evaluation of focal liver lesions, the sensitivities of ultrasonography with contrast, CT, and MRI for HCC seem to be similar. Across imaging modalities, sensitivity was low for small and well-differentiated lesions. Research is needed to understand the effects of test performance differences on clinical outcomes.

HEPATIC CYSTS

USG :The typical appearances of simple cysts were seen in all cases i.e. anechoic, with a well - defined thin wall and posterior acoustic enhancement.

Complicated cysts seen in one case and they appeared on USG as well defined cystic lesion with thin internal septations and uniform low level internal echoes.

CT : They appeared as well defined non enhancing lesions with attenuation values of water density. Complicated cyst had attenuation values slightly more than water density and were well defined with thick wall and internal septations which showed minimal enhancement on CECT.

Sensitivity and specificity of USG were 100% and CT were 75 % and 100% respectively in our study for cysts. And the findings were consistent with the following studies from Literature.

Spiegel et al [6](1978) summarized the established ultrasonic criteria of a simple hepatic cyst Must be i)anechoic, ii) Must have smooth borders and strong posterior wall echoes, iii) Must be spherical or oval in shape iv) Must show relative accentuation of echoes beyond the cysts. Author's study indicates that USG is the most accurate modality for diagnosing primary cysts of the liver and it should be considered the imaging modality of choice for the diagnosis of hepatic cysts. It can accurately locate primary cysts within the liver as well as determine their internal morphology. The most common single location is the lower edge of the right lobe of liver.

HYDATID CYST

USG : All cysts had well defined margins. On USG a multiseptated cyst with daughter cysts and echogenic material between the cysts (characteristic appearance) was seen in two (66.6%) cases. Cyst with internal septae and wall calcification was seen in one (33.3%) case.

CT :Well definedhypoattenuating lesions with daughter cysts were seen in two cases (66.6%).

In one case daughter cysts were not seen, only few septae with calcification were (33.3%).

Tankut et al [7] (1988)coined "Ball of Wool" or Yarn sign - ultrasonographic sign for the diagnosis of hydatid cyst which looked as a series of echogenic and echo lucent layers arranged in different ways and oriented differently at the side of lesion. This is due to separation of germinal layer from the inner side of cyst and folding several times in a limited space in the cyst cavity.

OTHER FOCAL LIVER LESIONS

Cholangio carcinoma was seen in only two case. In both the USG revealed mild hepatomegaly and mild peripheral and central intra hepatic biliary radicals dilatation.USG showed an ill definediso to hypoechoic lesions mostly confined to the hepatic confluence. On CECT abdomen all the cases showed there was an ill defined mass in both lobes of the liver where it was showing delayed enhancement and delayed washout which is quite opposite to HCC. So the probability of Cholangiocarcinoma is to be considered as first diagnosis followed by HCC. CT guided FNAC was done and proved to be cholangio carcinoma. One case was seen in 6th decade and another case in 7th decade.

HISTOPATHOLOGY FINDINGS

In our study histopathology findings played a supportive andconfirmatory role in characterizing the lesions especially inpatients with liver metastasis , HCC, Cholangio carcinoma , cysts andliver abscess.

FOLLOW UP STUDY

Follow up ULTRASOUND/CT was very important in obviouslybenign lesions in order to avoid unwanted surgeries and biopsies.Follow up was done in most of the patients with benign lesionslike simple liver cysts, hemangiomas and abscesses. The patients
with neoplastic disease underwent definitive treatment

CONCLUSION

- CECT and USG have high sensitivity and specificity in diagnosing liver abscess. Hence one of the two imaging modalities would be sufficient for diagnosing it as abscess.
- However Imaging features to differentiate amoebic versus pyogenic abscess are non specific on either imaging modality, and require needle aspiration cytology for confirmation. However, subsequent to treatment , follow-up is easier with ultrasound.
- USG has sensitivity and specificity comparable to that of CECT in diagnosing liver metastases. CT is superior to USG in showing exact extent of a focal lesion and in evaluating adjacent organs. Hence CT is useful to determine the extent of the liver tumors or hydatid cysts prior to surgical resection.
- Using CECT there is a high degree of sensitivity and specificity (up to 100%) in lesions such as hemangioma, which have specific enhancing pattern. USG is non - specific in diagnosis of large hemangiomas
- CECT is superior in diagnosing HCC and CC because of their typical enhancement patterns.
- Simple liver cysts have typical appearances on USG as well as CT.
- So in essence USG and CT are the modalities having comparable specificity and sensitivity, CT being slightly more accurate than USG in evaluation of focal hepatic lesions.
- Though CECT has various advantages over USG, in developing countries like India it may be easier to perform USG initially

Volume : 5 | Issue : 12 | December-2016 • ISSN No 2277 - 8179 | IF : 3.508 | IC Value : 78.46

because of its wide availability, cost effectiveness, non invasiveness and free from radiation.

- CT scan may be performed in

1) atypical cases where ultrasound is not confirmatory and
2) to know exact extent of the lesion prior to surgery.

- As a follow up modality, in most situations USG may be adequate.

REFERENCES

1. Ramamohan C, Pramod Kumar Reddy, Manohar K. Sonographic evaluation of liver abscess. Ind J RadiolImag. 1989; 43(3): 312- 215. Dewbury KC
2. Joseph AE, Millward Sadler GH, Birch SJ:Ultrasound in the diagnosis of the early liver abscess: BJR 1980 ; 53:1160-1165.
3. Withers C,WilsonSR.Theliver..InRumackC,WilsonS,Charboneau J : Diagnostic Ultrasound. St Louis,MosbyYear Book,1991.
4. Bree RL, Schwab RE, Neiman HL. Solitary echogenic spot in the liver: is it diagnostic of a hemangioma . AJR Am J Roentgenol 1983; 140:41–45.
5. Chou R, Cuevas C, Fu R, Devine B, Wasson N, Ginsburg A, et al. Imaging Techniques for the Diagnosis of Hepatocellular Carcinoma: A Systematic Review and Meta-analysis. Ann Intern Med. 2015;19:162 (10):697-711.
6. RM Spiegel, DL King and WM Green ultrasonography of primary cysts of the liver 1978; 131: 235-238. Tankut liter
7. M.D, ÖzgülÖzgüven M.D, Namik K. Mentes M.D:Ball of wool or yam sign:a new ultrasonographic sign for diagnosis of hydatidcyst.BJR 1988; 58- 695.