ORIGINAL RESEARCH PAPER

Volume-7 | Issue-8 | August-2018 | PRINT ISSN No 2277 - 8179

INTERNATIONAL JOURNAL OF SCIENTIFIC RESEARCH

CHOROIDAL METASTASES AS INITIAL MANIFESTATION OF LUNG CARCINOMA: A RARE CASE

Ophthalmology

Dr. Saroj I. Sahdev Professor and Head, Department of Ophthalmology, TNMC & BYL Nair .Ch .Hospital Mumbai.

Dr. Neelam H. Pahlajani* Fellow Vitreo-retina surgery, Department of Ophthalmology, TNMC & BYL Nair .Ch. Hospital Mumbai. *Corresponding Author

Dr. Gaurav S. Atal House Officer , Department of Ophthalmology, TNMC & BYL Nair .Ch .Hospital Mumbai.

ABSTRACT

Choroidal metastases are the most common intraocular tumors with malignancies such as breast & lung being the most common primary sites. Clinical reports of symptomatic choroidal metastasis as initial presentation in lung carcinoma are rare. Here we report such a presentation in a 61 yr old male patient, who presented with decreased vision in (LE) since 1 month. Detailed evaluation of the eye revealed a choroidal mass lesion involving the posterior pole. Further imaging scans of the body revealed bronchogenic lung carcinoma with mediastinal nodular & hepatic metastasis. Patient was referred to cancer institute where he underwent USG guided FNAC from hepatic metastasis and was diagnosed with metastatic small cell carcinoma of the lung. Prognosis is usually dismal with such kind of presentation. Treatment requires multidisciplinary collaboration & evaluation of multiple factors. Eye is truly the window of the body through which life threatening diseases can be diagnosed. Hence detailed examination of the eye is of utmost importance.

KEYWORDS

choroidal metastases,small cell lung carcinoma,systemic chemotherapy

Introduction

Choroidal metastases are the most common of adult intraocular tumors. Multiple foci in one eye approximately in 20%and bilateral involvement in20-40% is frequently seen in affected cases. Diminution of vision as the initial manifestation of lung carcinoma is extremely rare. Here we report such a rare clinical scenario in a patient of bronchogenic carcinoma along with relevant review of literature in an attempt to provide better insight to the clinicians faced with similar rare situations.

Case Report

A 61-year-old male patient presented to our ophthalmology clinic with chief complaints of dimness of vision in his left eye since 1 month. He was a heavy smoker since last 40 years and used to smoke one pack of cigarette a day. Ophthamic examination revealed his best corrected visual acuity was 20/40 in the right eye and 20/80 in the left eye. Slit lamp examination findings were unremarkable. Detailed fundus examination of the left eye revealed an ill-defined, yellow white lesion in the choroid more than 10 disc diameter involving the macula and superior peripapillary region(fig 1).



Fig:1

Fundus examination of the right eye was normal.An ultrasound B-scan revealed a dome shaped elevated choroidal lesion with moderate internal reflectivity and height of 5.6 mm (fig 2). His systemic examination was unremarkable.

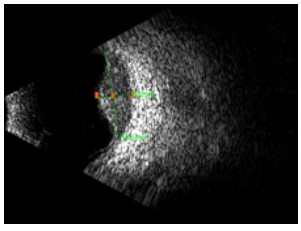

Fig:2

In search of primary malignancy further imaging studies were done.Computed tomography of the chest revealed centrally located bronchogenic malignancy in the left lung,invading the mediastinum with bronchovascular encasement and narrowing.Pleural effusion, lung parenchymal and mediastinal nodular and hepatic metastasis were also seen.USG guided biopsy of the hepatic metastasis was done.Subsequent histopathological examination showed metastatic tumor of neuroendocrine morphology with foci of necrosis. On immunohistochemistry tumor cells were positive for TTF1,focally positive for synaptophysin and occasional cells were positive for chromogranin.Overall findings were consistent with metastatic small cell carcinoma of the lung. Due to poor ECOG performance status, systemic chemotherapy could not be started in our patient.

Discussion

Metastatic cancer is the most common adult intraocular malignancy, choroid being the most frequent site.[1,2] Multifocal involvement in one eye in 20% and bilateral lesions in 20-40% are seen in the affected cases.[3] Metastatic choroidal lesions typically involve the posterior pole, due to relative greater blood supply to that area.[1]The most common primary sites for choroidal metastases being breast, lung, skin, pancreas, kidney, and prostate.[1,2]Choroidal metastases can be asymptomatic. When symptomatic, these lesions can cause painless visual loss by involvement of the macular or peripapillary retina due to associated exudative retinal detachment.[4,5] Our patient presented with diminution of vision due to solitary, ill-defined mass lesion involving the posterior pole in his left eye.

Differential diagnosis of these lesions include choroidal melanoma, choroidal osteoma, choroidal hemangioma, choroidal neovascularization with disciform scar, posterior scleritis, and other rare lesions.Clinically they appear creamy yellow lesions. On fluorescein angiography, metastatic choroidal tumors are usually hypofluorescent in the early phases and become progressively hyperfluorescent in late phases.[6] Ultrasound B-scan shows an echogenic sub-retinal mass with diffuse, ill-defined borders with moderate sound attenuation and associated overlying retinal detachment.[7]

Treatment options include laser photocoagulation, cryotherapy, chemotherapy, RT, surgical resection, enucleation and photodynamic therapy.[8]Letson et al. had described six patients with choroidal metastasis who were treated with systemic chemotherapy and underwent regression.[9]Thus, chemotherapy alone is a viable option in chemo-responsive primary tumors. Close observation may be considered for small metastases in the periphery of the retina that are

asymptomatic or slowly progressive in nature .[3] Complete response to systemic chemotherapy may allow postponement or avoidance of local therapy to the choroidal metastases although lesions causing visual symptoms or encroaching upon the optic disc or macula generally require local therapy. Few reports however suggest improved outcomes with combination of local and systemic therapies.[10]But in our patient poor ECOG performance status due to widespread metastases, did not permit the systemic chemotherapy.

Thus management of patients with choroidal metastases requires careful evaluation of multiple factors including the intraocular site, presence of visual symptoms, primary tumor histology and site, presence and status of other metastases, and anticipated efficacy of systemic treatment options.

Conclusion

Treatment for ocular metastases is only palliative. The goals for treatment are to maximize quality of life, and to restore or preserve vision. Thus the prognosis of patients with choroidal metastases is poor since most patients will unfortunately succumb to widely disseminated systemic disease. Therefore in a patient presenting with choroidal mass lesion,clinicians should always keep this rare scenario as a differential diagnosis.

References:

1. Ferry AP, Font RL: Carcinoma metastatic to eye and orbit: a clinicopathologic study of 227 cases. Arch Ophthalmol 1974, 92:276-286.
2. Stephens RF, Shields JA: Diagnosis and management of cancer metastatic to the uvea: a study of 70 cases. Ophthalmol 1979, 86:1336-1349.
3. Shields JA: Diagnosis and Management of Intraocular Tumors. St Louis:Mosby 1983.
4. Gonvers M, Zografos L. Choroidal metastases and rhegmatogenous retinal detachment. Retina 1991;11:426–9.
5. Haimovici R, Mukai S, Schachat AP, et al. Rhegmatogenous retinal detachment in eyes with uveal melanoma. Retina 1996;16:488–96.
6. David DL, Robertson DM: Flourescein angiography of metastatic choroidal tumors. Arch Ophthalmol 1973, 89:97-99.
7. Shammas HJ: Atlas of Ophthalmic Ultrasonography and Biometry. St L
8. Harbour JW: Photodinamic therapy for choroidal metastasis from carcinoid tumour. Am J Ophthalmol 2004;137:1143–1145. ouis: Mosby 1984.
9. Letson AD, Davidorf FH, Bruce RA Jr: Chemotherapy for treatment of choroidal metastases from breast carcinoma. Am J Ophthalmol 1982, 93:102-106.
10. Amer R, Pe'er J, Chowers I, et al. Treatment options in the management of choroidal metastases. Ophthalmologica 2004;218:372–7.