Volume : 2 | Issue : 4 | Apr 2013 • ISSN No 2277 - 8179

Research Paper

Clinical Evaluation of Non-Ablative Radio Frequency Device for Facial Rejuvenation with its Histopathological Co-Relation

Medical Science

KEYWORDS : Non –ablative radio frequency; facial rejuvenation; collegen remodeling

Dr Manjiri Oke	Assistant lecturer, Department of Skin and VD, NKPSIMS , Nagpur
Dr Milind Borkar	Professor and Head, Department of Skin and VD, NKPSIMS Nagpur
Dr Anne Wilkinson	Associate Professor, Department of Pathology, NKPSIMS Nagpur
Dr Amruta Dashputra	Assistant Professor, Department of Pharmacology, NKPSIMS Nagpur
Dr Sadhana Mahore	Professor and Head, Department of Pathology, NKPSIMS Nagpur
Dr Sushil Pande	Assistant Professor, Department of Dermatology NKPSIMS, Nagpur

ABSTRACT

Introduction-- Development of truly noninvasive deep tightening techniques continues to interest cosmetic surgeons and public alike. Non –ablative radio frequency device is a novel device which produces an electric current that generates heat through resistance in dermis and subcutaneous tissue. Objective -To evaluate the efficacy and safety of non-ablative radiofrequency device on Indian facial skin and to correlate the results with histopathology. Methodology-35 patients were enrolled for peri-orbital wrinkles, sagging jawline, prominent nasolabial fold, acne scars and open pores. Pre-treatment evaluation of patients was done by two physicians and pretreatment photographs and biopsy were also taken. Patients were treated at monthly interval. Post treatment evaluation along with post treatment photographs and biopsy was done at the end of 3 months and patient's satisfaction score was marked. Data analysis- Data was analyzed by unpaired t-test. Results- Mild improvement was seen on clinical evaluation. However, histopathology showed increase in collagen at the end of three months. Conclusion -The study indicates there is mild clinical improvement in acne scars, periorbital wrinkles and sagging by treatment with nonablative monopolar radiofrequency device at the end of 3 months. This device can be kept as a therapeutic cheap option for patients with realistic expectations opting for facial rejuvenation.

INTRODUCTION

Influenced by media publicity and coupled with advances in medical technology to restore a youthful appearance, there has been an enormous increase in supply and demand for aesthetic procedures. [1] Nowadays rejuvenation of photo damaged facial skin has become increasingly popular. Although dramatic clinical improvement can be achieved with surgical lifting procedures, there is considerable risk associated with it, along with prolonged post operative recovery. As such noninvasive procedures which are pocket friendly, with little post operative recovery and low side effects are in considerable demand.

Ablative laser skin resurfacing is a well accepted treatment modality for facial rejuvenation and it produces good improvement in the appearance of photo induced rhytides. However patients are hesitant to pursue the treatment because of its extended post operative recovery period and inherent risks of procedure and high cost.

Results of non ablative lasers and light based treatments do not match the results of ablative lasers. Therefore development of a truly noninvasive deep tightening technique continues to interest cosmetic surgeons and public alike.

Non –ablative radio frequency device is a novel device which produces an electric current that generates heat through resistance in dermis and subcutaneous tissue. The depth and degree of thermal injury depends on the geometry and size of the treatment tip and conductive properties of the tissue being treated. Tissue with higher impedance such as subcutaneous fat generates greater heat thus resulting in deep tissue thermal effects. Non-ablative radiofrequency device uses a unique capacitor membrane at the treatment tip that allows uniform volumetric application of heat. The reverse thermal gradient created is thought to cause skin collagen scaffold to contract when heated to sufficiently high temperature and eventually leads to collagen regeneration and further skin tightening via natural wound healing response and thus cause further skin tightening. [2 3, 4]

AIMS AND OBJECTIVES

1. To evaluate the efficiency and safety of non- ablative radiofrequency device on Indian ageing skin.
2. To see its effects on open pores, acne scars, periorbital rhytides, prominent naso-labial folds and sagging jawline.

METHODOLOGY

After ethical clearance from the Institutional Ethics Committee an observational study was conducted on 35 patients attending skin OPD of the Institute.

After pretreatment evaluation and proper explanation a written consent was taken from each patient. Pretreatment photographs of the patients were taken in frontal view, right and left lateral view and right and left oblique view with the same camera and proper lighting. Pretreatment skin biopsy was taken. Pretreatment evaluation was done by two Physicians. The patients were treated with mono polar Non ablative radiofrequency device Megatouch Gold from DermaIndia having frequency of 2.9 MHz. Before starting the procedure each patient was asked to wash face with soap and water. Each patient was treated in lying position. Shapes of the tips varied according to the part treated. Average Fluence of 8, 14, 16, and 18 were used for eyelids, forehead, cheeks, chin, and naso-labial fold and jawline. Fluence was adjusted as per patient's tolerance. Whole of the face was treated and treatment time was 45-50 minutes. While treating, conductive coupling fluid like Echo-ECG gel was used to facilitate complete contact between the tip of the electrode and skin surface and uniform contact was ensured. Capacitive electrode was moved in a circular manner on the entire face with moderate pressure. The electrode was moved till mild erythema or edema was noticed or patients' ability to tolerance to heat was regarded as an end point. Electrode was moved to other area on achieving the end point. Anesthesia or analgesia was not used on any of the patients. [5]

At the conclusion of the procedure, patient was asked to clean the face with water. Patient was informed to contact us if he/she noticed any adverse reactions. Patient was explained that he/she might have erythema which may last for 48 hrs and edema which may last for 2 to 7 days. The therapy was repeated every

Volume : 2 | Issue : 4 | Apr 2013 • ISSN No 2277 - 8179

month and three treatments (sittings) were given. After completion of scheduled three sittings, patient was evaluated by two physicians separately and patients' evaluation was filled up separately. And patients satisfaction score was marked. Post treatment skin biopsy from temple area was repeated after 3 months.

Following grading systems were used in this study:
Patient satisfaction
- A five point scale was used to measure patient's satisfaction
0 = no satisfaction, 1 = minimal satisfaction, 2 = moderate satisfaction, 3 = good satisfaction and 4 = excellent satisfaction.

Physician's evaluation [6] - Similarly, a five point scale was used for Physicians' evaluation 0 = no visible improvement, 1 = minimal improvement, 2 = moderate improvement, 3 = good improvement and 4 = excellent improvement.

Pore size [2] -Pore size was measured on a 3 point scale where 1= small, 2 = average, 3 = large.

Acne Scar-Acne scars was graded according to Global Acne Scarring Classification [7, 8]. It is a 4 point grading system where Grade 1 = Macular scarring (post inflammatory hyper or hypo pigmentation), Grade 2 = Mild atrophic or hypertrophic scarring that may be evident at a distance of 50 cm or more or may be adequately masked by make up or hair pattern, Grade 3 = Moderate atrophic or hypertrophic scarring obvious at social distance and not easily masked, Grade 4 = Severe atrophic or hypertrophic scarring.

Clarity of Acne [8]-Clarity of Acne was graded on a scale of four,[8] where Grade 1 = Black heads, white heads, Grade 2 = Papules and few pustules, Grade 3 = Pustules and few nodules, Grade 4 = Nodules and cysts.

Wrinkle depth and number [9] -Wrinkle depth and number was measured according to 3 point Fitzpatrick wrinkle classification where 1 = Fine, 2 = Moderate and 3 = Deep.

Nasolabial fold [9] -Nasolabial fold was decided on a 3 point scale where, 1 = Mild, 2 = Moderate and 3 = Marked.

Jawline was decided on a 3 point scale where, 1 = Mild, 2 = Moderate and 3 = Marked.

Indian patients between ages 15-55 years were selected. Those with acne scars, open pores ,moderate degree of laxity of skin in the form of sagging jawline and prominent naso-labial folds and wrinkles with Fitzpatrick skin type II to V were included in the study. Patients having severe grade of acne, and patients on treatment for acne in the form of retinoid or those undergoing treatment with peels were excluded from the study. All patients undergoing treatment for facial rejuvenation in the form of Botox, Lasers or those who have undergone facial surgeries were excluded from the study. Pregnant patients, those having implants or patients having dermatological or collagen vascular disease acute systemic infections/ local infections like herpes simplex, impetigo were also excluded. Patients showing side effects in the form of burns or hyper-pigmentation and not willing to participate were withdrawn from the study.

DATA ANALYSIS-Data was analyzed by applying unpaired t-test and p value < 0.05 was considered as significant.

RESULTS: Total no. of patients enrolled was 35. In the present study patients were evaluated on the basis of five entities (wrinkles, naso-labial folds, sagging jawline, acne scars and open pores). Each entity was counted as separate data. Thus total numbers of cases counted in study were 49.

Patients having wrinkles : 12
Patients with prominent naso-labial folds: 5
Patients with sagging jawline : 5
Patients with Acne scars :16
Patients with open pores :11
Pre T/t biopsy done : 28
Post T/t biopsy done : 20
Adverse effects in sagging : 5 (41.67%)
Adverse effects in acne scars : 11 (47.82%)
According to table no 1,

Sr. No.	Wrinkles			Open pores			Nasolabial fold			Sagging jawline			Acne scars		
	Age	Patient evaluation	Physicains' Average	Age	Pts Evaluation	Physician's Average	Age	Pts evaluation	Physicains' Average	Age	Pts evaluation	Physicains' Average	Age	Pts evaluation	Physicains' Average
1	32	3	2.5	28	1	1	48	1	1	32	2	2	29	2	1.5
2	40	1	1	28	2	1	55	1	1	42	2	2	26	2	2
3	48	1	1	21	0	0	35	2	1.5	48	1	1	23	2	2
4	46	1	1	25	0	0	40	1	1	46	2	1.5	26	2	1.5
5	55	1	1	24	1	1	40	1	1	55	1	1	23	2	2
6	28	1	1	19	0	0							23	1	1
7	30	0	0.5	19	0	0							24	1	1
8	38	2	2	23	2	2							23	2	2
9	35	2	1.5	25	1	1							28	1	1
10	40	0	0.5	24	1	1							30	2	1
11	30	1	1	27	2	2							50	1	1
12	40	0	0.5	-	-	-							22	2	2
13													25	0	0
14													24	0	0
15													24	1	1
16													38	1	1
		13	13.5		10	9		6	5.5		8	7.5		22	20
	Mean	1.08	1.125	Mean	0.91	0.82	Mean	1.20	1.10	Mean	1.60	1.50	Mean	1.38	1.25
	S.D.	0.90	0.61	S.D.	0.83	0.75	S.D.	0.45	0.22	SD	0.55	0.50	SD	0.72	0.66
	P value	0.89		0.7905			0.6665			0.7707			0.6117		

Note- Scoring was done according to gradation of different entities. (This is already mentioned)

out of 12 patients treated for wrinkles, 6 (50%) showed improvement by 1 grade and 1 (8.33%) showed improvement by 0.5 grade. All patients showed smoothening of skin. The patients treated for wrinkles were in the age group of 26 – 55 years. The age group of 26 – 35 years

showed the most improvement. Patient's improvement score: 1.08, average Physicians' improvement score: 1.125.

Out of 5 patients treated for prominent naso-labial folds, 3 (60%) showed improvement by 1 grade. All showed softening of the fold. The patients treated for prominent naso-labial folds were in the age group of 36 – 55 years. The age group of 36 - 45 years showed the most improvement. Patient's improvement score: 1.20, average Physicians' improvement score: 1.10.

Out of 5 patients treated for sagging jawline, 3 (60%) showed improvement by 1 grade and showed mild sharpening of the contour. Patients with less facial fat showed better results. The patients treated for prominent sagging jawline were in the age group of 36 – 55 years. The age group of 31 - 40 years showed the most improvement .Patient's improvement score: 1.6, Physicians' improvement scores: 1.5.

Out of the 16 patients treated for acne scars, 1 (6.25%) showed improvement by 0.5 grade, 7 (43.76%) showed improvement by 1 grade and 3 (1875%) patients showed improvement by 1.5 grade(Figure 1 &2) .



Fig -1 Pre treatment Fig -2 Post treatment

The patients treated for acne scars were in the age group of 21 – 50 years. The age group of 21 – 30 years showed the most improvement (Patient's improvement score: 1.38, average Physicians' improvement score: 1.25).

Of the 11 patients treated for open pores, 2 (18.18%) patients showed improvement by 0.5 grades and 1 (9.09%) showed improvement by 1 grade. The patients treated for open pores were in the age group of 16 – 35 years. (Patient's improvement score: 0.91, average Physicians' improvement score: 0.82). The age group of 26 – 35 years showed the most improvement according to patients it is 1.66 and average physicians it is 1.33.

In the three month post treatment follow up biopsies, all 8 patients (100%) with wrinkle showed increase in dermal collagen. Out of 12 patients with acne scars, 10(83%) patients showed evidence of mononuclear inflammatory infiltrate at the end of 3 months and 6 patents (50%) showed increase in collagen in the dermis (Figure 3). However the most appreciable increase in collagen was seen in the wrinkles category. (Figures 3 and 4)

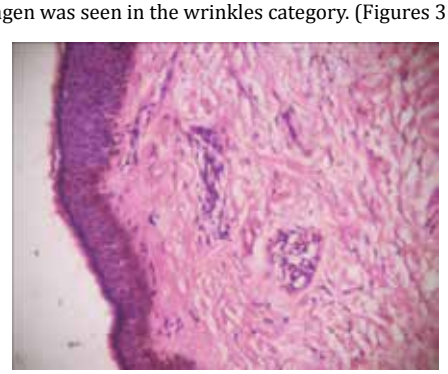

Figure 3. Skin biopsy after 3 months in a patient of wrinkles showing increase in collagen in the upper part of the dermis, along with mild mononuclear inflammatory infiltrate [Haematoxylin and Eosin stain x 400].

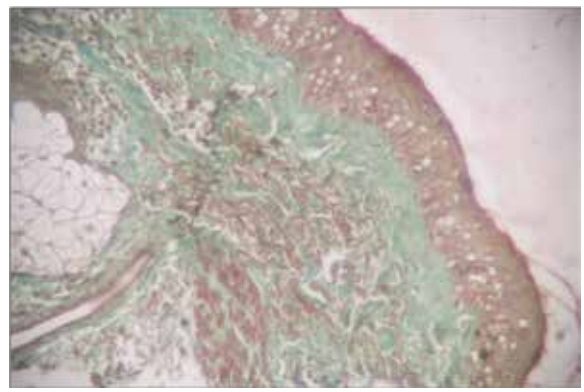

Figure 4. Skin biopsy after 3 months in a patient of facial wrinkles showing increase in collagen (green) in the upper part of the dermis. [Masson's Trichrome stain x 400]

Side Effects in patients with Acne scar

Acneform eruptions were seen in10 patients. Eight patients had increase in existing acne. Two patients who did not have acne at the beginning of the study developed Grade 1 acne.

Side Effects in patients with Sagging

Transient skin darkening was seen in five patients. This transient skin darkening resolved within a few days.

DISCUSSION

This was an observational study to evaluate the clinical efficacy and safety of RF monopolar device on Indian facial skin and to correlate it histopathologically. The treatment being non-invasive is getting popular. It is an office procedure and requires no down time.

Various studies have been conducted using devices like non-ablative lasers, nonablative radiofrequency devices and ultrasound devices for skin lifting and tightening. Most of the studies have been done on fair skin. There are few studies on Asian skin and very few on Indian skin.

There are various radiofrequency devices currently being used for skin tightening and body contouring. The oldest is the monopolar RF device. Newer devices are bipolar RF, bipolar RF with vacuum apparatus and bipolar RF with electro-optical energy. Another device combines RF energy and pulse light. Fractional RF works like fractional devices with skip areas next to damaged skin that are useful in treating acne scars. There are also devices using tripolar RF which deliver lower energies at different poles making treatment more palatable than monoplor RF. These are effective in treating skin laxity and body contouring. (10)

Most of the previous studies have been done using Thermcool (Thermage) monopolar radio frequency device, which was approved by FDA for non-invasive treatment of peri-orbital wrinkles and rhytides in 2002 and later for full face in 2004. FDA also gave clearance in 2006 for use of the device on non-facial skin including abdomen, thighs and buttocks. (11)

In our study 7/12 (58.33%) patients showed improvement in periorbital wrinkles by 1- 0.5 grade, 3/5(60%) patients of nasolabial prominence showed improvement by grade 1 .3/5(60%) patients of sagging jawline showed improvement by grade 1.In all these groups patients and average physicians evaluation showed mild improvement.

In the study conducted by Abraham et al [(2)] overall patient satisfaction with skin tightening and wrinkle reduction was excellent. Similarly in a multicentric study conducted by Fitzpatrick et al[(9)]at the end of 6 months clinicians' noted wrinkle reduction in 30% areas. Most of the patients had improvement by one Fitzpatrick point which somewhat matches our results .Reason of lesser results in our study could be related to lower RF treat-

ment fluences tolerated by these patients as no anesthesia was used ,neither IV nor topical as compared to other studies.

Significant improvement was seen at the end of 6 months in a study conducted by Alster and Tanzi([4]) on 50 patients of mild to moderate cheek or neck laxity. Here also topical anesthetic cream was used and oral diazepam 5 – 10 mg was given prior to treatment.

In present study, patients of acne scars showed mild improvement. Patients' evaluation matched average dermatologists evaluation. Clinically patients had softening of scars and 11/16 (68.75%) showed improvement ranging from 0.5 - 1.5 grade. However improvement in active acne seen in study done by Abraham MT, Chiang SK(2) and also in another study by Ruiz-Espaza and Gomez (12)is not seen in our study, rather there is increase in the acne following treatment with nonablative RF device in 10/16 patients. This acne flare is seen mostly in patients having preexisting acne 8/10.This finding contradicts the hypothesis that heat generated by RF causes atrophy of sebaceous glands and is bactericidal.

There are studies done by Ruiz-Esparza on role of mono polar non-ablative RF device on active acne and rosacea .There are no studies of monopolar RF on acne scars. The increasing use of non ablative RF in the rejuvenation of the skin has mentioned that acne scars have responded well to new devices using fractional bipolar RF(10)

Efficacy of this study showed mild improvement with treatment with RF as against very satisfactory results in another study.([3]) In present study nonablative radiofreqency device by derma India having frequency of 2.9 megahertz was used. Thermage is having frequency of 6 megahertz probably this could be the reason for lesser result in our study. Aging is a dynamic process and involves all layers of skin from epidermis to subcutaneous tissue as well as supporting muscle. So for getting good results we need a device which will treat all layers and also cause muscle tightening. There have been reports stating that combined use of monopolar bipolar and tripolar nonablative radiofrequency device enhance the results as they treat all layers of skin

In this study, side effects like transient erythema, edema and transient darkening of skin were seen in patients with sagging skin and were mild and reversible. This is our observation and is probably due to darker skin of Indian patients Darkening of skin has not been mentioned in other studies ([4, 10, and 13]). Patients with history of acne in recent past showed increase in acneform eruptions. Side effects like dysesthesia burns seen in other studies. ([4, 10]) were not seen in any of our patients.

Most of the studies have been done to study the safety and efficacy of RF. Our study was to do the clinical evaluation of non-ablative radiofrequency device and correlate the findings by doing histopathology. There has been only one study done with light microscopy which has demonstrated no significant change in epidermis or dermal ground substance immediately after treatment, there was scattered mild peri-vascular and peri-adenexal inflammation. 3 and 8 weeks after treatment no observable changes were noted. ([3])

In present study mild perivascular and periadenexal inflammatory infiltrate in post treatment biopsies mainly in patients of acne scars was seen. Inflammatory infiltrate in post treatment biopsies could be the early sign of new collagen synthesis as we find significant increase in collagen in most of our slides.

Clinical evaluation are showing mild to moderate results but there is increase in collagen in most of the cases suggesting that longer follow up could have given better results.

In a study by Kaplan et al.([14]) RF system using a multiple-electrode, TriPollar™ design with frequency of 1MHz histopathological examination of the biopsy samples of one patient revealed marked differences between the treated and non-treated abdominal skin areas. The average dermal thickness (combined papillary and reticular layers) on the treated side was measured as 5.5mm (range 5.0–6.0mm), while on the non-treated side it was 3.7mm (range 3.5–4mm), indicating a 49% increase in dermal thickness following seven TriPollar RF treatments. The increase in dermal thickness appears to be due to focal thickening of collagen fibers .A mild increase in the number of dermal fibroblasts and focally increased number of elastin fibers was noticed. The subcutaneous layer thickness was similar in both groups; however, in some areas of the treated skin samples the lobular fat cells appear to be smaller, with elongated or polygonal irregular shapes, instead of round shapes, and with some ruptured cell membranes. Inflammatory infiltrate or necrosis was not present in any of the samples.([14])

CONCLUSION

Our study shows mild to moderate improvement in facial appearance along with increased collagen seen on histopathology. Longer treatments and combined therapies should accentuate the results. Treatment with non ablative RF device can be kept as one of the safe treatment options for middle aged patients having mild laxity of skin or patients having mild acne scars having realistic expectations, and for those who are not willing for surgery as well as lasers due to the risk or the cost.

REFERENCE

1. Vedamurthy M. Antiging therapies Indian Journal Dermatol Venereol Leprol 2006; 72: 182-186 2. Abraham M T, Chiang S.K, Keller G.S, Rawnsley JD, Blackwell KE, Elashoff DA. Clinical evaluation of non-ablative radiofrequency facial rejuvenation. J Cosmet Laser Ther 2004; 6:136-144. 3. Kushikata N, Negishi K, Tezuka Y, Takeuchi K, Wakamatsu S Lasers Surg Med. 2005 Feb36(2)92-7 4. Alster TS, Tanzi E. Improvement for Neck and Cheek Laxity with a Nonablative Radiofrequency Device: A Lifting Experience. Dermatologic Surgery. 30:503-507. 5. Shared J. Nonablative facelift in Indian skin with superpulsed radiofrequency. Indian Dermatol Online J 2011; 2:6-9. 6. Erol OO, Gurlek A, et al. Treatment of Hypertrophic Scars and Keloids Using Intense Pulsed Light (IPL). Aesth Plast Surg (2008) 32:902-909.) 7. Kubba R, Bajaj AK, Thappa DM, Sharma R, Vedamurthy M, Dhar S, Criton S, Fernandez R,Kanwar A J, Khopkar U, Kohli M, Kuriyipe VP, Lahiri K, Madnani N, Parikh D, Pujara S, Rajababu KK, Sacchidanand S, Sharma VK, Thomas J. Acne in India: Guidelines for management –IAA Consensus Document: Acne Scars. Indian J Dermatol Venereol Leprol 2009; 75 (Suppl 1):52-S3) Gold MH Expert Rev. Dermatol. 6(2), 139-142(2011) 8. Tutakne M A, Vaishampayan SS; Acne & rosacea and perioral Dermatitis: In INDVL Text book of Dermatology 3rd Edition 2008. Bhalani Publishing House. Mumbai p842-43. 9. Fitzpatrick R, Geronemus R, Goldberg D, et al. Multicenter study of noninvasive radiofrequency for periorbital tissue tightening. Lasers surg Med 2003; 33: 232-42 10. Gold M H. The Increasing Use of Nonablative Radiofrequency in the Rejuvenation. Expert Rev. Dermacol. 6(2), 139-142 (2011) 11. Sukal SA, Geronemus RG, Clinics in Dematology (2008) 26,602-607. Publication ELSEVIER.) 12. Ruiz-Esparza J, Gomez JB Nonablative radiofrequency for active acne. Gold MH The increasing use of non ablative RF in the rejuvenation of the skin. (Expet Rev.Dermatol. 6(2), 139-143(2011) 13. Zelickson B D, Kist D, Bernstein E, et al. Histological and ultra structural evaluation of the effects of a radiofrequency –based nonablative dermal remodeling device: a pilot study. Arch Dermatol. 2004;140:204 14. Kaplan H, Gat A, Clinical and histopathological results filliwing Tripollar. Journal of Cosmetic and Laser therapy, 2009; 1-7.