ORIGINAL RESEARCH PAPER

Volume-7 | Issue-4 | April-2018 | PRINT ISSN No 2277 - 8179

INTERNATIONAL JOURNAL OF SCIENTIFIC RESEARCH

CLINICAL OUTCOME OF RAPID ABSORBABLE IRRADIATED POLYGLACTIN 910 SUTURE VERSUS NON ABSORBABLE ETHILON SUTURE IN CLOSURE OF THE SKIN WOUNDS OF HEAD AND NECK REGION –A COMPARATIVE STUDY

Clinical Research

Sneha Kadam* MGM Dental College AND Hospital, Kamothe Navi Mumbai *Corresponding Author

Sushrut Vaidya Professor, Dept. of Oral and Maxillofacial Surgery, MGM Dental College and Hospital

Jyotsna Galinde Professor, Dept. of Oral and Maxillofacial Surgery, MGM Dental College and Hospital

Srivalli Natrajan Professor & HOD, Dept. of Oral and Maxillofacial Surgery, MGM Dental College and Hospital

ABSTRACT

Many surgeons believe that nonabsorbable suture material are preferable over absorbale suture as it is easier to tie and elicits a minimal inflammatory response. While others feel tht absorbable sutures are more preferred because they do not have to be removed, thus saving the surgeon time and decreasing patient anxiety and discomfort. Also among absorbable materials, because of their long presence on skin due to delayed absorption time, it may elicitate tissue reaction and result poor cosmesis. So to facilitate rapid absorption, gamma irradiated polyglactin 910 was introduced for better outcomes. We sought to compare the clinical outcomes of rapidly absorbable irradiated polyglactin 910 suture material with nonabsorbable ethilon sutures for skin closure of wounds created in surgical procedure or those due to trauma. Patients were evaluated for wound healing, scar severity and patient satisfaction on 7thday, 14thday, 21st day and at 3 month follow up. In surgical cases, tissue response was more favorable with ethilon than vicryl rapide. Whereas in trauma group, optimal results were found in ethilon group as compared to vicryl rapide, though statistically significant differences were not obtained in any of the parameters. Our study concluded that wounds that are made in sterile condition like in the surgical procedure shows better cosmetic result by using ethilon suture rather than vicryl rapide. As per the trauma cases were considered, either of the suture material can be used.

KEYWORDS

vicryl rapide, ethilon , irradiated polyglactin 910.

Introduction

Face is considered aesthetically more important than any other part of the body. Because an individual's self-image are often derived from his or her own facial appearance, any injury affecting these features such as lacerations due to trauma or incision taken for surgical approaches requires particular attention. A surgeon can be successful in his surgery only on attainment of adequate healing of tissue. Ideal wound healing largely depends upon the use of proper surgical techniques and wound care. It can be achieved by accurate incision, delicate tissue handling, precise wound approximation, selection of appropriate wound closure material with good working properties and aseptic techniques to prevent pathogenic microbes from entering the body. Various other factors responsible for wound healing are individual's systemic health, nutritional status, immune response and presence or absence of infection at the surgical site.

The suture material is a foreign body which may elicitate a foreign body tissue reaction when implanted into human tissues. During wound closure, a sterile field and meticulous aseptic technique are critical to minimize the risk of wound infection. Other wound healing complications such as hypertrophic scars, wound dehiscence, incorrect suture selection, or technique that results in excessive tension across the wound should always be kept in mind while selecting a suture material. Skillful wound closure requires not only knowledge of proper surgical technique but also the physical characteristics and properties of the suture and the needle choice. Just like the choice of suture material is important, aetiology of the wound is also important. The type of injury has an influence on the course of wound healing.

The basic principles of wound repair have not changed significantly in the last century, but the therapeutic options now available are more innovative and rigorously studied. The development of topical anesthetics, tissue adhesives, and fast-absorbing sutures has made the management of skin closure less traumatic to the Patient. For this purpose, a variety of suture materials are studied and made available which may be classified upon their origin (organic and synthetic) or according to their durability in host tissues (absorbable and non absorbable)[1].

In the traditional teaching, non absorbable sutures have been recommended as the material of choice for closing the skin wounds. Many surgeons have challenged this notion and have recommended that all skin closure requiring sutures, including head and neck region, can be repaired by absorbable suture material. Non absorbable suture like Ethilon is the most commonly used material for closure of skin wounds[2]. Many studies have been conducted, which reports its advantages such as appropriate closure, low dehiscence rate, high tensile strength, and inexpensiveness. However various disadvantages like poor knot security, permanent suture tracts, difficult handling, pain and anxiety during removal have been reported. They degrade in vivo at a rate of approximately 15% to 20% per year by hydrolysis. It has a tendency to return to their original state, a property known as "memory" leading to decrease the knot security over time (in vivo). Therefore more throws in the knot are required which makes resultant knot bulky and time consuming to tie. If applied it has to be removed between 5 and 7 days on face postoperatively, when the wound has only regained approximately 5% to 10% of its strength, also its removal again creates a discomfort among anxious patients especially pediatric one[3].

Among absorbable suture, polyglactin 910 is a synthetic absorbable suture that is copolymer of glycolic acid and lactide acid. Its strength is lost within 28 days, however its long absorption time means that it is retained in the wound beyond the time required for healing, which may leads to infection and annoyance which defeats the purpose of using an absorbable suture. Subjecting it to ionizing radiation, polyglactin 910 reduces the absorption time without affecting its property. So, a new suture material named irradiated polyglactin 910 has been developed which is considered to be useful suture material both intraorally and extraorally.

Irradiated Polyglactin suture 910 (Vicryl Rapide) is a synthetic rapidly absorbable suture has been studied for many years and used successfully in a variety of applications, including plastic surgeries, gynecological, general and oral and maxillofacial surgery[4]. Its tensile strength is retained 50% till 5th day and starts dissolving in 7th -10th day, hence removal is unnecessary and gains patient acceptance with minimum scar formation. It is eliminated by hydrolysis. Studies have claimed its loss from skin in 10-14 days and it can be used on head and neck region.

This study was undertaken to compare the clinical outcomes of the irradiated polyglactin 910 suture which is a rapid absorbable suture with that of the traditionally used ethilon non absorbable suture in closure of skin wounds of head and neck region.

AIM OF THE STUDY:

The aim of the study was to compare the clinical efficacy of absorbable irradiated polyglactin 910 with non absorbable ethilon suture in the closure of skin wounds of head and neck region treated in our institute from December 2014 to August 2016.

OBJECTIVES:

- To compare the clinical outcome between irradiated polyglactin

910 and ethilon suture material in closure of skin wounds in head and neck region.
- To evaluate the advantages and disadvantage of irradiated polyglactin 910 and ethilon suture material.
- To evaluate the tissue response subjected to irradiated polyglactin 910 suture and ethilon suture.
- To evaluate the patient acceptance of irradiated polyglactin 910 and ethilon suture material.

MATERIALS AND METHODS:

Study was conducted in the Department of Oral and Maxillofacial Surgery, between Dec'2014 and Aug'2016. A standard performa was used to collect necessary information regarding each case after inclusion. The patients informed about the study and necessary consent was taken from the concerned personnel.

INCLUSION CRITERIA:

- Patients between age group 01 -60 yr.
- Patients of either gender were included.
- All cases having skin wounds of head and neck region including scalp, face and neck.
- Subject willingness and his/her Consent.

EXCLUSION CRITERIA:

- Patients with known history of Diabetes Mellitus and Immunocompromise condition.
- Intraoral wounds.
- Any evidence of cases with keloid formation or a tendency to form hypertrophic scars.
- Any patient allergic to known materials especially with a history of contact.
- Dermatitis to Ethilon or Irradiated polyglactin 910.
- Uncooperative patients and mentally challenged patients.
- Unwilling patients.

Study design

Total of sixty patients were enrolled and were subjected to two materials for closure of skin wound in head and neck region. The skin incisions over head and neck region were assigned to the following two material groups (Chart 1):

Group A: Skin wounds closed with sutures using 3-0 irradiated polyglactin 910 (vicryl rapide).

It is further divided into 2 subgroups:
- Group A1 : surgical or elective cases
- Group A2: traumatic wounds

Group B: Skin incisions closed with sutures using 3-0 ethilon.
It is further divided into 2 subgroups:
- Group B1 : surgical or elective cases
- Group B2: traumatic wounds

These procedures were done on different location of head and neck region such as Chin, Submandibular, Nose, Preauricular, Orbital and Neck region. Randomization was done between same wound location, gender and size of the wound.

These two groups of suture material where used for the closure of wound in patients with different age group, gender and aetiology. Assessment of scar, evaluation of wound, patient satisfaction was done postoperatively at follow up on 7th, 14th, 21st day and after 3 months. After 3 month follow up, a PowerPoint presentation is made out of all the photo shoots. It is then assessed by a nonexpert group and findings noted in the given questionnaire.

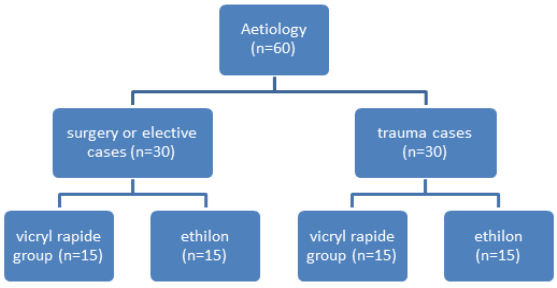

CHART 1: STUDY DESIGN

Evaluation parameters

Two groups of suture material (irradiated polyglactin 910 and ethilon) which were used in closure of skin wounds among the patients in different age group, gender and also in different aetiology like surgical or lacerations due to trauma were compared. All these parameters are evaluated by using following scale:

1. Wound evaluation score
2. Scar assessment scale
3. Cosmetic visual analogue scale
4. Third person evaluation

Patients wound were sutured as per the material selected in randomization. The wound evaluation score addresses 6 clinical variables: Absence of step off, contour irregularities, wound margin separation >2 mm, edge inversion, excessive distortion, and overall cosmetic appearance. Each of these categories is graded on a 0-or-l-point. A total cosmetic score is derived by the addition of the scores of the six categorical variables. Score of 6 is considered optimal, while a score of 5 or less than is considered as suboptimal[5].

Scar assessment scale on several intervals was used to compare the changes in the scar maturity. Scar is categorized into grades such as grade 0 is given if no scar is seen on the sutured wound, grade 1 if faint scar is appreciated. Non-raised visible scar with hyper or hypo pigmentation as compared to the surrounding skin were categorized under Grade 2. Whereas raised and erythromatous scar fell under grade 3. If any keloid formation or severe discoloration such as hyper or hypo pigmentation as compared to surrounding skin were present, then it was given grade 4.

On 3 month follow up, patients assessed their degrees of satisfaction with the wound appearance using a 100 mm vertical line visual analog scale (VAS). This scale was marked at the top with “most satisfied” with wound appearance, with the bottom labeled "least satisfied” with wound appearance. Patients satisfaction for their overall scar was assessed on using visual analogue scale by giving values such as 100mm for fully satisfied state ,50 mm for moderately satisfied and 0mm if patient is unsatisfied .

Postoperative scar formation was recorded according to standardized photographic documentation procedures. Photographic images were evaluated in a blinded manner by nonexperts according to fixed questionnaire after 3 month follow up. Systematic photographic documentation of all 60 patients irrespective of location of wound or material used was performed. Photographs of all 60 patients were taken with a DSLR camera (Nikon D 7000). Then, a PowerPoint presentation was prepared from all photo shoots. Presentation is then shown to a nonexpert observer and informed to fill a questionnaire for each case. Collected data compiled were descriptively assessed.

Result

Of the 60 patients, two aetiology has been considered, surgical and trauma cases among which the clinical outcome of two material (vicryl rapide and ethilon) has been compared. Patients with wounds involving skin over head and neck region are divided as per the aetiology. Skin incision made in sterile condition for operative purposes has been added in surgery or elective cases. Whereas those open wounds due to road traffic accident, fall, assault were added in trauma group. Surgery and trauma cases involve 30 patients each. These are further divided (15 patients) as per the material used for closure of skin wounds, vicryl rapide and ethilon.

The age of the patients included in this study were between 1 year to 60 years, out of which 8 patients (13.3%) were in the age group of 1-15 yrs, 24 patients (40.3%) were in the age group of 15-30 yrs, 21 patients (35.0%) were in age group of 35-40 yrs and 9 patients (15.02%) (table1). Out of patients in our study, 42 patients (70%) were male and 18 patients (30%) were female. Within gender, comparison was done between the two material used in single gender for example, 18 patients were female so 9 were sutured by vicryl rapide and remaining 9 patients by ethilon material. Similarly, in males out of 42 patients, 21 by vicryl rapide and remaining 21 by ethilon. After this, comparison was done between male and female. Clinical outcome of vicryl rapide in female is compared with clinical outcome of vicryl rapide in male. Similarly clinical outcome of ethilon in female is compared with clinical outcome of ethilon in male. No significant difference was observed in any of the age group between ethilon and vicryl rapide suture material. Similarly in gender, no difference was observed.

When compared as per the aetiology, surgical cases showed significant

difference among which ethilon was found to be superior than vicryl rapide suture material, the difference between two groups were found to be significant in margin separation, inflammation and severity of scar with $P < 0.05$; the values being higher in irradiated polyglactin 910 group (vicryl rapide) (figure -1and 2).



Figure-1: Healing on 14th day in ethilon group



Figure-2: Healing on 14th day in vicryl rapide group

In trauma cases, 15 patients were sutured with vicryl rapide and 15 by ethilon. No significant result was found in wound evaluation scale on any of the follow up days. 10 patients in ethilon group and 9 patients from vicryl rapide showed optimal score of 6. While 5 patient in ethilon and 6 patients in vicryl rapide group secured suboptimal score. Patients with optimal and suboptimal score were approximately equal in both the groups. On 7th day follow up, more patients from vicryl rapide were under grade 2 in scar assessment scale as compared to ethilon group patient. Four patient in vicryl rapide secured grade 3 in comparison to one patient in ethilon group on 7th day. Similarly on 14th, 21st day and 3rd month follow up scar severity was more in vicryl rapide as compared to ethilon group, however the difference was statistically insignificant.



Figure-3 :Hypertrophic scar in vicryl rapide group

One patient showed Hypertrophic scar in vicryl rapide group(Figure-3), pigmentation was observed in 2 patients among vicryl rapide. Rail road track appearance of scar was seen in one patient sutured by ethilon suture. There were no cases of suppuration in either of the group. No patients were recommended for scar revision.

Table 1: Clinical outcome of both material irrespective of aetiology, age and gender

Overall performance	WES 7th	WES 14th	WES 21st	WES 3rd month	SAS 7th	SAS 14th	SAS 21st	SAS 3rd month	Visual analogue scale	Third person evaluation
Vicryl rapide	5.80	5.00	5.37	5.67	2.27	1.97	1.50	1.03	83.33	2.03
Ethilon	5.80	5.50	5.73	5.93	2.07	1.93	1.30	.93	95.00	2.50
P-value	1.000	.059	.023	.037	.039	.993	.338	.651	.030	.029

Discussion

A variety of absorbable and non-absorbable materials, ranging from animal derivatives to synthetic polymers, some of which can be fabricated in braided and/or mono-filament form, are used for suturing[5]. Just like the choice of suture material is important, aetiology of the wound is also important. The type of injury has an influence on the course of wound healing[6]. In our study, two type of skin wound were compared. Incisions during elective surgery under sterile environment of operation theatre and lacerations due to trauma on head and neck region were compared. Skin closure of wounds in either of the aetiology (surgical or traumatic) were further divided into two group as per the material used for suturing. Non absorbable ethilon suture was used in one group while rapid absorbable irradiated polyglactin 910 (vicryl rapide) was used in another group. These wounds were evaluated on the following parameters such as wound evaluation, scar assessment, visual analogue scale and finally evaluated by non expert third person. These evaluations were done on intervals like on 7th day, 14th day, 21st day and on 3rd month.

Several approaches could be used to modify the degradation profiles of these synthetic absorbable sutures to meet specific clinic situations. One of them is gamma-irradiation as reported by Chu et al.[7,8]. They found that synthetic absorbable sutures treated by gamma-irradiation degraded faster than the untreated ones both in vitro and in vivo conditions. This is because gamma-irradiation results in extensive chain scissions in both amorphous and crystalline regions[9]. As a result, the increased chain end density and defects reduce the molecular weight of the sutures. A study conducted by Linda Zhang, by comparing the use of gamma irradiation on vicryl and other suture materials concluded that Gamma irradiation significantly accelerated the hydrolytic degradation of Vicryl suture which included an increase in the rate of mass loss; an increase in the rate of tensile strength loss; and a dramatically change in fiber surface morphology[10].

Our study was conducted to compare the clinical outcome of Irradiated Polyglactin 910 (vicryl rapide) suture which is a rapid absorbable suture with that of the traditionally used Ethilon, a non absorbable suture for closure of skin wounds of head and neck region in the Department of oral and maxillofacial surgery from December 2014 to August 2017. Total 60 patient fulfilled the criteria and the clinical trial was undertaken after due approval from the institutional ethic committee and informed consents were procured from the patients after explaining the procedure.

The age of the patients included in study was between 1 years to 60 years, out of which 8 patients (13.3%) were in the age group of 1-15 yrs, 24 patients (40.3%) were in the age group of 15-30 yrs, 21 patients (35.0%) were in age group of 35-40 yrs and 9 patients (15.02%).Out of these patients in our study, 42 patients (70%) were male and 18 patients (30%) were female. No statistically significant association is observed between age, gender and the materials used in our study.

A similar absence of gender-related difference in wound perception has been noted in relation to facial wounds by Nicola J. Tebble BSc MPhil while comparing minor facial laceration on different age group and genders[11]. Cena Tejani, MD, Adam B. Sivitz, MD,et al also found no significant differences in the age, race and gender in the two groups comparing wounds repaired with Vicryl Rapide and nylon sutures in pediatric and adult patients[12].

Clinical significant result was found in wound evaluation score in trauma cases on 14th and 21st day. On 14th day, 6 cases showed lowest score on WES in vicryl rapide group and 3 cases in ethilon group. On 21st day, 7 cases in vicryl rapide group got lowest score on WES and 2 cases in ethilon. Study conducted by Narasinga rao Bandaru, ranga rao a.,Vijaya Nanda et al found that wound infection and gaping can be seen in operative cases[13]. According to them 15 patients presented with infection in the second post-operative week, 13 presented in the first week and 2 presented in the 3rd week. Twun et al., reported that 92% of their Post-operative wound infections were detected by the 21st day,

which was comparable to our results[14]. In another study which was done at the Fauji Foundation Hospital, Rawalpindi, most of the cases of wound infections were noticed by the 6th post-operative day[15].

In a study, the comparison of scalp closure with staples, silk, prolene and vicryl following a Gillie's Temporal approach for malar / zygomatic complex fracture by Muhammad Israr et al Sixty patients were enrolled in the study and randomly selected to have staple, silk, prolene or vicryl rapide for closure of their scalp incision[16]. There was no difference in healing in all four groups.

Wound evaluation score, it is a 6-item categorical cosmetic scale, Step-off borders, margin separations (gap in between sides,> 2mm), Contour irregularity (wrinkled skin near wound), Edge inversion (sinking or curling), Inflammation(redness or swelling), Overall cosmesis are included. A score of 6 was considered optimal; <6 was considered "suboptimal or not effective result[17].

In our study, 5 cases of wound dehiscence or margin separation were seen in vicryl rapide group whereas 2 cases of wound dehiscence in ethilon group. Tissue reaction or inflammation was seen in 2 cases while 1 case of inflammation was seen in ethilon group

A comparison of cosmetic outcomes of lacerations on the extremities and trunk using absorbable versus nonabsorbable sutures study by RobertJ.MacFarlane MD et al was comparing wounds repaired with Vicryl Rapide and Prolene sutures[32]. Pediatric and adult patients with lacerations were enrolled in the study[18]. At a 10-day follow-up, the wounds were evaluated for infection and dehiscence. Out of the 115 patients, 73 completed the study including 35 in the Vicryl Rapide group and 38 in the Prolene group. They found no significant differences in the age, race, sex, length of wound, number of sutures, or layers of repair in the two groups[19].

Scar assessment scale, in our study, no significant difference was seen, out of 30 vicryl rapide cases one has shown hypertrophic scar and 2 shows pigmentation[20]. Most of the cases fall under grade 2 of scar assessment scale. Rail road track appearance is seen in 3 cases of ethilon and 1 in rapide group.

Conclusion

The suturing technique is a complex procedure involving a surgeon specific mix of cognitive and technical components. The choice of the correct suture material is fundamental for tissue healing and patient recovery. Usually, this choice depends upon the patient, the type of wound, tissue characteristics and also the anatomic region. The ethilon suture material found to have better clinical outcomes than irradiated polyglactin 910 (vicryl rapide). In surgical cases, tissue response was good with ethilon than vicryl rapide. Margin separations, inflammation on suture line, scar severity and poor cosmesis was more subjected to vicryl rapide. While, in the trauma group the optimal results were given by ethilon as compared to vicryl rapide, though statistically significant differences were not obtained in any of the parameters. Our study demonstrated that wounds that are made in sterile condition like in the surgical procedure shows better cosmetic result by using ethilon suture rather than vicryl rapide. As per the trauma cases were considered, either of the suture material can be used. Difference in age group or either of the genders does not made any influence on the wound healing when sutured with any of the mentioned suture material. Although vicryl rapide has the distinct advantage of being the rapidly absorbing synthetic absorbable suture, but providing the patient with a good cosmetic appearance for a lifetime, definitely deserves more consideration than avoiding the fear of suture removal.

References

1. Helen Karounis, Serge Gouin, Harley Eisman. A Randomized, Controlled Trial Comparing Long-term Cosmetic Outcomes of Traumatic Pediatric Lacerations Repaired with Absorbable Plain Gut versus Non absorbable Nylon Sutures. Journal of emergency department.2003.12.029.
2. G.joseph parell, Gary D.Becker : Comparision of Absorbable with Nonabsorbable Sutures in Closure of Facial skin wounds. Arch facial plastic surgery : 2003; 5:35,488-490
3. George K.B. Sandor,MD,DDS: outcome of irradiated polyglactin 910 vicryl rapide fast absorbing suture in oral and scalp wounds.journal of Canadian dental association june:1999; 65 i. 6 1277-1283
4. Shafath, K. Bonanthaya, P. Shetty, P. Kumar. Role of absorbable suture material (vicryl rapide 5-0) for skin closure in infants undergoing cheiloplasty. International journal of oral and maxillofacial surgery,2007.vol 8
5. Adam J. Singer; Adam L. Church, MD, Kerry Forrestal; Comparison of Patient Satisfaction and Practitioner Satisfaction with Wound Appearance after Traumatic Wound Repair. Academic emergency medicine2002 VOL 4/NO 2 127.
6. Muhammad Israr: The comparision of scalp closure with staples, silk, prolene and vicryl following a gillie's temporal approach for malar /zygomatic complex fracture.-a prospective study. Pakistan Oral & Dental Journal Vol 33, No. 1 (April 2013).
7. Carl-Johan Ivanoff, Göran Widmark,:. Nonresorbable versus Resorbable Sutures in Oral Implant Surgery: Clinical Implant Dentistry and Related Research, Volume 3, Number 1, 2001
8. L. K. McCaul, J. Bagg, W. M. M. Jenkins. Rate of loss of irradiated polyglactin 910 (Vicryl Rapide) from the mouth: a prospective study. British Journal of Oral and Maxillofacial Surgery (2000) 38, 328–330
9. Kim, Yong-Keun Lee: Comparison of tensile and knot security properties of surgical sutures. J Mater Sci: Mater Med (2007) 18:2363–2369.
10. Eric Silver, Liansheng Song. Knot Security Comparison of Different Suture Materials, Sizes, and Tying Techniques. Journal of Oral and Maxillofacial Surgery. S0278-2391(16)00167-1
11. Chu, David F. Williams. The effect of gamma irradiation on the enzymatic degradation of polyglycolic acid absorbable sutures. Journal of Biomedical Materials Research, Vol. '17, 1029-1040 (1983).
12. Linda Zhang, C.C. Chu,and Ih-Houng Loh Effect of a combined gamma irradiation and parylene plasma treatment on the hydrolytic degradation of synthetic biodegradable sutures. Journal of Biomedical Materials Research, Vol. 27, 1425-1441 (1993) 126.
13. R.K. kundra , S .Newman: Absorbable or non-absorbable sutures? A prospective, randomised evaluation of aesthetic outcomes in patients undergoing elective day-case hand and wrist surgery. Ann R Coll Surg Engl 2010; 92: 665–667.
14. S Pearce, RJI Colville Nailbed repair and patient satisfaction in children. Ann R Coll Surg Engl 2010; 92: 483–485
15. Hajme Mastsuimine, Masaki takeuchi,: Usefulness of irradiated polyglactin 910 (vicryl rapide) for skin suturing during surgery for lateral ray polydactyl of the toes in children plastic reconstruction surg glob open 2013. Surg. 36: 797–801.
16. Nicholes Tebble , Thomas DW, Price P. Anxiety and self-consciousness in patients with minor facial lacerations. J Adv Nurs. 2004 Aug;47(4):417-26.
17. Adam J. Singer, Adam L. Church: Comparison of Patient Satisfaction and Practitioner Satisfaction 124 with Wound Appearance after Traumatic Wound Repair.Academic emergency medicine2002 VOL 4/NO 2.
18. RobertJ.MacFarlane,ThomasD.Donnelly:. Clinical Outcome and Wound Healing following Carpal Tunnel Decompression: A Comparison of Two Common Suture Materials.. BioMed International Volume 2014, Article 270137.
19. Kenichi Hakamada, Shunji Narumi : An easier method for performing a pancreaticojejunostomy for the soft pancreas using a fast-absorbable suture World J Gastroenterol February 21, 2008 Volume 14 Number 7.
20. Hang Kim, H. J. Kang. C. H. Chun,S. M. N. Kim. Ganglion cyst generated by non absorbable suture material in meniscus repair. Journal of orthopaedic surgery vol 98,2001 608-618.