ORIGINAL RESEARCH PAPER

Volume-8 | Issue-3 | March-2019 | PRINT ISSN No 2277 - 8179

INTERNATIONAL JOURNAL OF SCIENTIFIC RESEARCH

CLINICAL PRESENTATION OF RECURRENT GRANULOMA GRAVIDARUM MIMICKING A MALIGNANCY- A REVIEW OF LITERATURE AND A CASE REPORT

Surgery

Ramita Sood* Department of Oral and Maxillofacial Surgery, Ahmedabad Municipal Corporation Dental College and Hospital, Ahmedabad, India. *Corresponding Author

Yusra Mansuri Department of Oral and Maxillofacial Surgery, Ahmedabad Municipal Corporation Dental College and Hospital, Ahmedabad, India.

Kaustubh Bhad Department of Oral and Maxillofacial Surgery, Ahmedabad Municipal Corporation Dental College and Hospital, Ahmedabad, India.

Mruga Gamit Department of Oral and Maxillofacial Surgery, Ahmedabad Municipal Corporation Dental College and Hospital, Ahmedabad, India.

Naiya Shah Department of Oral and Maxillofacial Surgery, Ahmedabad Municipal Corporation Dental College and Hospital, Ahmedabad, India.

ABSTRACT

Granuloma gravidarum also known as oral pregnancy tumor is a misnomer as the granuloma is a benign exophytic lesion occurring due to increased response to a low-grade local irritation, trauma, infection or hormonal disturbances in pregnant females. It can be sessile or pedunculated overgrowth commonly seen on gingiva. In our report, we present a very rare case of a massive swelling on intra-oral right maxillary mucosa proven to be a pregnancy tumor. It caused considerable facial deformity, inconvenience in mastication, & reduced mouth opening. Therefore, palliative treatment was planned. Though recurrence rate has been documented to be 16%, this case showed recurrence 1-month post-partum with a much larger lesion. It arose our suspicion towards malignancy due to enormous size and extension in maxillary sinus. Reports of pyogenic granuloma progressing in malignancy seem to be rare, but the possibility should not be ruled out. Hence, clinico-radiographic & histological evaluation of patient should be done periodically for further recurrence.

KEYWORDS

granuloma gravidarum; oral pregnancy tumor; pyogenic granuloma.

INTRODUCTION

Pregnancy tumor is a pyogenic granuloma occurring in approximately 5% of pregnancies [1]. Incidence of pyogenic granuloma among all reactive lesions is documented between 26.8% and 32% [3]. It is more commonly present on gingiva with 75% incidence of all and more commonly on maxillary and anterior region.it can also be seen on lips, tongue and buccal mucosa [10].

It is non-neoplastic in nature and has tendency to bleed on slight provocation. Increased level of estrogen and progesterone increases the levels of Prevotella intermedia in the subgingival biofilm. It also increases vascular permeability, thus raising infiltration of fluids into the perivascular tissues and enhancing the inflammatory response. This plays important role in the development of the lesion [9].

In 1904, Hartzell coined the term pyogenic granuloma. But it is a misnomer because it is not associated with pus [2]. Pregnancy tumor can appear in any trimester [5], [6] but more commonly appears at the second or third month of pregnancy [4]. Regression usually follows the termination of pregnancy. Recurrence rate for pyogenic granuloma is said to be 16 % of the treated lesions and so re-excision of such lesions must be done [8].

It is usually small (<2 cm) in size and rarely presents with minimal bone changes [3]. But this is not true in all cases. The current report includes a rare case of large sized pregnancy tumor which cause difficulty in swallowing and mastication with localized resorption of bone. The lesion on CT-scan showed maxillary sinus involvement which is rare case.

Oral prophylaxis and surgical excision are usually done but, during pregnancy it is not treated because of possibility of recurrence later. Regression usually follows the termination of pregnancy but depends on size of lesion.

In the present case, a palliative treatment was done during the second trimester of pregnancy, but recurrence occurred due to incomplete excision. So, definitive treatment was opted after 1-month post-partum.

CASE REPORT

A 21-year old woman with 6th month pregnancy primigravida presented with a swelling of 15 days duration in the right maxilla. (fig 1A, B). She gave a history of pain and swelling in relation to maxillary right first molar since 15 days. She also noticed bleeding from the swelling (fig1A).

On intraoral Examination, A large, bilobed, reddish gingival mass around the maxillary right molar and extending both lingually and buccally was seen. The lesion also extended on occlusal surface of the right maxillary posterior region. The overall size of the lesion was 4 × 4 cm in all dimensions. The lesion was tender and bled easily upon palpation. The maxillary second molar showed Grade III tooth mobility. Enlarged, firm, mildly tender submandibular lymph nodes were palpable on the same side.



Fig.1 (A) preoperative photograph shows front view of patient, (B) radiographic interpretation of the lesion with resorption of bone in maxillary right second molar. (C)shows intraoral picture of lesion and its extension.

Palliative treatment:

The patient was advised oral prophylaxis with oral hygiene instructions; though the result was not promising. So, palliative treatment was advised. All blood investigations were under physiological limit. The patient's obstetrician was consulted and he approved of the treatment plan. Palliative treatment with excision of overgrowth as done. She was kept on follow up.

Histopathological report:

The histopathological section showed multiple vessels, areas of hemorrhage and residual fibrous proliferation with marked acute

inflammatory infiltrate consists of polymorphs, histiocytes (fig 2).

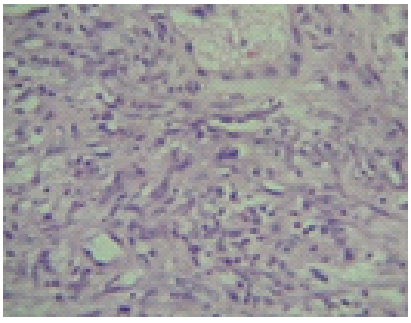

Fig.2 . shows the histopathological picture of multiple blood vessels with perivascular inflammatory infiltrate.(H and E stain).

After the full-term delivery of a healthy newborn patient showed recurrence of lesion. The profile showed increased size of lesion. CT-scan was advised 1-month post-partum when the swelling did not regress on its own.

CT scan:

Ct reporting suggested a heterogeneously ill-defined 58*41 mm sized lobulated lesion in right gingivobuccal sulcus, retro antral space and infra temporal fossa. Lesion caused pressure on cortical thinning and erosion of lateral wall of right maxillary sinus, maxillary alveolar arch and lateral pterygoid plate. Multiple enlarged lymph nodes in bilateral level 1b,2b and 3 level. (fig 3)

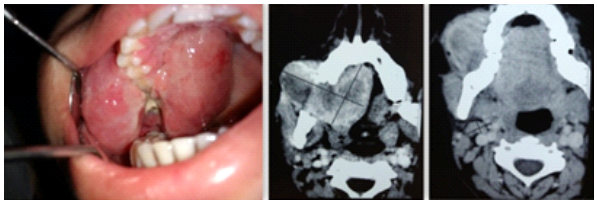

Fig.3(A): size of lesion clinically after 1-month post-partum period, and (B), (C), (D) on CT-scan.

Definitive treatment:

A definitive treatment was planned 1 month after her full-term delivery. Though the swelling should have regressed after post-partum, in our case it progressively increased. So, excision of lesion along with soft tissue reconstruction with buccal fat pad was done under general anesthesia. In the treatment the grade-iii mobile teeth were extracted. Uneventful healing was seen. And no recurrence was been documented in 1 year of follow up period. (Fig 4)

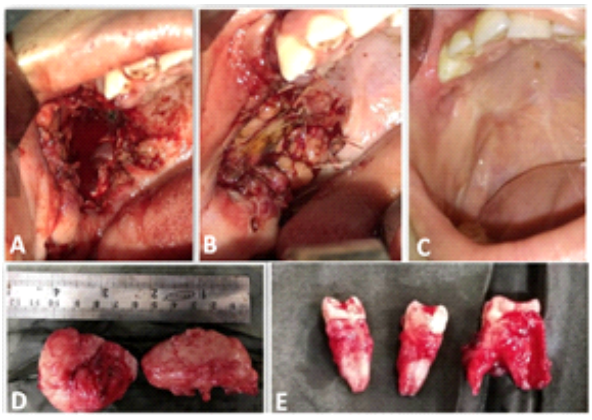

Fig.4. The surgical procedure (A) shows the mucosa after the excision of lesion, (B) shows the reconstruction of lesion with buccal fat pad. (C) shows post-operative photograph on follow-up. (D) shows gross specimen removed.(E) shows the teeth removed along-with.

MATERIALAND METHOD

3192 articles are documented in the English literature review from the year 1969 till 2018. PubMed database was used to conduct the literature review using the term 'oral pregnancy tumor'. Articles have also been searched from references of the articles.7 articles could not be documented because of unavailability.42 cases with oral pregnancy tumor out of which 23 articles were having >2 cm size were included. Similarly, in COCHRANE library the term searched was oral pregnancy tumor, 369 trials + 13 reviews were found out of which 0 articles matched the criteria.

Table 1: Analysis of literature review

Age				Trimester				Bone involved	Mean size	recurrence	
15-20	21-30	31-40	40 OR Above	1st	2nd	3rd	Post-partum			YES	NO
3	16	2	1	2	10	8	3	7	3. 361905	2	6

Table 2: Summary of the cases of the pregnancy tumour with size (>2 cm) in dimension. ("-" – no mention.)

SR NO	AUTHORS	Journal Name	Year	Age And Sex	Month of pregnancy	Area Involved	Size Of Lesion	Bone Loss	Mobility Of Teeth	Recurrence
1.	Nisha.S et al[2]	Journal of Dental and Allied Science	2018	20/F	2nd trimester	13 to17(maxillary right side)	5*4 cm	-	-	NO
2.	Shwetha c Chikkaboraiah et al[7]	Journal of health science and research	2016	23/f	1st trimester	24,25(maxillary left side)	4*3 cm		grade 1mobility in 24	-
3.	Divya Gayatri P S et al[8]	Int j oral health sci	2016	23/f	8th month	14 to 16(maxillary right side)	2*2*2.5 cm	NO	NO	-
4.	Arunmozhi Priya et al[9]	Journal of clinical and diagnostic research	2016	27/f	2nd month	tip of tongue	3*3 cm	-	-	NO
5.	Ritu Rana et al[10]	Cutis	2015	30/f	7 months	maxillary palatal incisors	3×3 cm	bone loss nr maxillary CI	-	Recurrence after 1 year
6.	Andrew Rockafellow et al[11]	Case reports in dentistry	2015	31/f	2 months post-partum	left maxilary gingiva	3.9 × 1.7 cm	interproximal bone loss between 24 and 25	24 is mesialy displaced	Recurrence after 6 weeks
7.	Wei-Lian Sun et al[12]	Journal of dental science	2014	22/f	-	multiple pgs in maxilla and mandible	largest size 3 cm	-	-	NO
8.	Ambika Sharma et al[13]	Laser therapy	2014	25/f	1 month postpartum	31 to 33(mandibular anterior left side)	4x4x5 cm	NO	NO	-
9.	Sohini Bhattacharya et al[14]	Reviews in obstretrics and gynecology	2013	25/f	6th month	Tip of tongue	3*3 cm	-	-	-

10.	Jaishree Garg et al[15]	Journal of Indian Society of Periodontology	2013	23/F	8 months	21, 22 and 23(maxillary led=ft region)	3.5 cm × 2 cm	Minimum bone loss	-	-
11.	Cardoso JA et al[16]	Journal of Applied Oral Science.	2013	patients out of 41	-	-	>2 cm	-	-	-
12.	Luis Eduardo et al[17]	Archives of Oral Research	2012	22/f	Fourth month	21 22(maxillary left anterior side)	21.0 × 10.0 × 7.0 mm	diastema 21,22	-	NO
13.	Priya K et al[1]	Oral & maxillofacial pathology journal	2012	27/f	2nd trimester	42 to 31(mandibular anteriors)	3 x 2.5 cms	-	-	-
14.	Deepak Kumar chopra et al[18]	General dentistry	2012	26/f	Five months	42,43(mandibular right side)	2.5*2.5 cm	-	-	-
15.	MARTINS-FILHO et al[19]	International journal of morphology	2011	20/f	19th week	21 to 22 maxillary left side	4*4 cm	resorption around 22	grade 3, nonvital 22	-
16.	J. Durairaj et al[20]	Journal of Obstetrics and Gynecology,	2011	23/f	38th week	Mandibular anterior labial and lingual side	4*3 cm	-	-	-
17.	Shailesh gondivkar et al[21]	Contemporary clinical dentistry	2010	25/f	Third trimester	34,35(mandibular premolar left side)	3*7 cm	interdental alveolar crest resorption	-	-
18.	Nitu shah et al[22]	The journal of Ahmedabad dental college and hospital	2010	22/f	5 months	47(mandibular right side)	2.5*2 cm	NO	NO	-
19.	Ababneh K, et al[6]	Journal of contemporary dental practice	2009	28/f	Fourth month	36,37(mandibular left side)	5*5 cm	36 furcation involvement	Present	-
20.	Yamoah K et al[23]	Journal of obstetrics and gynecology	2009	26/f	37 weeks	Maxillary anterior palatal side 12,11,21,22	4*4 cm	-	-	-
21.	Al-Omari B et al[24]	Rev laryngol otol rhinol.	2008	-	32 weeks	dorsum of tongue	4 cm	-	-	NO
22.	John L. Powell et al[25]	Lasers in Surgery and Medicine	1994	19/f	33 weeks	Mandibular right anterior gingiva	3.5 x2.5 x 2.0 cm	NO	NO	NO
23.	John macvicar et al[26]	J. Obstet. Cvnaec. Brit. Cwlth.	1969	33/f	4th month	mandibular left side gingiva	4*6 cm	-	-	-

DISCUSSION

The term pregnancy tumor was first coined by Blum in 1912. According to Ziskin and Ness clinical classification of pregnancy gingivitis, the present case falls under Class V [1].

Pregnancy tumor is usually not associated with bone loss and is not extensive. 47% of cases have shown bone formation on the contrary [3]. Our case involved bone resorption around the teeth extending till maxillary sinus which has not been documented previously. This shows the extensivity of the lesion.

It could be seen at any age. In our review of 23 patients, mean age of occurrence is found to be 39.15 years, which includes a range from 19 to 41 years. Our patient is 21 years old. Size varied from 2.1*1 cm to 5* 7 cm with average size of 3.361 cm. maxillary to mandibular ratio 1.16:1.

The common site of occurrence of pregnancy tumor is maxillary anterior [4]. Maxillary right posterior was involved in our case. It extensively involved all the tissues till maxillary sinus, occlusal surface of the molars, buccally and palatally involved. This presents its proliferative nature. In our literature review the site involved was most commonly seen maxillary left side.

Pregnancy tumor is usually seen in first or second trimester of pregnancy. In our case, it was in third trimester.in this analysis it was observed that maximum cases happened in second trimester. It is usually painless in nature. Our case showed tenderness due to opposing teeth in occlusion.

The cause of pregnancy is thought to be plaque and local factors. Trauma could be a possible cause for its proliferative nature. It has been related to hormonal changes. It is found that sex hormones like estrogen and progesterone receptors are present on epithelial cells of pregnancy tumor. But there have been no further studies as to why it particularly happens in some women and not all.

This lesion has a rapid growth rate but has not grown beyond 2 cm [5]. In the present case, a much larger size was found (5.8*4.1 cm). The usual size of pyogenic granuloma reported ranges from 0.3 × 0.2 × 0.1 cm to 2.1 × 1.3 × 0.8 cm with a mean of 1 × 0.7 × 0.5 cm [5]. The large size of lesion and the extensive bone loss and recurrence after removal pointed more towards a neoplasm.in the cases reviewed, it was seen that 7 cases showed bone loss and mobility of teeth were also noted in 4 patients.

Pregnancy tumor can be diagnosed based on clinical findings. Its histopathological findings are distinctive and only needed for differential diagnosis purpose. In the present study, histopathological examination was needed to rule out neoplasm as the lesion mimicked a neoplastic growth.

The treatment protocol to be followed for pregnancy tumor is removal of local factors. Once the local factors are removed and after delivery, a small pregnancy tumor subsides by itself [5]. During pregnancy, a strict oral hygiene is maintained and home care is to be followed. Surgical excision is usually done after delivery.

Usually surgical excision of lesion is done after delivery due to chances of its recurrence. But in present case the lesion was removed during pregnancy due to functional disturbances caused to patient and hinderance in daily activities like mastication and speech. In the present case, there was severe bleeding on slight provocation, so care was taken while doing the palliative treatment in pregnancy.

Differential diagnosis of a pregnancy tumor includes peripheral giant cell granuloma, peripheral ossifying fibroma, metastatic cancer, and hemangioma [6].

Funding: No funding was received

Conflict of interest: The authors declare that they have no conflict of interest

Ethical approval: All procedures performed in study involving human participant were in accordance with the ethical standards of the institutional and/or national research committee and with the 1964 Helsinki declaration and its later amendments or comparable ethical standards.

Informed consent: Informed consent was obtained from human participant included in the study.

REFERENCES:

[1]. Priya, K., Sekar, B., Augustine, D., & Murali, S. (2012). PERSISTENT PREGNANCY TUMOR: A CASE REPORT WITH REVIEW OF LITERATURE. Oral & Maxillofacial Pathology Journal, 3(2).
[2]. Nisha s, shivamallu ab, hedge u. Oral pregnancy tumor. J dent allied sci 2018; 7:47-50.
[3]. Anneroth, g., & sigurdson, å. (1983). Hyperplastic lesions of the gingiva and alveolar mucosa: a study of 175 cases. Acta odontologica scandinavica, 41(2), 75-86.
[4]. laine, m. A. (2002). Effect of pregnancy on periodontal and dental health. Acta odontologica scandinavica, 60(5), 257-264.
[5]. Ababneh, k., & al-khateeb, t. (2009). Aggressive pregnancy tumor mimicking a malignant neoplasm: a case report. J contemp dent pract [internet], 10(6), 072-078.
[6]. Jafarzadeh, h., sanatkhani, m., & mohtasham, n. (2006). Oral pyogenic granuloma: a review. Journal of oral science, 48(4), 167-175.
[7]. Chikkaboraiah s, puttaswamaiah rn, galgali sr. Pregnancy tumor. J health sci res 2016;7(1):23-27.
[8]. Divya gayatri p s, triveni m g, gaidhankar s, mehta d s, gayathri g v. Angiogranuloma in pregnancy: a case series and mini review. Int j oral health sci 2016;6:30-4.
[9]. Arunmozhi, u., priya, r. S., kadhiresan, r., sujatha, g., & shamsudeen-ss, s. M. (2016). A large pregnancy tumor of tongue–a case report. Journal of clinical and diagnostic research: jcdr, 10(10), zd10.
[10]. Rana, r., ramachandra, s. S., prasad, u. C., aggarwal, p., & dayakara, j. K. (2015). Recurrent pyogenic granuloma with a satellite lesion. Cutis, 96(2), e27-30.
[11]. Rockafellow, a., florin, w., philipone, e., & koslovsky, d. (2015). Pregnancy tumor in a 31-year-old female with a facial port-wine stain. Case reports in dentistry, 2015.
[12]. Sun, w. L., lei, l. H., chen, l. L., yu, z. S., & zhou, j. W. (2014). Multiple gingival pregnancy tumors with rapid growth. Journal of dental sciences, 9(3), 289-293.
[13]. Sharma, a., mathur, v. P., & sardana, d. (2014). Effective management of a pregnancy tumour using a soft tissue diode laser: a case report. Laser therapy, 23(4), 279-282.
[14]. Bhattacharya, s., bhattacharyya, s. K., & patua, b. (2013). Lingual pyogenic granuloma gravidarum. Rev obstet gynaecol, 6(2), 46-7.
[15]. Srivastava, a., gupta, k. K., srivastava, s., & garg, j. (2013). Massive pregnancy gingival enlargement: a rare case. Journal of indian society of periodontology, 17(4), 503.
[16]. Cardoso, j. A., spanemberg, j. C., cherubini, k., figueiredo, m. A. Z. D., & salum, f. G. (2013). Oral granuloma gravidarum: a retrospective study of 41 cases in southern brazil. Journal of applied oral science, 21(3), 215-218.
[17]. Cruz, l. E. R. N., martos, j., da silveira, j. C., & da silva, g. D. C. (2012). Clinical evaluation at two-year follow-up control of pregnancy granuloma. Archives of oral research, 8(1).
[18]. Chopra, d. K., gandhi, p., & kochar, d. (2012). Pregnancy tumor mimicking a neoplasm--a case report. General dentistry, 60(3), e182-4.
[19]. Con gran, t. A. D. E. G. P., & del hueso, p. (2011). Aggressive pregnancy tumor (pyogenic granuloma) with extensive alveolar bone loss mimicking a malignant tumor: case report and review of literature. Int. J. Morphol, 29(1), 164-167.
[20]. Durairaj, j., balasubramanian, k., rani, p. R., sagili, h., & pramya, n. (2011). Giant lingual granuloma gravidarum. Journal of obstetrics and gynaecology, 31(8), 769-770.
[21]. Gondivkar, s. M., gadbail, a., & chole, r. (2010). Oral pregnancy tumor. Contemporary clinical dentistry, 1(3), 190.
[22]. Nitu shah et al. (2010). pregnancy tumor of a 22yr old female. The journal of ahmedabad dental college and hospital;1 (2), Sep 2010- feb 2011.
[23]. Yamoah, k. K., lindow, s., & karsai, l. (2009). A large epulis in pregnancy. Journal of obstetrics and gynaecology, 29(8), 761-762.
[24]. Al-omari, b., keogh, i., waheed, k., hughes, j., & timon, c. (2008). Lingual granuloma of pregnancy. Revue de laryngologie-otologie-rhinologie, 129(4-5), 345-346.
[25]. Powell, j. L., bailey, c. L., coopland, a. T., otis, c. N., frank, j. L., & meyer, i. (1994). Nd: yag laser excision of a giant gingival pyogenic granuloma of pregnancy. Lasers in surgery and medicine: the official journal of the american society for laser medicine and surgery, 14(2), 178-183.
[26]. Macvicar, j., & dunn, m. F. (1969). Pregnancy tumour of the gums: a report of two cases. Bjog: an international journal of obstetrics & gynaecology, 76(3), 260-263.