ORIGINAL RESEARCH PAPER

Volume-7 | Issue-6 | June-2018 | PRINT ISSN No 2277 - 8179

INTERNATIONAL JOURNAL OF SCIENTIFIC RESEARCH

COMPARATIVE STUDY BETWEEN FOLLICULAR UNIT EXTRACTION (FUE) AND NON CULTURED MELANOCYTE TRANSFER (NCMT) IN STABLE VITILIGO PATIENTS

Dermatology

Tolani A	Third Year Postgraduate Student,Department of Skin and VD, Sri Aurobindo Medical College & Postgraduate Institute, Indore (M.P.)
Sharma K*	Third Year Postgraduate Student, Department of Skin and VD, Sri Aurobindo Medical College & Postgraduate Institute, Indore (M.P.) *Corresponding Author
Bhatia K	Professor and Head, Department of Skin and VD, Sri Aurobindo Medical College & Postgraduate Institute, Indore (M.P.)
Kataria R	Associate Professor,Department of Skin and VD, Sri Aurobindo Medical College & Postgraduate Institute Indore (M.P.)
Namdeo C	Associate Professor,Department of Skin and VD, Sri Aurobindo Medical College & Postgraduate Institute Indore (M.P.)
Kohli P	Third Year Postgraduate Student, Department of Skin and VD, Sri Aurobindo Medical College & Postgraduate Institute Indore (M.P.)
Sarin A	Third Year Postgraduate Student, Department of Skin and VD, Sri Aurobindo Medical College & Postgraduate Institute Indore (M.P.)

ABSTRACT

Background: Vitiligo is an acquired, hypomelanotic disorder characterized by circumscribed depigmented macules in the skin resulting from the loss of functional melanocytes from the cutaneous epidermis. It also causes significant psychological and social distress.

Aims and Objectives: To compare the efficacy of follicular unit extraction and non cultured melanocyte transfer in patients of stable vitiligo with respect to repigmentation, vitiligo noticeability and global treatment success.

Material and Methods: A total of 15 patients with stable vitiligo (as per IADVL guidelines) were enrolled in the study. In the same patient follicular unit extraction (FUE) was done in the vitiliginous lesions and the hair was transplanted approximately 3-5 mm apart on the left side of the body, while another vitiliginous lesion in the same patient was selected for non cultured melanocyte transfer (NCMT) which was done on the dermabraded area on the right side of the body. These patients were followed-up for a period of 6 months, initially at every 2 weeks or till first signs of repigmentation, then monthly follow-ups for two times and then followed-up in every 2 months. Visual analogue scale was used for assessment of repigmentation, VNS scale was used to evaluate vitiligo noticeability and global treatment success was calculated.

Results: There were 2 (13.3%) females and 13 (86.7%) males in our study, showing a male preponderance. Majority of the patients were in the age group 21-40 years (66.7%). There was statistically significant increase in the mean pigmentation at each follow-up in comparison to the earlier follow-up in both the groups ($p<0.05$). The mean pigmentation and mean pigmentation difference, between the two groups was also comparable ($p>0.05$). Excellent pigmentation was seen in 60% patients of FUE and 73.3% patients of the NCMT group. Vitiligo was 'not noticeable' in 33.3% patients of FUE and 40.0% patients of NCMT group. Global treatment success was 80% in both the groups. Bony prominence, greying and loss of follicles in FUE group; and graft displacement and herpes zoster in NCMT group were the factors responsible for low pigmentation.

Conclusion: From the above study, we conclude that repigmentation was seen in both the groups, with equal efficacy seen between the two methodologies. Thus, any method can be applied for repigmentation with due considerations to complications of each method used.

KEYWORDS

Follicular unit extraction, non-cultured melanocyte transfer,stable vitiligo patients, repigmentation, vitiligo noticeability, global treatment success

INTRODUCTION

Vitiligo is an acquired, hypomelanotic disorder characterized by circumscribed depigmented macules in the skin resulting from the loss of functional melanocytes from the cutaneous epidermis. Vitiligo also causes significant psychological and social distress. [1-5]

Vitiligo has an overall worldwide prevalence of 1% with incidence ranging from 0.1 to > 8.8% [6,7-12] across the country and in different countries of the globe.

There are many modalities for the treatment of vitiligo but there is still a need for a treatment that is promptly effective. Treatment of vitiligo by transplantation of autologous pigmented skin grafts or blister roofs has been carried out for about 45 years. Punch grafts can give rise to cobblestone-like scars, but this has been avoided by using blister roofs. The blisters have been produced on normal skin by suction and transplanted to white areas[13] Keeping in mind the near to resistant nature of this disease to almost all the modalities of the treatment, the present study has been done to find out the efficacy of autologus non-cultured melanocyte transfer in imparting pigmentation.

As noticed clinically, with any treatment for vitiligo, the repigmen tation usually begins at the orifice of hair follicles, which further enlarges and coalesces to cover whole vitiliginous areas; this indicates that repigmentation in vitiligo is closely related to hair follicles.

Thus the present was designed to find out the efficacy of autologous non-cultured melanocyte transfer and follicular unit extraction method in imparting pigmentation to the vitiliginous lesion.

AIMS AND OBJECTIVES

AIM

To find out the efficacy of follicular unit extraction and non-cultured melanocyte transfer in patients with stable vitiligo with respect to repigmentation, vitiligo noticeability and global treatment success.

OBJECTIVES

1. To assess repigmentation post follicular unit extraction and post non-cultured melanocyte transfer in stable vitiligo patches.
2. To study reduction in vitiligo patch noticeability post follicular unit extraction and post non-cultured melanocyte transfer in stable vitiligo patients.
3. To compare the pigmentation, vitiligo noticeability and global treatment success between the two methods.

MATERIAL AND METHODS

PLACE OF STUDY

The present study was carried at Department of Skin and Venereal Disease, Sri Aurobindo Medical College and Postgraduate Institute, Indore (M.P.)

STUDY POPULATION
All the patients visiting the institution during the study period with diagnosis of vitiligo based on presence of depigmented patch, history, duration, progression of disease, and appearance of chalky white on wood's lamp examination formed the study population. Convenient sampling technique was used for the present study.

STUDY PERIOD
September 2015 to September 2017 (2 years).

GROUPING
Follicular unit extraction (n=15): All the stable vitiligo patients received this treatment on the left side of their body.

Non-cultured Melanocyte Transfer (n=15): The same stable vitiligo patients received this treatment on the right side of their body.

INCLUSION CRITERIA
- Male and female patients of age between 18 to 37 years, with localized stable vitiligo as per the Indian Association of Dermatologists Venereologists and Leprologists (IADVL) Task Force for standard guidelines of care for dermatological procedures (A patient reporting no new lesions, no progression of existing lesions, and absence of Koebner phenomenon during the past 1 year).[14]
- Patient and/or his/her legally acceptable representative giving their voluntary written consent for participation in the study.

EXCLUSION CRITERIA
- Patients with active vitiligo lesions.
- Patients with a history of koebner phenomenon.
- Patients with keloidal tendency.
- Patients with a history of bleeding disorders.
- Patients with other hypopigmented disorders.
- Patient and/or his/her legally acceptable representative not giving their voluntary written consent for participation in the study.

PROCEDURES
The study was explained to the patients and their legally acceptable representatives in great detail viz. the procedures, risks/benefits, follow-ups, compliance, etc. After obtaining their verbal consent for participation in the study, a written informed consent was obtained from all the patients. Only after obtaining the consent, the study related procedures were initiated.

Details about the patient and a detailed history about the disease such as the site of onset, duration, progression, stability of the disease, and history of medication was taken. Any previous history of systemic diseases, endocrinological disturbances, bleeding tendency or herpes labialis was noted. The selected patients were thoroughly examined for the number of lesions, size, site, and type of vitiligo. Old scars and Bacillus Calmette-Guérin (BCG) scars were examined to exclude keloidal tendency.

All the patients were investigated for complete hemogram, bleeding time, and clotting time. Lignocaine sensitivity was tested before the surgery. Photographs were taken before the procedure and then periodically to compare the pigmentation and color match.

a. Follicular Unit Extraction (FUE):
Follicular unit grafting was done in the vitiliginous lesion and the hair was transplanted 3-5 mm apart approximately. After giving tumescent anesthesia at the donor site (lignocaine with 1:100,000 adrenaline diluted in the ratio of 1:10 with normal saline), the donor follicles were extracted using motorized 0.9mm sharp cylindrical punch [follicular unit extraction (FUE) technique]. The donor area was the occipital region of the scalp. Number of follicles extracted were as per the patient's requirement. The hair follicles so extracted were stored in Petri dish with cold normal saline till the extraction was complete. After infiltrative anesthesia at the recipient site, transplantation was done using 18-G needle to create slits in the recipient area and the hair follicle was gently inserted using a jeweler's forceps into the created slits. The hair follicles were transplanted intact as follicular units. After grafting an occlusive dressing was applied for 14 days. Topical corticosteroid or tacrolimus therapy was started after 14 days to facilitate repigmentation.

b. Non-cultured Melanocyte Transfer (NCMT):
The technique used was described by **Mulekar in 2005.**[15]

Donor Site Preparation:
The donor area was anesthetized with lidocain/epinephrine injected intradermally. Donor site was held flat and made taut by stretching. By holding the cutting edge of razor blade with artery forceps parallel to skin surface it was advanced to cut tangentially to obtain split skin graft of thinnest possible thickness according to requirement of recipient area. The main emphasis was given on the thinness of the graft rather than the continuity and a povidone iodine dressing was done.

Processing of the graft:
The grafts were placed on a Petri dish containing 0.2% EDTA-trypsin solution and incubated for 30 minutes at 37°C. After washing with normal saline, the epidermis was separated from the dermis in the same medium in a petridish. The dermis was discarded and the solution containing melanocyte-keratinocyte mixture was transferred to a plain vaccutainer and centrifuged for 6 min. at 2000 rpm. The cell pellet was resuspended in a 1 mL syringe.

Recipient site preparation:
The recipient area was anesthetized with lidocaine / epinephrine injected intradermally and submitted to low-speed dermabrasion. The cell suspension was mixed with methyl cellulose and then uniformly spread over the dermabraded area and the area covered with a collagen dressing, cotton pads and crepe bandage.

Post-operative care:
- The patient was instructed to perform only restricted movements for next one week.
- Recipient area dressing was opened after seven days.
- The patient was instructed not to scrub the recipient area for another one week.
- The patients were prescribed with topical 0.01% tacrolimus and oral antioxidants.

ASSESSMENT
The patients were followed up regularly for a period of 6 months, initially at 1 month, then at two months, then at fourth month and last at sixth month. The results were assessed at the end of 6 months for the extent of repigmentation, reduction in vitiligo noticeability and complications.

Three methods were devised for assessment:
One with an observer opinion who was a third person apart from patient and study researcher. The observer belonged to medical fraternity.

The degree of repigmentation was evaluated qualitatively on the basis of visual analogue system score for the extent of pigmentation on the basis of photographs taken on every follow-up. Hair were trimmed each time to maintain the uniformity & better visuality of pigmentation in photographs.

0-25%	Poor response	Grade I
26-50%	Fair response	Grade II
51-75%	Good response	Grade III
76-100%	Excellent response	Grade IV

The second method took into consideration the patient's assessment on vitiligo noticeability of the lesion at the end of six months post procedure.[16]

Question: Compared with before treatment, how noticeable is the vitiligo now?

Response options:

More noticeable	(1)
Same as before	(2)
Little less noticeable	(3)
A lot less noticeable	(4)
Not noticeable	(5)
Success criteria	VNS score of 4 or 5

Third clinician reported global treatment success: Treatment success was defined as 'yes' on global assessment with a VNS score of 4 or 5, and >75% repigmentation.[16]

Thus this study took into consideration three different evaluation scales for assessment of the therapeutic utility of the procedure.

Hair in the vitiliginous patch was also observed for any change in pigmentation.

Only one session was carried out with each patient.

METHOD OF DATA COLLECTION

A customized proforma was designed for the study purpose, and also observational method was used for getting any information.

OUTCOME MEASURES

Repigmentation as assessed using Visual Analogue Scale, vitiligo noticeability using VNS scale and global treatment success, along with complications.

STATISTICAL ANALYSIS

Initially data was captured on to the customized proforma and then transferred to Microsoft Excel for analyzing the data. Online statistical software were used for calculating the p value. The mean comparison between the two groups was done using Unpaired 't' test, while comparison within the group was done using Paired 't' test. A p value of < 0.05 was considered as statistically significant.

FINANCIAL INPUTS AND FUNDING

All the patients were charged according to schedule of charges laid down by the institution for the treatment, but no additional procedures / tests were done for the specific requirement of the study, hence there was no additional financial burden either on the patient or the institution. This study was also not sponsored by any pharmaceutical company or institution. All the study related costs were borne by the investigators.

ETHICAL CONSIDERATIONS

The protocol of the study was submitted to the Ethics Committee of our institution. After their approval, the present study was initiated in the institution. Also prior to enrollment into the study, a voluntary written informed consent form was obtained from the patients for participation in the study. This consent was in addition to the consents obtained for the treatment of such patients.

RESULTS

In all 15 patients were enrolled in the study. There were 2 (13.3%) females and 13 (86.7%) males in our study, showing a male preponderance. Majority of the patients were in the age group 21-40 years (66.7%).

The areas of the body chosen for follicular unit extraction was left beard area, left cheek, left chest, left foot, left forearm, left hand, left leg, left shin, left upper arm and left upper back; while the areas chosen for non-cultured melanocyte transfer were right beard area, right cheek, right chest, right foot, right forearm, right hand, right leg, right shin, right upper arm and right upper back.

Mean pigmentation in follicular unit extraction group:

The mean pigmentation (VAS) in the follicular unit extraction group at 1 month was 15.67 ± 7.29%, at 2 months it was 35.67 ± 14.98%, at 4 months it was 58.67 ± 20.74% and at 6 months it was 74.00 ± 26.19%. There was a statistically significant increase in the pigmentation at each follow-up in comparison to the earlier follow-up ($p<0.05$). [Table 1]

Table 1 : Comparison of mean pigmentation (VAS) in the FUE group at different follow-ups

Group	Follow-up	No. of Patients	Pigmentation (%) Mean ± SD	't' value	p value
FUE	1 month	15	15.67 ± 7.29	-8.367, df=14	0.000*
	2 months	15	35.67 ± 14.98		
	2 months	15	35.67 ± 14.98	-10.095, df=14	0.000*
	4 months	15	58.67 ± 20.74		
	4 months	15	58.67 ± 20.74	-6.782, df=14	0.000*
	6 months	15	74.00 ± 26.19		

Mean pigmentation in non-cultured melanocyte transfer group:

The mean pigmentation (VAS) in the non-cultured melanocyte transfer group at 1 month was 15.67 ± 7.29%, at 2 months it was 35.67 ± 14.98%, at 4 months it was 58.67 ± 20.74% and at 6 months it was 74.00 ± 26.19%. There was a statistically significant increase in the pigmentation at each follow-up in comparison to the earlier follow-up ($p<0.05$). [Table 2]

Table 2 : Comparison of mean pigmentation (VAS) in the NCMT group at different follow-ups

Group	Follow-up	No. of Patients	Pigmentation (%) Mean ± SD	't' value	p value
NCMT	1 month	15	18.67 ± 7.67	-8.935, df=14	0.000*
	2 months	15	39.67 ± 13.02		
	2 months	15	39.67 ± 13.02	-8.293, df=14	0.000*
	4 months	15	61.33 ± 20.31		
	4 months	15	61.33 ± 20.31	-5.134, df=14	0.000*
	6 months	15	72.67 ± 22.75		

Comparison of mean pigmentation between the two groups:

The mean pigmentation at 1 month, 2 months, 4 months and 6 months between the follicular unit extraction group and non-cultured melanocyte transfer group was found to be statistically not significant ($p > 0.05$), showing comparable pigmentation. [Table 3]

Table 3 : Comparison of mean pigmentation (VAS) between the FUE and NCMT group at 1 month, 2 months, 4 months and 6 months follow-ups

Follow-up	Group	No. of Patients	Pigmentation (%) Mean ± SD	't' value	p value
1 month	FUE	15	15.67 ± 7.29	-1.098, df=28	0.281, NS
	NCMT	15	18.67 ± 7.67		
2 months	FUE	15	35.67 ± 14.98	-0.780, df=28	0.442, NS
	NCMT	15	39.67 ± 13.02		
4 months	FUE	15	58.67 ± 20.74	-0.356, df=28	0.725, NS
	NCMT	15	61.33 ± 20.31		
6 months	FUE	15	74.00 ± 26.19	0.149, df=28	0.883, NS
	NCMT	15	72.66 ± 22.75		

Comparison of mean pigmentation difference between the two groups:

The difference in the pigmentation was calculated between 2 months to 1 month; 4 months to 2 months; and 6 months to 4 months and then compared between the two groups. The difference was found to be statistically not significant ($p>0.05$), showing a comparable mean pigmentation difference between the two groups. [Table 4]

Table 4 : Comparison of mean pigmentation difference (VAS) between the FUE and NCMT group between various follow-ups

Difference	Group	No. of Patients	Pigmentation (%) Mean ± SD	't' value	p value
2 months – 1 month	FUE	15	20.00 ± 9.26	-0.298, df=28	0.768, NS
	NCMT	15	21.00 ± 9.10		
4 months – 2 months	FUE	15	23.00 ± 8.82	0.385, df=28	0.703, NS
	NCMT	15	21.67 ± 10.12		
6 months – 4 months	FUE	15	15.33 ± 8.76	1.266, df=28	0.216, NS
	NCMT	15	11.33 ± 8.55		

Comparison of VAS grades between the two groups at 6 months:

At 6 months, 'excellent' pigmentation was seen in 60% patients of the FUE group and 73.3% patients of the NCMT group; 'good' pigmentation was seen in 20% patients of FUE group and 6.7% patients of the NCMT group, 'fair' pigmentation was seen in 6.7% patients each in both the groups; and 'poor' pigmentation was seen in 13.3% patients each in both the groups. There was no statistically significant association seen between the VAS grade at 6 months and the groups ($2=1.200$, df=3, $p=0.753$), showing comparable distribution in both the groups in relation to VAS grade. Our study results corroborate with the study done by **Thakur et al**[17] who also reported excellent repigmentation in 61.9%, good in 25.4% and poor in 12.7% with follicular unit extraction method.

Pandya et al[18] reported that an excellent response was seen in 52.17% cases with non-cultured epidermal suspension technique. According to **Van Geel et al**[19] a significant repigmentation was observed in 70% of patients. Best results were reported by **Mulekar et al**[20] in segmental vitiligo (84%).

Vitiligo Noticeability (VNS):

At 6 months, VNS was 'more noticeable' in 6.7% patients each in both

the groups; it was 'same as before' in 6.7% patients each in both the groups; it was 'little less noticeable' in 6.7% patients each in both the groups; it was 'a lot less noticeable' in 46.7% patients of FUE group and 40.0% patients of NCMT group and it was 'not noticeable' in 33.3% patients of FUE group and 40.0% patients of NCMT group. There was no statistically significant association seen between the VNS at 6 months and the groups (2=0.168, df=4, p=0.997), showing comparable distribution in both the groups in relation to VNS grade.

Factors responsible for low pigmentation:

In the FUE group, bony prominence was responsible in 6.7% patients; greying in 6.7% patients and loss of follicles in 6.7% patients for low pigmentation; while in the NCMT group, graft displacement was seen in 13.3% patients and herpes zoster was seen in 6.7% patients.

Global Treatment Success:

The global treatment success was seen in 80.0% patients each in both the groups, showing a comparable success rate in both the groups. [Fig. 1 and 2]

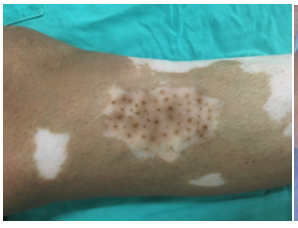

Figure 1 : Repigmentation seen after 6 months post FUE



Figure 2 : Repigmentation seen after 6 months post NCMT

CONCLUSION

Follicular unit extraction procedure gives negligible scarring compared to other procedures like punch grafting, split-thickness skin grafting, and blister technique all of which have visible scar at the donor site. Further this method is best suited for smaller lesions on hair bearing areas. Vitiligo with leukotrichia has an exhausted melanocyte reservoir which makes it procedure of choice in such cases. Non Cultured Melanocyte Transfer method can be done on a comparatively larger area even in the non-hairy region of the body. Thus, based on the site, area and associated features, an appropriate method can be adopted.

LIMITATIONS

All the surgical modalities in vitiligo have some or the other limitations. Each case should be individualized and best technique suitable should be chosen.

Both the procedures need due expertise & can become cumbersome if it has to be done on larger area, moreover FUE can only be done on hairy sites. Females do not show much interest in this method due to apprehension of unwanted hair on the body. Retention of hair follicles in non-hairy areas should be studied further.

The only drawback of NCMT observed was the time it takes to complete the procedure.

Moreover, larger sample size, comparative studies with other surgical modalities and longer follow ups should be carried out for better evaluation of the above procedures.

ACKNOWLEDGEMENTS

We kindly acknowledge the support provided to us from the Library of the institution and the other consultants and co-postgraduates for providing us support from time to time.

References

1. Mehta NR, Shah KC, Theodore C, Vyas VP, Patel AB. Epidemiological study of vitiligo in Surat area, South Gujarat. Indian J Med Res.1973;61:145-54.
2. Parsad D, Pandhi R, Dogra S, Kanwar AJ, Kumar B. Dermatology life quality index score in vitiligo and its impact on the treatment outcome. Br J Dermatol. 2003;148:373–4.
3. Noh S, Kim M, Park CO, Hann SK, Oh SH. Comparison of the psychological impacts of asymptomatic and symptomatic cutaneous diseases:vitiligo and atopic dermatitis. Ann Dermatol. 2013;25:454-61.
4. Silverberg JI, Silverberg NB. Quality of life impairment in children and adolescents with vitiligo. Pediatr Dermatol.2014;31:309-18.
5. Al-Shobaili HA. Correlation of clinical efficacy and psychosocial impact on vitiligo patients by excimer laser treatment. Ann Saudi Med.2014;34:115-21.
6. Srivastava G. Vitiligo - Introduction Asian Clinic. Dermatol. 1994;1:1-5.
7. Shwartz RA, Janniger CK. Vitiligo. Cutis. 1997;60:239-44.
8. Hann SK, Park YK, Chun WH. Clinical feature of vitiligo. Clin Dermatol 1997;15:891-7.
9. Kovacs SO. Vitiligo. J Am Acad Dermatol 1998;38:647-66.
10. Agarwal G. Vitiligo: An under - estimated problem. Fam Pract. 1998;15:519-23.
11. Handa S, Kaur I. Vitiligo - Clinical findings in 1436 patients. J Dermatol Tokyo. 1999;26:653-7.
12. Alkhateeb A, Fain PR, Thody A, Bennett DC, Spritz RA. Epidemiology of vitiligo and associated autoimmune diseases in Caucasian probands and their families. Pigment Cell Res. 2003;16:208-14.
13. Gauthier Y, Benzekri L. Non-cultured epidermal suspension in vitiligo: From laboratory to clinic. Indian J Dermatol Venereol Leprol 2012;78:59-63.
14. Prasad D, Gupta S. IADVL Dermatosurgery Task Force. Standard guidelines of care of vitiligo surgery. Indian J Dermatol Venerol Leprol. 2008;74(Suppl):S37–45.
15. Mulekar S. Long-term follow-up study of 142 patients with vitiligo vulgaris treated by autologous, non-cultured melanocyte-keratinocyte cell transplantation. Int JDermatol. 2005;44:841-5.
16. Batchelor JM, Tan W, Tour S, Yong A, Montgomery AA, Thomas KS. Validation of the Vitiligo Noticeability Scale: a patient-reported outcome measure of vitiligo treatment success. Br J Dermatol. 2016 Feb;174(2):386-94.
17. Thakur P, Sacchidanand S, Nataraj H, Savitha A. A Study of Hair Follicular Transplantation as a Treatment Option for Vitiligo. Journal of Cutaneous and Aesthetic Surgery. 2015;8(4):211-7.
18. Pandya V, Parmar KS, Shah BJ, Bilmora FE. Study of autologous melanocyte transfer in treatment of stable vitiligo. Indian J Dermatol Venereol Leprol 2005;71:71-3.
19. Van Geel N, Ongenae K, Vander Haeghen Y, Vervaet C, Naeyaert JM. Subjective and objective evaluation of non-cultured epidermal cellular grafting for repigmenting vitiligo. Dermatology 2006;213:23-9.
20. Mulekar SV. Melanocyte-keratinocyte cell transplantation for stable vitiligo. Int J Dermatol 2003;42:132-6.