ORIGINAL RESEARCH PAPER

Volume-8 | Issue-1 | January-2019 | PRINT ISSN No 2277 - 8179

INTERNATIONAL JOURNAL OF SCIENTIFIC RESEARCH

COMPARATIVE STUDY OF HARMONIC SCALPEL VERSUS MONOPOLAR COAGULATION AND TITANIUM CLIPS IN LAPAROSCOPIC CHOLECYSTECTOMY

Surgery

Dr. Anoop Kumar Singh Assistant Professor, Deptt. Of Surgery Govt. Allopathic Medical College, Banda(U.P.)

ABSTRACT

The purpose this study was undertaken to evaluate the safety and efficacy of harmonic scalpel in laparoscopic cholecystectomy in comparison to standard clip application to ligate and divide cyst artery and duct.

KEYWORDS

Laparoscopic cholecystectomy, harmonic scalpel, electrosurgery/cautery, cyst artery and duct.

INTRODUCTION

Laparoscopic cholecystectomy is considered worldwide the "gold standard" in the surgical treatment of symptomatic gallstones and because it offers well-known and more definite advantages in comparison with the open procedure.

The standard laparoscopic cholecystectomy is usually performed using a monopolar electrosurgical hook for dissection and clips for occlusion of the cystic dust and cystic artery. Alternative techniques for duct ligation have included linear stapler, endoloops, or sutures, which are, however, seldom used.

Even if laparoscopic cholecystectomy is considered a safe procedure, some pitfalls are associated with the use of the monopolar electric scalpel, such as the high risk of thermal injuries and significantly more common postoperative biliary complications. Furthermore, not to be underestimated are visceral and solid organ injuries caused by the frequent instrument exchange, such as bile leakage due to slippage of the clips.

The ultrasonically activated scalpel (Harmonic) was introduced into surgical patient more than a decade ago. This technology relies on the application of ultrasound within the harmonic frequency range to tissues and allows 3 effects that act synergistically :coagulation, cutting, and cavitation. The temperature obtained and the lateral energy spread are lower than those detected when the monopolar hook is used, thus reducing the risk of tissue damage. The Harmonic scalpel is also an effective tool for closure of biliary ducts and vessels whose diameter is <4mm to 5 mm (as certified by the FDA in 2006).

In addition, the elimination of inadvertent, Sometimes unrecognized, electrical arcing injuries with their potentially hazardous sequelae supported the role of the Harmonic scalpel as a potentially safer instrument for tissue dissection. One additional benefit of Harmonic scalpel dissection of the liver bed is the more effective closure of the ducts of Luschka. While rarely of clinical sighificance, bile leakage from the liver bed may contribute to postoperative pain, small bilomas, and the occasional return to the operative room.

Since its inception, the Harmonic scalpel has gained significant clinician acceptance and applications. Uses now range widely to include surgery of the head and neck, chest, liver,spleen,kidney, adrenal glands, colon, rectum, gastroesophageal junction, and others.

The Harmonic Scalpel's biggest advantage is the reduced bleeding and recovery time for the patient. Other advantages include the ability for a surgeon to make more precise cuts, and an overall reduction of lateral thermal tissue damage in comparison to other operating divices. There is also significantly less desiccation and charring of the blood vessels when the Harmonic Scalpel is used for surgery. Finally, the device requires less instrument exchanges than other techniques do during surgery.

Whereas a Bovie performs its action via an electrical current (and production of heat), the Harmonic scalpel cuts via vibration. The scalpel surface itself cuts through tissue by vibrating in the range of 20,0000 Hz. The vibration cuts through the tissue and seals it using protein denaturization, rather than heat. A good analogy is whisking an egg white; denaturation of the protein by vibration rather than heat.

This study is undertaken to compare the efficacy, safety, complications and cost effectiveness of the harmonic scalpel for dividing cystic artery and duct and the entire dissection from the liver bed versus traditional clip and cautery dissection as is done in American approach.

AIMS AND OBJECTIVES

1. To assess the role of harmonic scalpel in clipless laparoscopic cholecystectomy.

2. To assess the morbidity and evaluate the outcome in terms of operative time, blood loss, lateral thermal tissue damage, complications and recovery time.

MATERIAL AND METHODS

This prospective study namely "A study of Clipless Laparoscopic cholecystectomy using Harmonic scalpel V/s traditional clip application in patients with gall stone disease" was conducted in department of surgery in 60 patients undergoing elective laparoscopic cholecystectomy for gallstones. 60 Patients were included in this study who were randomized in two groups of 30 patients each in study group and control group respectively.

ELIGIBILITY CRITERIA :

INCLUSION CRITERIA :

1. Age between 17 to 80 years.
2. Symptomatic cholelithiasis (biliary colic, acute cholecystitis)
3. Gallstone pancreatitis.

EXCLUSION CRITERIA :

1. Unable to tolerate general anesthesia.
2. Refractory coagulopathy.
3. Suspicion of carcinoma.
4. Previous multiple upper abdominal surgery.
5. Cholangitis
6. Diffuse peritonitis.
7. Cirrhosis or portal hypertension.
8. Chronic obstructive pulmonary disease.
9. Cholecysto-enteric fistula.
10. Morbid obesity.
11. Pregnancy.

The patients were prospectively randomized into two groups :

Group A - Includes all cases that were treated by using harmonic scalpel.

Group B - Includes all cases that were treated by using monopolar coagulation and titanium clips.

CASE SHEET

NAME OF PATIENT BHT NO.

AGE AND SEX D.O.A.

WARD/BED D.O.O.

ADDRESS D.O.D.

RELIGION

HISTORY OF PRESENT ILLNESS :

PAST HISTORY :

FAMILY HISTORY :
PHYSICAL EXAMINATION :
GENERAL EXAMINATION :

Condition of the patient
pulse
B.P.
R/R
Temperature
Pallor

Cyanosis.
SYSTEMIC EXAMINATION :
C.N.S.
C.V.S.
Respiratory
P/A
Per-rectal examination

INVESTIGATION :
A-Routine blood test -

- Hb
- TLC
- DLC
- Blood urea
- S. creatinine
- blood sugar
- S. electrolytes
- Liver function tests (S. Bilirubin, S.G.O.T., S.G.P.T.,S. Alkaline phosphatase)

B-Radiography -

- x-ray chest-PA view
- USG abdomen
- ECG (if age>40 years)

Informed consent : All the eligible candidates were explained about the examining procedure and investigations used study and a written informed consent was taken.

Pre-operative Antibiotic prophylaxis was administered in all cases.
Pre-operative data :

A. Age of Patient (17-84 age)
B. Gall bladder pathology on ultrasonography abdomen.
C. Any other relevant finding.

The assessment were done under the following heads :
Intra-operative assessment -
(a) Mean Operative time
(b) Blood Loss
(C) Mean duration no. of time lens cleaned
(d) Lateral tissue damage

Post-operative assessment -
(a) Post operative pain
(b) Mean drainage
(C) Mean duration of hospital stay

Anaesthesia given - General anaesthesia.
Position - Patient should be supine with arms tucked to the side with right side up and head end up (American technique)

OPERATIVE TECHNIQUE –

60 subjects were divided randomly into groups of each. One group underwent traditional laparoscopic cholecystectomy using clips and whole dissection was done by Maryland dissector, whereas other group underwent clipless laparoscopic cholecystectomy using harmonic scalpel.

First cystic artery was identified and dissected. It was inserted between jaws of harmonic ACE. Then it was divided by activation of harmonic ACE. Then it was ascertained that there was no micro-calculi in the lumen of the cystic duct by moving the jaws of the harmonic ACE up and down. The duct was inserted between the jaws at a safe distance from common bile duct to avoid damage to it then the jaws were closed. The harmonic was activated to power level 3 and during this phase, great care was taken to avoid stretching or rotating cystic duct rather to keep it still until the gall bladder was detached from the cystic duct. Then the cutting point of the cystic duct was checked for any bile leakage. Irrigation was done with normal saline and hemostasis was achieved. Finally intra-abdominal drain was inserted in hepatorenal pouch in all patients of both the groups.



HARMONIC SCALPEL

The analysis included -

The operative time, number of times the lens cleaned during surgery, intra operative diffculties, gall bladder perforation with or without spillage of stones in peritoneal cavity and any spillage of bile in the peritoneal cavity were recorded.

Post operative follow-up included -

- Repeated clinical examination (Pulse rate, Temperature, Blood Pressure, Respiratory Rate and Abdominal examination) till discharge.
- Drain output, nature of output(serous, bilious or hemorrhagic).
- Post operative pain was recorded on visual analogue scale (VAS) at 1, 4 and 24 hrs after the surgery.
- Post operative investigations in the form of abdominal ultrasound on day 2 with special attention to the presence or absence of any subhepatic collection, full blood count, assessment of liver functions (SGPT, SGOT, Total Bilirubin, Direct Bilirubin, Alkaline Phosphatase) and renal functions were recorded. Drain was removed when it was not draining. Patient were discharged once they were tolerating oral feeds are there was no abnormality on clinical examination. Follow up was done upto 6 months.

Findings were noted and tabulated. Data analyzed statistically using 't' test. Table 't' value was 1.98. Test significant when calculated 't' value is greater than table 't' i.e. $p<.05$.

Then conclusion were drawn after analysis.

OBSERVATIONS & RESULT

In the present study "A study of Clipless Laparoscopic cholecystectomy using Harmonic scalpel V/s traditional clip application in patients with gall stone disease" sixty (60) patients in two groups were included. The study was carried out at Sarojini Naidu Medical College Hospital during the period from Nov. 2011 to Oct 2013.

The observations noted were as follows :
There were 21 (70%) females and 9(30%) males in group 1 (study group) and 24 females (80%) and 6 males (20%) in group 2 (control group). The age range for group 1 was 20-60 years, and that for group 2 was 20-70 years. Mean age for study group was 37.9 yrs and mean age for control group was 39.5yrs.

1. AGE/SEX -

a. Study group -

TABLE 1 - Showing Age/Sex Distribution of study group

AGE GROUP	NO. OF CASES	M	F	% OF CASES TOTAL(M/F)
0-10	0	0	0	0
20-30	6	0	6	20(0/20)
30-40	12	4	8	40(13.36/26.72)

40-50	9	4	5	30(13.36/16.67)
50-60	3	1	2	10(3.34/6.68)
60-70	0	0	0	0
70-80	0	0	0	0

Above table shows the break-up of the number of cases in the different age/sex groups.

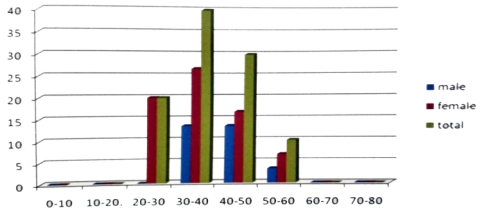

Age/Sex Distribution of study group.

b. Control group -

TABLE 2 - Showing Age/Sex Distribution of control group

AGE GROUP	NO. OF CASES	M	F	% OF CASES
0-10	0	0	0	0
10-20	0	0	0	0
20-30	6	1	5	20(3.34/16.67)
30-40	15	3	12	50(10/40)
40-50	3	0	3	10(0/10)
50-60	3	1	2	10(3.34/6.68)
60-70	3	1	2	10(3.34/6.68)
70-80	0	0	0	0
80-90	0	0	0	0

Above table shows the break-up of the number of cases in the different age/sex groups.

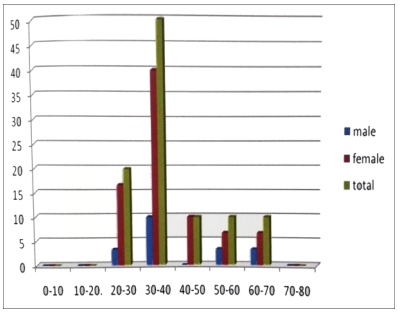

Age/Sex Distribution of Control group

2. Post operative pain -

TABLE - 2 :- Showing Statistical analysis of post operative pain

	POST OPERATIVE PAIN (MEAN) ON VAS (1-10)	t VALUE	p VALUE
STUDY CASES	3.88	0.76	NS
CONTROL CASES	3.98		

Post operative pain was measured with visual analogue scale (VAS) graded between 1-10 according to the patient's perception. Mean post operative pain in study group was 3.88 (range 1 to 8) and in control group was 3.98 (range 1 to 7). On statistical analysis no significant difference was found in both these group (TABLE-2).

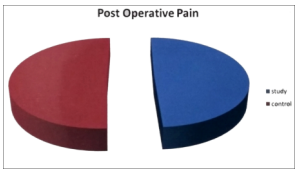

3. OPERATIVE TIME -

TABLE - 3 :- Showing Statistical analysis of operative time.

	OPERATIVE TIME (MEAN)	S.D.	t VALUE	p VALUE
STUDY CASES	42.40 MIN	8.97	1.11	0.272
CONTROL CASES	44.90 MIN	8.49		

Mean operative time in study group was 42.40 min (range 28 to 60 mins) and in control group was 44.90 min (range 30 to 65 mins). On Statistical analysis no significant difference was found in operative time of both the groups (TABLE-3).

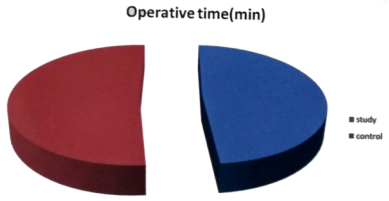

4. DRAINAGE -

Table - 4 : Showing Statistical analysis of drainage.

	DRAINAGE (MEAN)	S.D.	t VALUE	p VALUE
STUDY CASES	46.83 ml	14.35	0.43	0.67
CONTROL CASES	48.16 ml	9.05		

Mean drainage in study group was 46.83 ml (range 20 to 80 ml) and in control group was 48.16 ml (range 20 to 180 ml.) On Stantistical analysis no significant difference was found in drainage of both the groups(Table-4)

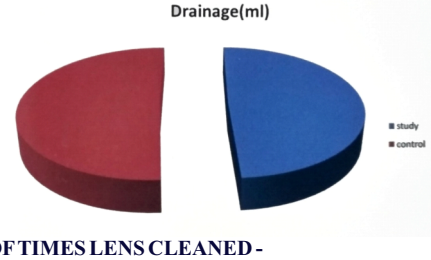

5. NO. OF TIMES LENS CLEANED -

Table - 5 : Showing Statistical analysis of no. of times lens cleaned.

	NO. OF TIMES LENS CLEANED	S.D.	t VALUE	p VALUE
STUDY CASES	1.43	0.5	7.72	0.0001
CONTROL CASES	2.57	0.63		

Mean duration no. of times lens cleaned during surgery in study group was 1.43 and in control group was 2.57. On Statistical analysis significant difference was found in both these groups (TABLE - 5)

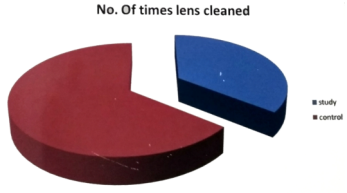

6. HOSPITAL STAY -

Table - 6 : Showing Statistical analysis of duration of hospital stay.

	HOSPITAL STAY (MEAN)	S.D.	t VALUE	p VALUE
STUDY CASES	2.0 DAYS	0.51	1.16	0.25
CONTROL CASES	2.13 DAYS	0.37		

Mean duration of hospital stay in study group was 2.0 days (range 1.5 to 3 days) and in control group was 2.13 days (range 1.5 to 9 days). On Statistical analysis no significant difference was found in both these groups (TABLE - 6)

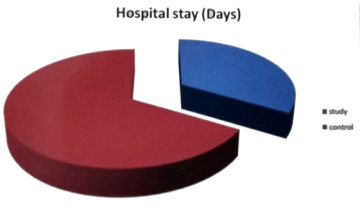

7. COMPLICATIONS -

In our study cases none of the patient had any bile duct injury. In control group there was single patient who had bile duct injury which was managed conservativly.

8. COST -

Single harmonic shear was used group which costed about Rs. 27000, i.e. Rs 900 per patient. In control group liga clip of 300 and 400 sizes were brought by the patient which costed about Rs 550 per patient. So we found that there was significant difference of cost in both the groups.

DISCUSSION

Laparoscopic cholecystectomy has become the standard practice, but it is associated with small percentage (0 to 1.28%)1, 2, 3, 4 of biliary tract injuries which can be avoided by careful dissection, minimum use of cautery and avoiding nonabsorbable suture material. In laparoscopic cholecystectomy, ligation of the cystic duct by metal clips is a routine procedure due to its ease. Nonetheless, there are reposts of both clip slippage and migration into the biliary tract 5, 6 7, 8, 9. Furthermore, CBD stone formation due to migration of various mono and polyfilament ligature materials has also been reported10. With the advent of ultrasonically activated shears laparoscopic procedures, have become more promising in terms of ergonomics and safety. There have been other reports on the use of ultrasonically activated devices during laparoscopic cholecystectomy 10, 11, 12, in which the harmonic scaplel or shears were employed for dissection only or for dividing the cystic artery.

In 1999, the use of ultrasonically activated shears for both dissection and closure-division of the cystic duct and artery was first reported.

The present sutdy "A study of Clipless Laparoscopic cholecystectomy using Harmonic scalpel V/s traditional clip application in patients with gall stone disease", sixty (60) patients were included. The study was carried out at department of surgery, Sarojini Naidu Medical College Hospital during the period from Nov. 2011 to Oct. 2013.

The current study was performed to determine the possible role of ultrasonically activated scissors in laparoscopic cholecystectomy, mainly focusing on the reduction of operation time, Bile duct injuries and biliary complications.

It has been reported that with ultrasonic energy, there is a ninimal lateral spread of vibration current in the surrounding tissues minimizing the risk of injury compared with monopolar electrocautery, which is associated with 90% of visceral injuries and 15% of biliary tract injuries during laparoscopic cholecystectomy13.

Three animal studies confirmed the increased lateral spread of thermal energy from monopolar electrocautery and subsequent increased tissue injury compared with ultrasonic energy14, 15. Safety of electrosurgical devices may also be compromised by the possible failure of insulation of the active electrode, which may lead to electrical "coupling" with other surgical instuments or tissue with subsequent generation of stray electrical current15. However, in a more recent controlled animal trial, monopolar electrocautery produced negligible thermal injury in the extrahepatic biliary ducts after laparoscopic cholecystectomy16.

Although some authors argue that the safety of the ultrasonic dissector may be enhanced by the reduced need for instrument replacement during surgery, other demonstrated that ultrasonic dissection is not as safe as it was initially perceived.

Tabala17 (2006) argues that because the Harmonic scalpel can replace 4 instruments [scissors, clipper, dissector (such as Maryland dissector), and electrocautery hook], and because that in the classical technique using electrocautery, frequent change (extraction and reinsertion) of instruments can increase the risk of tissue injury, such as bowel or liver, multiple functions of the Harmonic scalpel may eliminate the need for instrument change, thus reducing the risk of tissue injury. While this could be true, the risk of tissue injury by ultrasonic dissection remains clear and has been demonstrated by others.

An experimental animal study by Emam and Cuschieri18 (2003) showed that high-power ultrasonic dissections resulted in considerable heat production that caused proximal collateral damage to adjacent tissues when continuous activation time exceeded 19 seconds. Because data are conflicting regarding the potential benefits and risks of ultrasonic dissection in laparoscopic cholecystectomy, this study attempts to further explore such outcomes that could be related to tissue handling and any resulting tissue injury.

Ultrasonic shears have proven effective in a number of advanced laparoscopic procedures, providing better control of oozing from dissected tissues and making the procedures more expeditious. Long-lasting application of ultrasonic energy on vessels causes collagen in the wall to denature and seal the lumen. Application of ultrasonic energy to other hollow structures, such as the cystic duct, has been proven to have similar tissue effects.

Histology examination of the cystic duct clearly showed the sealing of the lumen caused by collagen homogenization with resulting distortion of glands profile, epithelial detachment, cell welding, nuclear lengthening, and nuclear chromatin homogenization. Fissures and cavitation effects may be visible on the cutting edge19. All morphological changes were found within 1.5 mm from the cutting edge.

In terms of safety, the main advantage of laparoscopic cholecystectomy by means of ultrasonically activated shears is low-risk dissection in the proximity of biliary structures.

The following important technical maneuvers may help to prevent bile duct injury : exposure of the Calot's triangle, identification and dissection of the gallbladder-cystic duct junction and CBD, and lateral traction of the gallbladder neck to avoid tenting of the bile duct. Also, inadequate application of metal clips may cause bile duct injury, and continuous instrument change may disturb the surgeon because he or she must look away from the operating field. Ultrasound dissection allows the surgeon to work in an almost bloodless field, which enhances discrimination of anatomical structures.

Bile duct lesions caused by coagulation-division with harmonic scissors may be wider than lesions after sharp division with standard scissors, but the bile duct wall is injured less than it is by monopolar electrocautery.

It was observed in the study that male :female ratio was 1:2.33 and 1:4 respectively in study and control group. This goes in accordance with the well known saying 'Fat, Fertile, Fair, Female, Forty'.

In study done by Tsimoyiannis et al20 (1998) duration of operating time was found to be statistically shorter (mean 37 mins vesus 45 mins; $p<0.05$) with ultrasonic dissection in laparoscopic cholecystectomy. In our study mean operation time for study and control group was 42.40 min and 44.90 min respectively ($p>0.05$). So operation time in our study was comparable to above study .Operating time is affected by

many variables (e.g., associated procedures,emergent procedures,difficult or heigh risk cases); therefore,a comparative analysis of overall results in the two subgroups did not show any relevant differences. however the no. of times the lens need to be cleaned in study group was significantely lower than the control group.This improves ease and maneuverbility of operation.

A review of the English literature published from 1992 to 2001 regarding the incidence of intraoperative Bile duct injury during laparoscopic cholecystectomy showed rates ranging from 0 to 1.28%1,2,3,4,21,22.

Considering the data from most of the targest cumulative series published in the past 10 years, we may assume that 0.60% rate of intraoperative Bile duct injury is a realistic value that mirrors the overall results of laparoscopic cholecystectomy worldwide. In our study one patient in control group had bile duct injury which was managed conservatively. No bile duct injury occurred in study group. None of the patient in both the groups developed wound infection.

Conversion rate reported in the literature is 1.2-8.2% in23,24 , in our study none of the patient was required to convert to open cholecystectomy.

In a study done by Tsimoyiannis et al20 (1998) mean length of hospital stay is statistically shorter with patient with ultrasonic dissection as compared to electrocautery (1.60 days in ultrasonic group and 1.90 days in electrocautery group) but in our study there was no significant difference (mean hospital stay-study group 2 days, control group2.13).

Two crucial aspects regarding the use of ultrasonically activated devices during laparoscopic cholecystectomies are the modality of application of ultrasonic scissors and the presence of severe adhesions. The surgeon must become familiar with the instrument and avoid maneuvers such as pointing the tip toward delicate structures or touching them with the active blade immediately after use. Cavitation could cause injuries to organs, vessels, and ducts ahead of the instrument's tip and the active blade (which becomes hot after use) could endanger the bile duct, the gallbladder, or the bowel. Correct application of the ultrasonically activated shears onto the cystic duct is mandatory to avoid subsequent leakage. However in our study group no such complication occurred.

Visual analogue scale (VAS) was used to measure postoperative pain in both the groups. Postoperative analgesia used was same in both the groups. Postoperative pain scores studied by Cengiz et al trial 25 (2005) (mean 1.50 in ultrasonic group and 2.60 in electrocautery group) were statistically lower with ultrasonic dissection. In our study mean pain on VAS was 3.88 and 3.98 respectively in study and control group. So we see that there is no significant difference in postoperative pain in both the groups.

In our study drain was placed in all the patients of both the groups. Mean drainage was 46.83 ml and 48.16 ml. in study and control group respectively. This shows there was no significant difference in both the groups. Ultrasound abdomen was done in all the patients in postoperative period to see any collection which also did not show any significant collection in both the groups.

As reported by Cuschierei13, 26 (1999), the temperature of the active blade after extensive use is probably higher than reported in initial studies and there may be risk of thermal injury by instrument misuse. Also, it may be argued that delayed biliary complications can occur ever after laparoscopic cholecystectomy by means of ultrasonically activated shears.

Nevertheless, at follow-up none of out patients suffered from postoperative biliary injury as determined by ultrasound scan.

In addition to its safety, ultrasonically activated scissors enhance the overall ergonomics of surgery by allowing the surgeon to work with both hands while focusing on the operating field throughout the operation without continuously changing instruments. Repeated instrument changes are typical of laparoscopic cholecystectomy, in which dissector, scissor, and clip applier are all needed to accomplish the operation. This may lead to either unsafe maneuvers performed without optic guidance or frequent change of laparoscope direction to follow instrument insertion.

The main disadvantage of ultrasonic dissection is instrument cost, which is particularly true if the surgical unit is equipped with reusable instruments. Nevertheless, some authors believe that compared with combined cost of using multiple disposable instruments (scissors, a clipper, an electrocautery hook, and a grasper), the Harmonic scalpel may provide a cost-effective option16.

In a cost analysis by Westervelt27 (2004) the cost in an American hospital of a disposable LCS Harmonic scalpel blade tip is $330.00. This is compared with the combined cost of a disposable electrocautery shears and a clipper, which is $350.00.

In Europe, Huscher et al19 (1999) estimated the cost for a disposable LCS Harmonic scalpel to be lower compared with the combined cost for one scissors and one clipper (346.03 Euro Vs. 397.67 Euro).

In our study total cost of operation was Rs 9200 in study group and Rs. 5550 in control group. This difference in cost was because clips were not used in study group. One harmonic scalpel was used for 30 patients which costed about Rs 27000 i.e. Rs 900 per patient. Cost of liga clip used in control group was about Rs 550. So we find significant difference of cost was found between both the groups.

However, the cost issue is relevant only on the assumption that disposable technology is used for monopolar electrocautery. By knowing that both ultrasonic and monopolar electrosurgery are now reusable instruments, making cost comparisons would be more difficult.

SUMMARY & CONCLUSION

In our prospective study "A study of clipless Laparoscopie cholecystectomy using Harmonic scalpel V/s traditional clip application in patients with gall stone disease" 60 Patients were included who were randomized in two groups of 30 patients each in study group and control group respectively. One group underwent traditional laparoscopic cholecystectomy using clips and dissection was done by Maryland dissector, whereas other group which underwent clipless laparoscopic cholecystectomy using harmonic scalpel and dissected with the harmonic ACE shear.

1. There were 21 (70%) females and 9(30%) males in group 1 (study group and 24 females (80%) and 6 males (20%) in group 2 (control group).
2. The age range for group 1 (study group) was 20-60 years (mean 37.90 yrs), and that for group 2 (control group) was 20-70 years (mean 39.50 yrs).
3. Post operative pain was measured with visual analogue scale (VAS) graded between 1-10 according to the patient's perception. Mean post operative pain in study group was 3.88 (range 1 to 8) and in control group was 3.98 (range 1 to 7). On statistical analysis no significant difference was found in both these group.
4. Mean operative time in study group was 42.40 minutes (range 28 to 60 mins) and in control group was 44.90 minutes (range 30 to 68 mins). On Statistical analysis no significant difference was found in operative time of both the groups.
5. Mean drainage in study group was 46.83 ml (range 25 to 80 ml) and in control group was 48.16 ml (range 30 to 70 ml). On Statistical analysis no significant difference was found in drainage of both the groups.
6. Mean duration no. of times lens cleaned during surgery in study group was 1.43 and in control group was 2.57. On Statistical analysis significant difference was found in both these groups.
7. In our study cases none of the patient had bile duct injury. In control group there was single patient who had minor bile duct injury which was managed conservatively.
8. Mean duration of hospital stay in study group was 2 days (range 1.5 to 3 days) in control group was 2.13 days (range 1.5 to 3.5 days). On Statistical analysis no significant difference was found in both these groups.
9. Harmonic shear was used in study group that costed Rs.27000 (Rs 900 per patient). In control group liga clip of 300 and 400 sizes were brought by the patient which costed about Rs 550 per patient. So we found that there was significant difference of cost in both the groups.

The use of harmonic scalpel eases the dissection maneuvers and avoids the use of clips to seal the cystic duct and artery. The harmonic scalpel is a safe, efficient and practical instument to use during

laparoscopic cholecystectomies. No significant difference was found in our study regarding operative time, post operative pain, biliary complication, hospital stay and post operative drainage. However no. of times camera lens cleaned during surgery was significantly lower in patient undergoing clipless laparoscopic cholecystectomy. This improves ease and maneuversbility of operation.

Hence on the basis of our study we conclude that use of harmonic scalpel for dissection, isolation, sealing and cutting of cystic duct and artery is safe, effective, and without any complication. We recommend use of harmonic ACE for laparoscopic cholecystectomy especially when cystic duct diameter is less than 6 mm.

REFERENCES

1. Calvete J, Sabeter L, Camps B, Verdu A, Gomez-Portilla A, Martin J, Torrico MA, Flor B, Cassinello N, Liedo S (2000) Bile duct injury during laparoscopic cholecystectomy : myth or reality of the learning curve? Surg Endosc 14:605-61175.
2. Dexter SP, Martin IG, Marton J, McMahon MJ (1997) Long operation and the risk of complications from laparoscopic cholecystectomy. Br J Surg 84:464-466.
3. Hjelmqvist B (2000) Complications of laparoscopic cholecystectomy as recorded in the Swedish laparoscopy registry. Eur J Surg Suppl 585:18-21.
4. McMahon AJ, Fullarton G, Baxter JN, O'Dwyer PJ(1995) Bile duct injury and bile leakage in laparoscopic cholecystectomy. Br J Surg 82:307-313.
5. Amann K, Kiesenebner J, Gadenstatter M, Mathis G, Stoss F (2000) Embolism of a metallic clip:an unusual complication following laparoscopic cholecystectomy. Dig Surg 17:542-544.
6. Hanazaki K, lagarashi J, Sodeyama H, Matsuda Y (1999) Bile leakage resulting from clip displacement of the cystic duct stump : a potential pitfall of laparoscopic cholecystectomy. Surg Endosc 13:168-171.
7. Labuski MR, Wise SW (1999) Recurrent abdominal abscess secondary to a dropped laparoscopic clip : CT imaging. Abdom Imaging 24:191-192.
8. Nelson TM, Nakashima M, Mulvihill SJ (1992) How secure are laparoscopically placed clips? Arch Surg 127:718-720.
9. Reis LD (2000) Surgical Clips incorporated into a duodenal ulcer : a rare complication after elective laparoscopic cholecystectomy. Endoscopy 32:S3.
10. Power C, Maguire D, McAnena OJ, Calleary J (2000) Use of the ultrasonic dissecting scalpel in laparoscopic cholecystectomy. Surg Endosc 14:1070-1073.
11. Sietses C, Eijsbouts AJ, von Blomberg BME, Cuesta MA (2001) Ultrasonic energy vs monopolar electrosurgery in laparoscopic cholecystectomy. Influence on the postoperative systemic immune response. Surg Endosc 15:69-71.
12. Tsimoyiannis EC, Jabarin M, Glantzounis G, Lekkas ET, Siakas P, Stefanaki-Nikou S (1998) Laparoscopic cholecystectomy using ultrasonically activated coagulating shears. Surg Laparosc Endosc 8:421-424.
13. Huscher CGS, Lirici MM, Di Paola M et al. laparoscopic cholecystectmy by ultrasonic dissection without cystic duct and artery ligation. Surg Endosc 2003;17:442-51.
14. Antonutti R, Fontes-Dislaire I, Rumeau JL. Mutter D, Fourtanier G. Experimental study of monopolar electrical and ultrasonic dissection. Ann Chir 2001;126(4):330-335.
15. Tucker RD, Voyles CR. Laparoscopic electrosurgical Complications and their prevention. AORN J. 1995;62:51-53, 55, 58-59 passim;quiz74-77.
16. Portella AO, Trindade MR, Dias LZ, Goldenberg S, Trindade EN. Monopolar electrosurgery on the extrahepatic bile ducts during laparoscopic cholecystectomy; an experimental controlled trial. Surg Laparosc Endosc Percutan Tect. 2009;19(3):213-216.
17. Tebala GD. Three port laparoscopic cholecystectomy by harmonic dissection with out cystic duct and artery clipping. Am J Surg 2006;191:718-720.
18. Emam TA, Cuschieri A. How safe is high power ultrasonic dissection? Ann Surg. 2003;237(2):186-191.
19. Huscher CGS, Lirici MM, Anastasi A, Sansonetti A, Amini M. Laparoscopic cholecystectomy by harmonic dessection. Surg Endosc 1999;13:1256-1257.
20. Tsimoyiannis EC, Jabarin M, Glantzounis G, Lekkas ET, Siakas P, Stefanaki-Nikou S (1998) Laparoscopic cholecystectomy using ultrasonically activated coagulating shears. Surg Laparosc Endosc 8:421-424.
21. Targarona EM, Marco C, Balague C, Rodriguez J, Cugat E, Hoyuela C, Veloso E, Trias M (1998) How, when, and why bile duct injury occurs. A comparison between open and laparoscopic cholecystectomy. Surg Endosc 12:322-326.
22. Wills VL, Jorgensen JO, Hunt DR (2000) Role of relaparoscopy in the management of minor bile leakage after laparoscopic cholecystectomy. Br J Surg 87:176-180.
23. Ayerdy J, Wiseman J, Gupta SK, Simon SC (2001) Training background as a factor in the conversion rate of laparoscopic cholecystectomy. Am Surg 67:780-785.
24. Thompson MH, Benger JR (2000) Cholecystectomy conversion and complications HPB Surg 11:373-378.
25. Cengiz Y, Janes A, Grehn A, Israelsson LA. Randomised trial of traditional dissection with electrocautery versus ultrasonic fundus - first dissection in patients undergoing laparoscopic cholecystectomy. Br J Surg. 2005; 92(7):810-813.
26. Gossot D, Buess G, Cuschieri A, Leporte E, Lirici M, Marvik R, M eijer D, Melzer A, Schurr MO (1999) Ultrasonic dissection for endoscopic surgery. Surg Endosc 13:412-417.
27. Westervelt J. Clipless cholecystectomy: Broadening the role of the Harmonic scalpel. JSLS. 2004;(8):283-285.