Research Paper

Volume : 4 | Issue : 1 | January 2015 • ISSN No 2277 - 8179

Comparative study of neoplastic lesions of gastrointestinal specimens received at tertiary care centre of Municipal corporation, Ahmedabed, Gujarat, India.

Medical Science

KEYWORDS : Neoplasms of GIT, GIST, Benign, Intermediate, Malignant.

Dr. Rupal P. Mehta	Associate Professor, Smt. NHL MMC
Dr. T.Y. Vijapura	Assistant Professor , Smt. SCL Hospital, Smt. NHL MMC
Dr. Alpa A. Shah	HOD and Professor, Smt.SCL Hospital, Smt.NHL MMC
Dr. Seema R. Patel	2nd Year Resident Smt.SCL Hospital
Dr. Keyur G. Patel	3rd year Resident Smt.SCL Hospital
Heli M. Kapadia	1st year resident
Vishal S.Patel	1st year resident

ABSTRACT

Surgical 61 gastrointestinal specimens are compared and analysed. We have done study of only whole gastrointestinal specimens from stomach to rectum (excluding all small biopsy).Out of 61 cases, 26 cases are neoplastic. Out of 26 neoplastic lesions, 23 lesions are malignant, 1 is intermediate and 2 are benign.

AIM:

- *Total 61 gastrointestinal specimens are compared and analysed.*
- *Our aim of study is to evaluate neoplastic lesions of GIT.*
- *Out of total 61 cases, 26 cases are neoplastic.*
- *Out of 26 neoplastic lesions, 23 lesions are malignant, 1 is intermediate and 2 are benign.*
- *To compare Benign, Intermediate and Malignant GIST. Out of 4 cases of GIST, 2 is Benign, 1 is Intermediate and 1 are Malignant GIST.*

INTRODUCTION:

- We have evaluated only whole gastrointestinal specimens received from stomach to rectum (excluding all small biopsies).
- Majority of gastric carcinomas are adenocarcinoma.
- WHO classification subdivides gastric carcinoma into four predominant patterns: papillary, tubular, mucinous and poorly cohesive carcinoma (including signet ring cell carcinoma and other variants).[11,12]
- WHO histology classification of adenocarcinoma of colon and rectum- Cribriform comedo, Medullary carcinoma, Micropapillary, Mucinous carcinoma, Serrated and signet cell carcinoma[16]
- Small intestinal Adenocarcinomas account for approximately 40%of small intestinal malignant tumors; however compared with colonic Adenocarcinoma they are uncommon. They are morphologically similar to adenocarcinomas elsewhere in the GI tract, but more often they are papillary.
- GI stromal tumors (GISTs) are mesenchymal neoplasms of the GI tract that formerly were often designated smooth muscle tumors. Two-thirds of GISTs arise from the stomach, and one-fourth arise from the small intestine; of the latter, one-third arise in the duodenum.[10]
- Macroscopic- Circumscribed, solitary, rounded, or ovoid masses. On cross section, often with areas of hemorrhage, necrosis, myxoid change, or cavitary degeneration. Both benign and malignant GISTs have similar macroscopic appearances.[10,14]
- Histologically- There are 8 different histological subtypes of GIST.4 spindle cell type and 4 epithelioid types. Epithelioid pattern is most common in the stomach and omentum. Spindle cell tumors composed of relatively uniform spindle cells in short fascicles or whorls. The cytoplasm is pale eosinophilic, and the nuclei are uniform and ovoid with vesicular chromatin. Approximately 50% of duodenal and small intestinal GISTs contain distinctive, round, oval, or elongated eosinophilic and PAS-positive aggregates of extracellular collagen referred to as skeinoid fibers.[5,10,13]
- Previously the term GIST was applied to mesenchymal tumors of all type. However at present time this diagnosis should be restricted to neoplasm arising from the interstitial cells of cajal (GI pacemaker cell).4 Cajal cell control the peristaltic action of the intestinal tract. Ultrastructurally, they show feature similar to GIST. By IHC normal cajal cell are positive for the KIT protooncogene, which encode for a transmemebrane tyrosine kinase receptor CD117. Approximately 95% of GIST have gain of function mutation of the KIT gene and are immunopositive for CD117. However, this marker is not unique for GIST.[1,2,14]
- There are 8 different histological subtypes of GIST.4 spindle cell type and 4 epithelioid types.[1,15]
- In our study 100% of GIST are of spindle cell type. Sex incidence is equal and the peak incidence is between fifth and eight decade of life.
- Out of total 61 cases, 4(6.56%) cases of GIST were studied, Out of 4 cases of GIST, 1is Benign, 1 is Intermediate and 2 are Malignant GIST.

MATERIAL AND METHODS:

- Retrospective study of 60 cases of gastrointestinal specimen which were received in pathology department at tertiary care centre of Municipal Corporation, Ahmadabad, Gujarat, India.
- Routine paraffin sections, H&E stain and PAS stain has been used.
- In diagnosing GIST, we used CD117 and CD 34.

OBSERVATION AND DISCUSSION

- We have done study of total 61 cases of whole gastrointestinal specimens, Out of 61 cases, 26 cases (42.62%) are neoplastic. Out of 26 neoplastic lesions, 23 (37.7%) lesions are malignant, 1 (3.27%) is intermediate and 2 (1.63%) are benign.
- Out of total 61 cases, 20 (33.33%) cases are of Adenocarcinoma of GIT.
- We have analaysed total 61 cases of gastrointestinal specimen which were received at pathology department.
- Out of 61 cases, 26 cases are neoplastic. Out of 26 neoplastic

lesions, 23 lesions are malignant, 1 is intermediate and 2 are benign. Out of 60 no of total gastrointestinal specimen neoplasm, only 4 (16%) cases of GIST are diagnosed.

- Out of 26 neoplastic lesions, 23 lesions are malignant, 1is intermediate and 2 are benign.
- Majority of cases are of Adenocarcinoma of gastrointestinal tract. Out of total 61 cases, 20 cases of Adenocarcinoma we have found and studied.
- 15-20% of colorectal Adenocarcinomas are Grade-1(low grade or well differentiated tumors), 60-70% are Grade-II (Moderately differentiated tumors), and 15-20% are Grade-III (Poorly differentiated tumors).
- In our study 75% 0f Adenocarcinomas are Moderately differentiated,15% are High grade and 10% are Poorly differentiated tumors.
- Out of 4 cases of GIST 1 are malignant, 2 is benign and 1 is intermediate type. Out of 60 cases, 25 cases are neoplastic.
- In our study 4 cases of GIST were studied. In our study 50% of cases are malignant, and 100% of cases are of spindle cell type. Sex ratio is equal in our study and 50% of GIST arises from stomach, which is most common site in GIST.
- In our study only 1 case of hemangioma we have found. It is vascular lesion of intestinal tract. Hemangioma unassociated with systemic syndrome may be classified on the basis of the predominant vessel type as capillary, cavernous, venous, arteriovenous or mixed type.
- In our study 1 case of basaloid carcinoma is also found. It is subtype of squamous cell carcinoma of rectum.
- We didn't have received any specimen of Lymphomas, Pure Squamous cell carcinoma or SCC.

Table no 1: Total no of GI specimen Vs GI Neoplasm.

Total no of cases of GIT	Neoplastic lesions	Non Neoplastic lesions
61	26	35

Table no 2: No of cases of GI Neoplasm

GIT neoplasm	Adenocarcinoma	GIST	Hemangioma	basaloid carcinoma
26	20	4	1	1

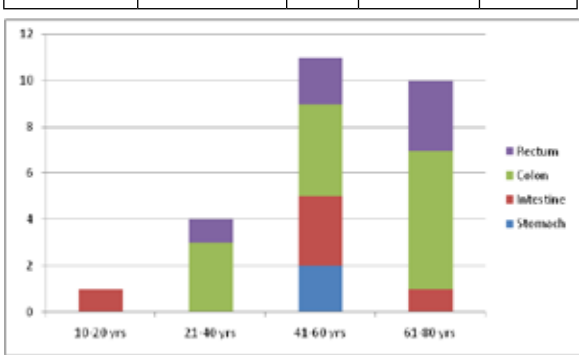

Above chart showing relation between age of patient and site of gastrointestinal neoplasm.

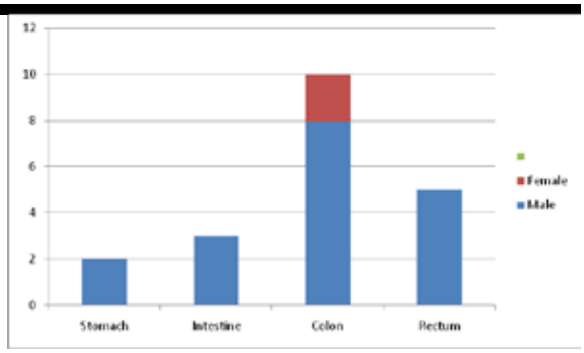

Above chart showing no of cases of male and female in gastrointestinal neoplasm.

CONCLUSION:

- In our study, we have evaluated mainly 61 GI specimens excluding small biopsies.
- Out of 26 neoplastic lesions, 23 lesions are malignant, 1 is intermediate and 2 are benign.
- Male Female Ratio 1:1.
- Majority of gastrointestinal neoplasm occurs between 40-60 years of age.
- Out of total 61 cases, 20 cases of Adenocarcinoma.
- Out of 4 cases of GIST 1 are malignant, 2 is benign and 1 is intermediate.

REFERENCE

1. Sternberg,s diagnostic surgical pathology, fifth edition. Chapter 32,1305-1311. | 2. Sircar K, Hewlett Brownish, Huitzinga JD, et al. Interstitial cells of cajal as precursor of gastrointestinal stromal tumors. Am J Surg Patho l1 999;377-389. | 3. Miettinen M, Sobin LH, Lasota J. gastrointestinal stromal tumors: review on morphology, molecular pathology, prognosis and differential diagnosis. Arch Pathol Lab Med2006;130:1466-1478. | 4. Juan Rosai, Akerman's Surgical Pathology. Ninth Edition Chap 11,638-643. | 5. Heinrich MC, Rubin BP, Longely B, Fletcher JA. Biology and genetic aspect of gastrointestinal stromal tumors : Kit activation and cytogenetic alteration. Hum Pathol 2002,33:484-495. | 6. Hurlimann J, Gardiol D. gastrointestinal stromal tumors.An immunohistochemical study of 165 cases. Histopathology 1991, 19:311-320. | 7. Suster S, Fletcher C. gastrointestinal stromal tumors with prominent signet ring features. Mod Pathol 1996;9:609-613. | 8. Greenson JK. gastrointestinal stromal tumors and other mesenchymal lesions of the gut. Mod Pathol 2003,16:366-375. | 9. Corless CL, McGreevey l, Haley A, Town A, Heinrich MC. KIT mutation are common in incidental gastrointestinal stromal tumors one centimetre or less in size.AM J Pathol 2002,160:1567-1572. | 10. Sternberg's Diagnostic Surgical Pathology, 5th ed. 2010, Pg-1419 | 11. Bosman F T, Carneiro F, Hruban R H et al. 2010 World Health Organization classification of tumours. Classification of tumours of the digestive system. IARC Press, Lyon, France | 12. Fletcher 4th 2013 Diagnostic Histopathology of Tumors Chapter - 8 Tumors of the Esophagus and Stomach. Page- 398 | 13. Robbins & Cotran Pathologic Basis of Disease - 8th Ed p- 784 | 14. Rosia and Ackerman's Surgical Pathology 10th ed, p- 688 | 15. Fletcher 4th 2013 Diagnostic Histopathology of Tumors Chapter - 8 Tumors of the Esophagus and Stomach. Page- 399 | 16. Washington Manual of Surgical Pathology, Second edition, Section –III: GI Tract,p-234 |