Research Paper

Volume : 4 | Issue : 1 | January 2015 • ISSN No 2277 - 8179

Comparison of transepithelial corneal collagen crosslinking with epithelium-off crosslinking in progressive keratoconus.

Medical Science

KEYWORDS : Corneal collagen crosslinking, Transepithelial, keratoconus,

Dr.Nikhil Rupareliya	3rd Year M.S.Ophthalmology; M&J Institute of Ophthalmology; Civil Hospital;Ahmedabad
Dr.Palak Shah	3rd Year M.S.Ophthalmology;M&J Institute of Ophthalmology;Civil Hospital;Ahmedabad
Dr. Nilam Chaudhary	3rd Year M.S.Ophthalmology;M&J Institute of Ophthalmology;Civil Hospital;Ahmedabad
Dr. Rupal Bhatt	MS, assistant professor ophthalmology; M&J Institute of Ophthalmology;Civil Hospital;Ahmedabad

ABSTRACT

To evaluate the safety and efficacy of transepithelial corneal collagen cross-linking(TE-CXL) as compared to epithelium-off crosslinking(epi-off CXL) in progressive keratoconus.Prospective study involving 20 patients with 3 months follow-up was undertaken.Pre and post-operative measurements of patient comfort,BCVA,refraction,corneal haze,keratometry,topography and specular microscopy were compared.There was no statistical significant difference in terms of BCVA,refraction,corneal thickness,keratometry values,specular microscopy counts between the two groups at 3 month follow-up.Statistically significant difference was noted in terms of patient comfort and corneal haze;TE-CXL group having better patient comfort and less corneal haze.So both the techniques are safe and effective;TE-CXL is better tolerated by patients.

Introduction:
Corneal collagen cross-linking(CXL) is a unique technique for the treatment of keratoconus and ectasia that was introduced in the late 1990s. The procedure involves loading riboflavin into the corneal stroma and then exposing the cornea to ultraviolet A (UVA) light. The riboflavin combined with UVA light strengthens the cornea by cross-linking it, which halts the progression of keratoconus.The conventional technique involves partial or complete removal of the central epithelium followed by the topical administration of riboflavin 0.1% solution to achieve intrastromal penetration. Now a days some surgeons are leaving the epithelium intact or performing"Epi-on" or trans-epithelial CXL. So the aim of this study is to evaluate the safety and efficacy of transepithelial CXL as compared to the conventional Epi-off technique.

Literature review:
Among surgeons familiar with the procedure of corneal collagen crosslinking its popularity is rising rapidly because of its positive safety profile and its unique efficacy in stopping progressive vision loss by addressing the root cause of ectasia: pathological corneal weakness. The use of corneal collagen cross-linking (CXL) to arrest progressive keratoconus was first introduced by Wollensak, Spoerl, and Seiler in 2003. In their initial description of the procedure, they removed the epithelium (epi-off) prior to administering riboflavin.These investigators have the most experience with the procedure, have experimented

with different ways of preparing the cornea prior to the cross-linking step, and they have conducted many studies demonstrating its safety and efficacy.

Experiments with Epi-on:
It is tempting to wish to perform a procedure in which

the epithelium is retained for several compelling reasons:
there is less postoperative pain, there is less risk of infection, and patients can return more quickly to wearing rigid contact lenses.

The epi-on technique was originally described by Boxer Wachler in 2004 and then by Pinelli. In some cases, the epi-on procedure can take up to 30 to 50 minutes longer than epi-off CXL, because the surgeon must ensure that the corneal stroma has properly absorbed the riboflavin. The reported rates of stromal and corneal haze after epi-off CXL have ranged from 7% to 90%.4-7 Almost no significant haze has been reported to date with the epi-on technique.

Methods: 20 eyes of 20 patient were randomly allocated to group 1 (10 patients)-Transepithelial CXL and group 2 (10 patients)Epi Off CXL.

Following parameters were measured in both the groups Pre and postoperatively:
-Patient comfort
-UCVA
-BCVA
-Refraction & Keratometry
-Slit lamp biomicroscopy
-Corneal topography
-Specular microscopy

Follow up was done on post-op 1st , 3rd day,1ST week, 1 month & 3 month.

Inclusion Criteria: 20-40 years of age,Progressive keratoconus (increase in cylinder 1D or more over a year),corneal thickness >400 microns.

Exclusion Criteria: Corneal scar,corneal thickness<400 microns,Non progressive, Associated cornel pathology,history of recurrent erosions,Pregnancy.

Results & Discussion: BCVA improved by about 1 line in all patients by both methods. Improvement was same in both group of patients. Though there was initial fall in BCVA at the end of 1st week post-op. There was increase in the least corneal thickness after surgery (438.2 microns before surgery versus 451.4 microns 3 months after surgery) but statistically the difference was not significant (P=0.75) and the difference between both groups was also not significant.

Changes in keratometric readings were statistically not significant, and the difference between both groups was also not significant

BCVA

	Mean best corrected visual acuity	± SD
PRE-OP GROUP 1 GROUP 2	 0.39 0.33	 ±0.14 ±0.09
1 WEEK POST OP GROUP 1 GROUP 2	 0.37 0.34	 ±0.12 ±0.10
1 MONTH POST OP GROUP 1 GROUP 2	 0.48 0.42	 ±0.11 ±0.12
3 MONTH POST OP GROUP 1 GROUP 2	 0.65 0.58	 ±0.65 ±0.58

Mean Spherical Error Of Refraction

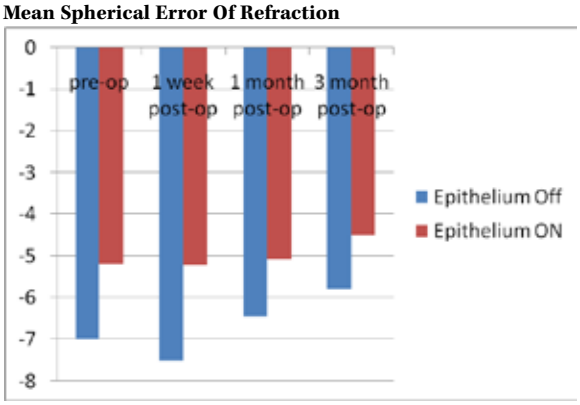

Mean Cylindrical Error Of Refraction

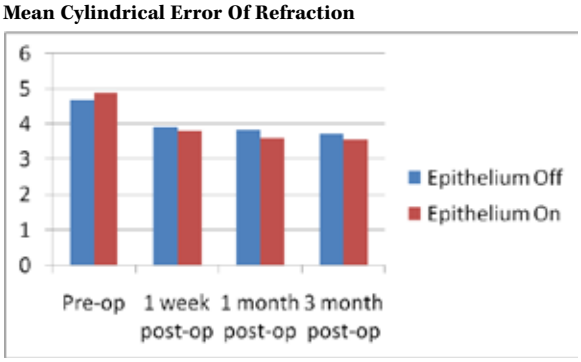

Keratometric Changes

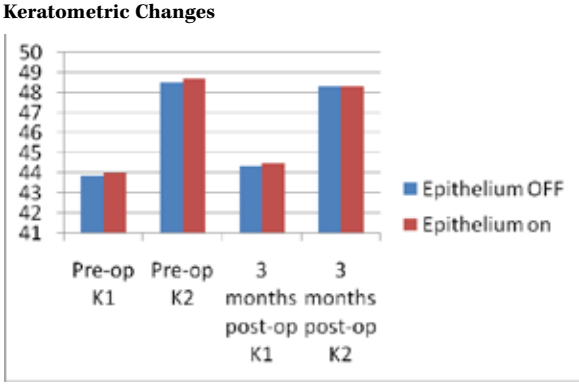

Mean Thinnest Point

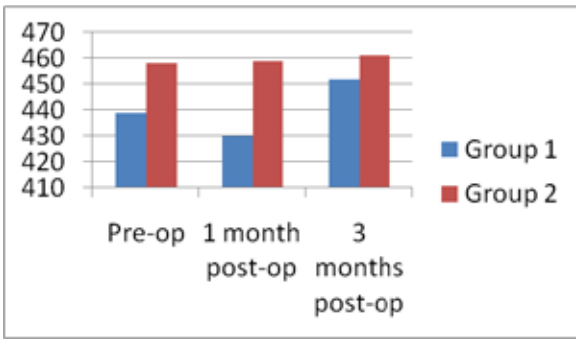

Specular Endothelial Cell Count

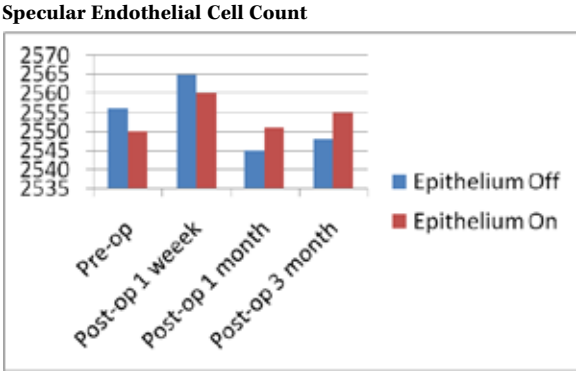

Epithelial Haze-1 Week Post-op

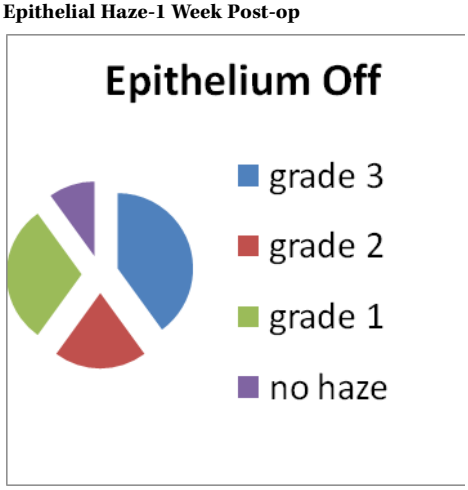

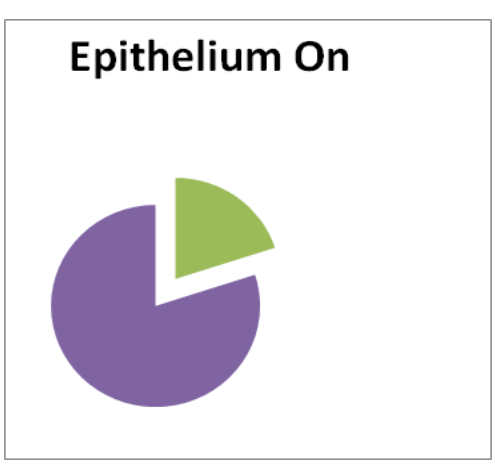

Volume : 4 | Issue : 1 | January 2015 • ISSN No 2277 - 8179

EPITHELIAL HAZE: 1 MONTH POST OP

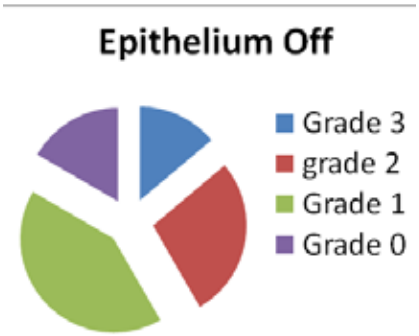



EPITHELIAL HAZE: 3 MONTH POST OP

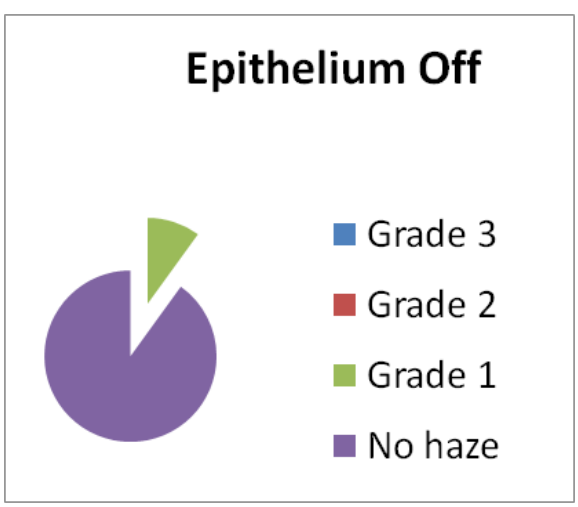

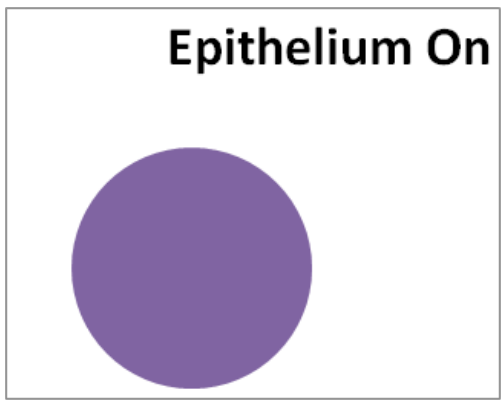

Pain, photophobia, lacrimation, redness, blurring

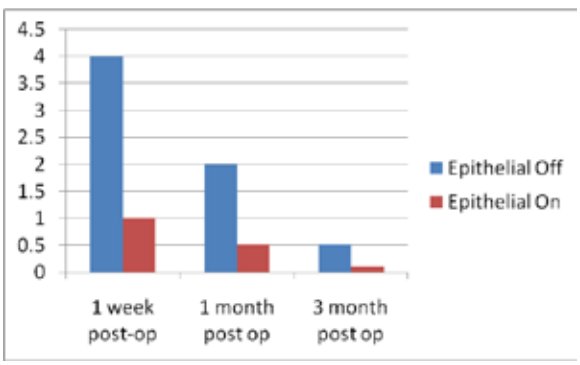

Conclusion:

Both epithelium on and off techniques of corneal collagen cross linking are safe and effective in stabilization of mild to moderate degree of keratoconus with regard to BCVA,refraction,keratometric readings ,least corneal thickness and endothelial count;however epi-on technique is easy to perform and better tolerated by patient with least postoperative corneal haze.

REFERENCE

1. The Management of Corneal Ectasia in the U.S.A. in 2012: Part Ia, Randy J. Epstein, MD,Professor, Dept. of Ophthalmology,Cornea Service | 2. The Egyptian Journal of Hospital Medicine (April 2013) Vol. 51 , Page 240– 252 | 3. Efficacy of Corneal Collagen Crosslinking with Riboflavin and Ultraviolet A in Progressive Keratoconus, Delhi Journel of Ophthalmology | 4. Epithelium On Versus,Epithelium Off,Surgeons discuss whether to remove the outer corneal layer during CXL,BY PARAG A. MAJMUDAR, MD; REBECCA MCQUAID, MSC; ARTHUR B. CUMMINGS, MB,CHB, FCS(SA), MMED(OPHTH), FRCS(EDIN); AND MICHAEL MROCHEN, PHD |