ORIGINAL RESEARCH PAPER

Volume-7 | Issue-6 | June-2018 | PRINT ISSN No 2277 - 8179

INTERNATIONAL JOURNAL OF SCIENTIFIC RESEARCH

COMPARITIVE STUDY OF TWO CROSS-SECTIONAL MODALITIES, ULTRASONOGRAPHY(USG) AND COMPUTED TOMOGRAPHY(CT) SCAN REGARDING THE ASSESSMENT OF ACUTE PANCREATITIS

Radiodiagnosis

Dr. R.Prabhakara Rao Assistant Professor, Department of Radio Diagnosis, Deccan College Of Medical Sciences, Hyderabad

Dr. S.Althaf Ali* Associate Professor, Department of Radio Diagnosis, Deccan College Of Medical Sciences, Hyderabad. *Corresponding Author

ABSTRACT

The objective of this study was to compare the two cross sectional modalities, USG and CT regarding the assessment of acute pancreatitis. All patients were first screened with USG and then underwent contrast-enhanced CT for the confirmation of diagnosis. Both USG and CT assessment was compared using several parameters including pancreatic enlargement, peripancreatic collection, pancreatic necrosis, ascites, pleural effusion and thickened retroperitoneal fascial planes. Chi square test was used to study the association between the comparable variables. P value and Odds ratio was calculated to study the level of significance and degree of correlation. This study emphasizes on the high value of USG as an initial tool in the screening and diagnosis of acute pancreatitis, however the severe forms of pancreatitis with pancreatic necrosis and thickened retroperitoneal fascial planes are better detected on CT.

KEYWORDS

Ultrasonography(USG), Computed Tomography(CT) Scan, Acute Pancreatitis, Screening.

INTRODUCTION

Acute pancreatitis is a life threatening condition with significant morbidity and mortality. Early assessment of severity of acute pancreatitis is of utmost importance in management of the patients of acute pancreatitis. Diagnosis of acute pancreatitis is made by combination of clinical presentation, laboratory investigations and imaging. Ultrasonography and computed tomography are the important diagnostic modalities for early diagnosis and staging of acute pancreatitis. Ultrasonography is usually the initial imaging modality employed. A frequent sonographic finding of acute pancreatitis is diffuse or focal enlargement of the gland. Sensitivity of USG in diagnosing severe acute pancreatitis is 89.6%, but specificity was as low as44% where as specificity of CT was 87.5%.However, Ultrasound has certain limitations in diagnosing and grading acute pancreatitis like the visualization of pancreas is often impaired because of overlying bowel gas, detection of intra pancreatic and retroperitoneal fluid collection correlates poorly with the extent of pancreatic necrosis and pancreas may appear completely normal in mild cases of acute pancreatitis. CT scan remains the most important modality for the diagnosis and imaging of acute pancreatitis. Its marked ability to detect early inflammatory changes as well as complications, in particular pancreatic necrosis, makes it an invaluable investigation. Complications of acute pancreatitis such as psuedocysts, abscess, necrosis, vascular thrombosis, psuedoaneurysms, and hemorrhage can also be recognized with CECT(Contrast Enhanced CT). Detection and quantification of severity of acute pancreatitis is necessary to improve medical care, lower mortality rates. An ideal imaging system should be able to detect pancreatic inflammation and necrosis early.

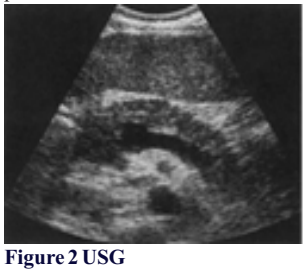

Figure 2 USG

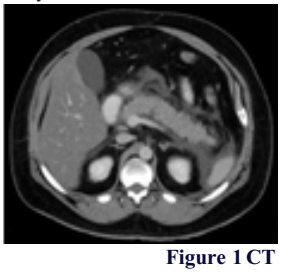

Figure 1 CT

PATIENTS AND METHODSFigure USG

Study design: This is a prospective cross-sectional study.

Approval: This study received approval from college ethical committee.

Setting: Owaisi Hospital, Hyderabd.

Participants: Sixty one patients admitted in Owaisi Hospital.

Study period : June 2015 – November 2016

OBSERVATIONS AND RESULTS

In our prospective study, a total of 61 patients were examined during the period 25th June 2015 to 5th November 2016. All the patients referred from the emergency department were first examined with ultrasound and then subjected to CT scan .Confirmation of the diagnosis is based on the CT findings.

The patients were divided according to Balthazar's grading (Grade A to E) and classified into mild (MCTSI 0-2), moderate (MCTSI 4-6) and serve (MCTSI 8-10) pancreatitis on the basis of Modified CT severity index (MCTSI).

SEX DISTRIBUTION

TABLE : 1

GENDER	No. OF PATIENTS
MALE	40
FEMALE	21

COMPARED PARAMETERS

Ultrasonography was used as a primary investigating modality for diagnosing acute pancreatitis. CT was used for the confirmation of diagnosis. Apart from acutely inflamed and enlarged pancreas, other generally associated findings such as peripancreatic fluid collections, pancreatic necrosis, retroperitoneal fascial thickening, ascites, pleural effusion, and gall stones were also assessed. Finally, the findings obtained on USG and CT were compared as under:

PANCREATIC ENLARGEMENT

TABLE : 3

MODALITY	MILD PANCREATITIS	MODERATE PANCREATITIS	SEVERE PANCREATITIS	TOTAL
USG	21	12	6	39
CT	24	14	7	45

Statistical test results:

Degree of freedom 1

Chi-square Value 1.376

P value 0.241

Odds ratio 1.587

Upper limit of 97% Confidence level 0.732

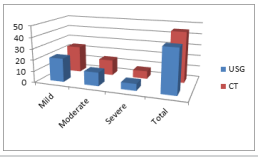

PERIPANCREATIC COLLECTIONS TABLE : 4

MODALITY	MILD PANCREATITIS	MODERATE PANCREATITIS	SEVERE PANCREATITIS	TOTAL
USG	3	2	5	10
CT	2	3	8	13

Statistical test results:
Degree of freedom1
Chi-square Value0.482
P value0.487
Odds ratio1.381
Upper limit of 97% confidence level0.554
Upper limit of 97% confidence level0.517

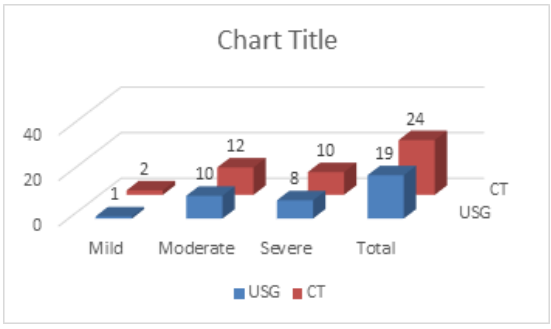

PANCREATIC NECROSIS
TABLE : 5

MODALITY	MILD PANCREATITIS	MODERATE PANCREATITIS	SEVERE PANCREATITIS	TOTAL
USG	1	3	4	8
CT	3	7	9	19

Statistical test results:
Degree of freedom1
Chi-square Value5.755
P value0.016
Odds ratio2.997
Upper limit of 97% confidence level1.194

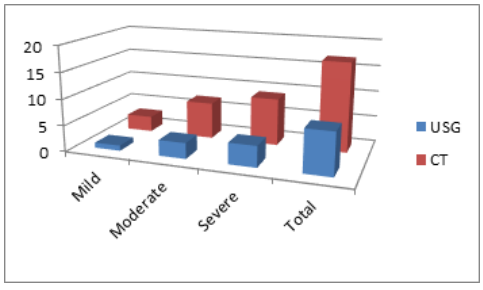

ASCITES
TABLE : 6

MODALITY	MILD PANCREATITIS	MODERATE PANCREATITIS	SEVERE PANCREATITIS	TOTAL
USG	4	5	5	14
CT	2	5	4	11

Statistical test results:
Degree of freedom1
Chi-square Value 0.453
P value0.501
Odds ratio0.739
Upper limit of 97% confidence level0.305

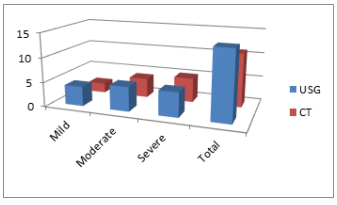

PLEURAL EFFUSION
TABLE : 7

MODALITY	MILD PANCREATITIS	MODERATE PANCREATITIS	SEVERE PANCREATITIS	TOTAL
USG	1	10	8	19
CT	2	12	10	24

Statistical test results:
Degree of freedom1
Chi-square Value0.035
P value0.852
Odds ratio1.072

THICKENED FASCIAL PLANES
TABLE : 8

MODALITY	MILD PANCREATITIS	MODERATE PANCREATITIS	SEVERE PANCREATITIS	TOTAL
USG	0	2	6	08
CT	5	9	11	25

Statistical test results:
Degree of freedom1
Chi-square Value12.005
P value0.001
Odds ratio4.601

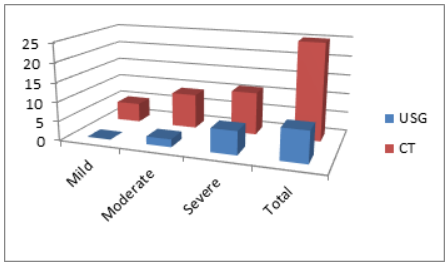

Upper limit of 97% confidence level1.86
On comparison with USG findings, pancreatic enlargement, necrosis, peripancreatic fluid collections and retroperitoneal facial plane thickening were observed in more number of cases on CT.
Pleural effusion was observed in almost similar number of cases both on USG and CT.
However, ascites was seen in slightly more number of patients on USG when compared with CT.

DISCUSSION

On statistical analysis done for association between compared parameters observed on USG to that detected on CT, no significant difference was observed between pancreatic enlargement, peripancreatic collections, ascites and pleural effusion, with each parameter having **p value greater than 0.05 and upper limit of 95% confidence interval less than 1**. However statically significant difference was observed for pancreatic necrosis and thickened retroperitoneal fascial planes with **p value less than 0.05 and upper limit of 95% confidence interval greater than 1** on comparing USG findings with CT.

Compared Parameters	CHI-SQUARE VALUE	P-VALUE	ODDS RATIO	UPPER LIMIT OF95%CONFIDENCE INTERVAL	STATISTICALSIGNIFICANCE
PANCREATIC ENLARGEMENT	1.376	0.241	1.587	0.732	NOT SIGNIFICANT
PERIPANCREATIC ENLARGEMENT	0.482	0.487	1.381	0.554	NOT SIGNIFICANT
NECROSIS	5.755	0.016	2.997	1.194	SIGNIFICANT

ASCITES	0.453	0.501	0.739	0.305	NOTSIGNIFICANT
PLEURAL EFFUSION	0.035	0.852	1.072	0.517	NOTSIGNIFICANT
FASCIAL THICKENING	12.005	0.001	4.601	1.867	SIGNIFICANT

This signifies that CT is significantly better than USG for the detection of pancreatic necrosis and retroperitoneal fascial thickening in acute pancreatitis. However, both modalities can equally contribute to the detection of pancreatic enlargement, peripancreatic collection, ascites and pleural effusion.

SUMMARY AND CONCLUSIONS

This study was done to assess the comparative role of two cross-sectional modalities, USG and CT in the evaluation of Acute Pancreatitis.

All the patients were first examined with ultrasound and then subjected to contrast-enhanced CT scan. Confirmation of the diagnosis was based on the CT findings.

The patients were divided according to Balthazar's grading (Grade A to E) and classified into mild (MCTSI 0-2), moderate (MCTSI 4-6) and severe (MCTSI 8-10) pancreatitis on the basis of modified CT severity compared and analysed.

Parameters taken for comparison were:

- Pancreatic enlargement
- Adjacent fluid collections
- Pancreatic necrosis
- Fascial plane thickening
- Pleural effusion
- Ascites

Data analysis showed that for both USG and CT, no significant difference was observed between pancreatic enlargement, peripancreatic collection, ascites and pleural effusion, with each parameter having p value greater than 0.05. However statistically significant difference was observed with p value less than 0.05 for pancreatic necrosis and thickened retroperitoneal fascial planes on comparing the USG findings with CT.

TO SUMMARISE,
our study on acute pancreatitis supported that USG is a very valuable initial tool in the screening and diagnosis of acute pancreatitis, however the severe forms of pancreatitis with pancreatic necrosis and thickened retroperitoneal fascial planes are better detected on CT as compared to USG.

TO CONCLUDE,
Ultrasonography is an important screening modality in patients with probable clinical diagnosis of acute pancreatitis with pancreatic enlargement being a commonly observed finding.

Findings like pancreatic necrosis, thickened retroperitoneal fascial planes and peripancreatic collections are less commonly observed on USG, but have good correlation with severe form of acute pancreatitis based on Balthazar's modified CT severity index.

CT is better in detecting necrosis, retroperitoneal fascial thickening and in assessing the severity of acute pancreatitis.

REFERENCES

1. Bradely EL III, A clinically based classification system for acute pancreatitis. Arch surgeon 1993; 128-586-590
2. Dharani Subramaniam. Etiology of pancreatitis in the United States. In Acute pancreatitis; Diagnosis and therapy. Newyork, raven; 1994: 234-239
3. Gill KA. Textbook of Abdominal Ultrasound. A Practitioner's Guide. P.163-164.
4. anuradha Soakar, Chad B. Rabinowitz, Dushyant V. Sahani. Radiolclin Nam..2007; 45;447-460
5. Brant WE, Helms C. Fundamentals of diagnostic Radiology. 3rd Edition. Philadelphia:Lippincott, Williams and Wilkins; 2007 p.376.
6. Chaya CT, Bhutani MS. Ultrasonography of the Pancreas-Endoscopic imaging. Abdom imaging. 2007 ; 32(2); 191-9
7. Gorelick FS alcohol and zymogen activation in the pancreatic acinar cell. Pancreas. 2003; 27; 305-10
8. Lee SP, Nicholls JF, Park HZ. Biliary sludge as a cause of acute pancreatitis. N Engl J Med. 1992; 326 :589-93
9. Parenti DM, Spineberg W, Kang P. Infectious causes of acute pancreatitis. Pancreas. 1996; 13:356-71
10. Finely JW. Respiratoru complications of acute pancreattits. Am Surg.1969; 35:591-98
11. Balthazar EJ. Staging of acute pancreatitis. Radiol clin North AM 2002; 40: 1199-209
12. Banks PA . A new classification system for acute pancreattis. Am J Gastro enterol. 1994;89(2):151-52
13. Modder U, Bayer D. Diagnostic Imaging of the Acute Abdomen clinic-radiologic approach. 1998; 202-10
14. Mortel KJ, Banks PA. Silverman SG. State of the art Imaging of Acute Pancreatits. JBR-BTR. 2003;86:193-208
15. Forsmark CE, Baillie J. AGA Institue Technical review on Acute Pancreatitis. Gastroenterology. 2007;132:2022-2044
16. Irie H, Honda H, Baba S, ET al. Auto immune pancreatitis; CT and MR charecteristics. AJR 1998;170:1323-1327
17. Beger HG, Rau B, Mayer J, Pralle U. Natural Course of Acute Pancreatitis. World J Surg 1997; 21:130:135