ORIGINAL RESEARCH PAPER

Volume-7 | Issue-9 | September-2018 | PRINT ISSN No 2277 - 8179

INTERNATIONAL JOURNAL OF SCIENTIFIC RESEARCH

COMPLICATIONS ASSOCIATED WITH POSTERIOR SUPERIOR ALVEOLAR NERVE BLOCK USING ARTICAINE AS A LOCAL ANESTHETIC AGENT

Dental Science

Mandeep sharma* PG Student KVG Dental College And Hospital Sullia *Corresponding Author

Sandeep sharma Registrar Government Medical College Jammu

Pooja Sharma Registrar Government Medical College Jammu

Sneha Kulkarni PG Student KVG Dental College And Hospital Sullia

ABSTRACT

BACKGROUND & OBJECTIVES Local anesthetics are frequently administered in dental field. Lignocaine is most commonly used local anesthetic solution for extracting tooth in oral surgery. The major source of drug-related complications in the dental office occur because of local anesthetics. Articaine contains a thiophene group, which increases its lipo-solubility. It has high diffusion properties so it can be used widely in the dentistry field. Posterior superior alveolar nerve block is commonly used in dentistry for extraction and other purposes. But due to the high diffusion properties its use in posterior superior alveolar nerve block is limited due to risk of complications. Objectives of the study was to evaluate the complications associated with the use of articaine in posterior alveolar nerve block.

METHODOLOGY: A randomized study was carried on 100 patients of age group 10-60 years who required procedure in posterior maxillary arch, visiting the Department of Oral and Maxillofacial surgery. They were included in the study after obtaining informed consent. Posterior superior alveolar nerve block of anesthetic solution was given randomly to 100 patients. Objective signs were checked after 2 minutes. Duration of anesthesia was measured. Patients receiving dental anesthesia were evaluated by questionnaire for risk factors, and complications associated with the administration of the local anesthetic.

RESULTS: The most frequently observed complications were dizziness, tachycardia, agitation, nausea, tremor which were transient in nature. 23% had at least one risk factor in their medical histories out of which 13.04% (3 patients) showed complications. Overall incidence of complications was also 4 %. Severe complications (seizure, bronchospasm) did not occurred in any case. No paresthesia was noted in nerve. No ocular complications were present in any of the case. No hematoma occurred following administration of posterior superior alveolar nerve block.

INTERPRETATION & CONCLUSION: No severe complications occurred with the use of articaine in PSA nerve block. The incidence of complications due to articaine as anesthetic agent in PSA nerve block can be reduced. Proper evaluation of patients should be done for risk factors with adequate medical history prior to dental treatment.

KEYWORDS

Anesthesia, Articaine, PSA (posterior superior alveolar nerve block).

INTRODUCTION-

Articaine is 4-methyl-3-[2-(propylamino)-propionamido]-2-thiophene-carboxylic acid, methyl ester hydrochloride. Classified as an amide, however, it possesses both amide and ester characteristics[1].It differs from the other amide local anesthetics because it contains a thiophene ring[2]. Its molecular mass is 284.37 g/mol and 320.836 g/mol (HCl)[3]. The thiophene ring allows greater lipid solubility, which facilitates diffusion across the lipid-rich nerve membrane to access target receptors. In addition, articaine contains an ester group, so that hydrolyzation occurs in the plasma by nonspecific cholinesterases, further metabolism, and excretion, primarily in the kidneys.[4]

Articaine hydrochloride was synthesized by Rusching et al in 1969 and first marketed in Germany in 1976[3]. The mechanism by which articaine blocks nerve conduction is similar to that of lidocaine, mepivacaine and prilocaine[5]. No differences in toxicity were noted between 4% articaine and lower concentrations[6-10]. The duration of soft tissue anesthesia produced by 4% articaine with a dose of 1.8 ml was reported as 4.3 to 5.3 hours for nerve block[11,12].

Posterior superior alveolar nerve block is commonly used in dentistry for extraction and other purposes. This injection technique delivers the local anesthetic agent on to the posterior surface of maxilla targeting posterior superior alveolar branch of maxillary nerve. Other important structures present in this space area include pterygoid venous plexus and posterior superior alveolar branch of maxillary artery[1]. Articaine hydrochloride due to the high diffusion properties, its use in posterior superior alveolar nerve block is limited due to risk of complications.

Objectives of the study was to evaluate the complications associated with the use of articaine in posterior alveolar nerve block.

AIM

- To evaluate the complications associated with posterior superior alveolar nerve block using articaine as local anesthetic agent.

OBJECTIVES

To evaluate incidence of side effects and complications most oftenly observed after PSA with articaine.

To evaluate complications that are to be expected in the presence of risk factors.

METHODOLOGY- A randomized study was carried on 100 patients of age group 10-60 years who required procedure in posterior maxillary arch, visiting the Department of Oral and Maxillofacial surgery. They were included in the study after obtaining informed consent.

Inclusion criteria: Patients who require procedures in posterior maxillary arch in the region of maxillary molars. Patients in the age group of 10-60 years.

EXCLUSION CRITERIA: Subjects with any previous history of complications associated with local anaesthetic administration. Presence of acute infection or swelling. Patients having sickle cell anemia diseases. Pregnant women and lactating mothers. Patients unable to give informed consent.

MATERIALS

1) SEPTANEST® (Articaine HCl. 4% with Epinephrine 1:100,000 Injection) manufactured by Septodont, France (Marketed by Septodont Healthcare India Pvt. Ltd., Maharsahtra)
2) Septoject sterile 27 gauge disposable needles manufactured by Septodont, France (Marketed by Septodont Healthcare India Pvt. Ltd., Delhi)

METHOD OF COLLECTION OF DATA-

Proper history of the patients was taken. Risk factors (eg, cardiovascular, pulmonary, hepatic, metabolic, allergic, CNS disease, pregnancy) were evaluated. After obtaining the informed consent each patient was randomly allocated to the study. Local anaesthesia (LA) 4% articaine with 1:100,000 adrenaline was administered using posterior superior alveolar nerve block. PSA nerve block was administered by using a 25mm needle and LA was administered distal to first molar with needle directed upward, backward and inward in 45 degree angulation. The depth of penetration was about half the length

of the needle, aspiration was done which yielded negative aspiration and LA was injected. Complications (eg, nausea, vomiting, erythema, urticaria, itching, mucosal edema, anaphylactic shock, confusion, disorientation, agitation, dizziness, trembling, headache, syncope, seizure, hypotension, hypertension, bradycardia, tachycardia, arrhythmia, cardiac arrest, pectoral angina, local bleeding, dyspnea, asthma attack, bronchospasm) were noted if present. Patients were monitored till the anesthetic effect wears off.

RESULTS

Out of 100 patients 46 patients were female and 54 patients were male. The average age of the patients was 43.3 ± 14.8yr. The most frequently observed complications were dizziness, tachycardia, agitation, nausea, tremors which were transient in nature. 23% had at least one risk factor in their medical history out of which 13.04% (3 patients) showed complications. Out of 23% patients 17% had one and 6% had more than one risk factors in their medical history. Patient may exhibit more than one risk factor. Most often encountered patients were having cardiovascular diseases (18%), metabolic diseases (4%), and pulmonary diseases (5%). Also, 20% of all patients were on a daily medication, with 9 % taking more than two drugs daily. Most commonly used medications were Pi blocker/ACE inhibitors/Ca-channel blockers, thyroid/antithyroid drugs, cardiovascular drugs, antihypertensive drugs, NSAIDS, oral contraceptives, antidiabetic drugs etc.

Overall incidence of complications was 4% which included syncope in two cases and tachycardia and agitation in two cases. Severe complications (seizures, bronchospasm) did not occur in any case. No paresthesia was noted in the nerve. No hematoma occurred following administration of posterior superior alveolar nerve block.

Patients having risk factors (23 patients) showed a higher risk of complications. Out of 23 patients, 3 patients showed complications. Two patients (8.69%) had tachycardia and one (4.3%) had syncope. Chi square test was used and p value < 0.05. These results showed a significant difference to the patients having no complications. All three patients had cardiovascular disease whereas one patient was having superimposed pulmonary disease and the other one with thyroid dysfunction.

No ocular complications were present in any of the case.

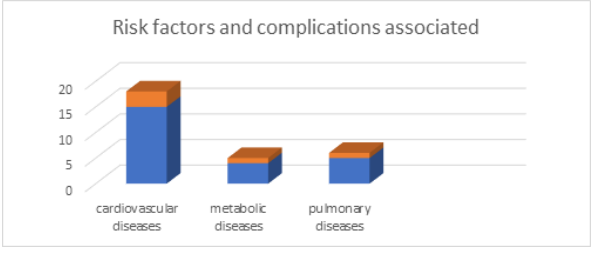

Graph 1 – Medically compromised patients with complications associated with PSA. Patients may overlap. Blue colour- without complications, brown colour – with complication.

DISCUSSION:

Pain control during any operative or surgical procedure is one of the most important factors for successful treatment. There are various methods used to control pain among which use of local anaesthetic agents is the most commonly employed technique in dental practice[5].

Articaine being an amide-type local anesthetics contains a carboxylic ester group, thus is inactivated in the liver and by hydrolyzation in the tissue and the blood. Articaine is therefore cleared more quickly from the body. Hydrolyzation is very fast and starts immediately after injection and about 85 to 90 % of administered articaine is inactivated in this way. Main metabolic product is articainic acid which is non-toxic and inactive as local anesthetic[13].

One of the most controversial aspects of articaine administration is its potential to cause paresthesia. It is known to cause paresthesia after inferior alveolar nerve block[14,15]. This adverse effect is attributed to the higher concentration of articaine (4%) in comparison with other local anesthetics (e.g., 2% lidocaine in association with epinephrine). In Germany, a 2% formulation in association with 1:200,000 epinephrine has recently become available for dental use, which proved as effective as 4% concentration in teeth extractions with infiltration anesthesia but causes less paresthesia[16].Others claim that paresthesia is chiefly seen in the lingual nerve, this might be due to direct trauma from the needle or over-reporting of problems which is natural when a new drug is introduced to practice[17]. Malamed stated that "there is absolutely no scientific evidence to demonstrate there is a greater risk of paresthesia associated with the administration of a 4% local anesthetic"[18]. Malamed et al conducted a study and found that 4% Articaine with 1:1,00,000 epinephrine is a safe and effective local anesthetic for use in pediatric dentistry[19].

In our study the frequency of complications was higher in cases which were medically compromised. Complications associated with articaine are comparable to those associated with lidocaine which was in accordance to the study conducted by Katyal et al[20] which found that there is no difference in post-injection adverse events between articaine and lignocaine. However, articaine injection resulted in a slightly higher score for pain at the injection site after anesthetic reversal compared to lignocaine as measured by a visual analogue scale. The clinical impact of these higher post-injection pain scores compared to lignocaine is negligible considering that both drugs appear to have similar adverse effect profiles.

No patient in our study shows ocular complications like diplopia, mydriasis, palpebral ptosis, and abduction difficulties. In contrary Peñarrocha-Diago M et al[21] published a study with 14 cases of ophthalmologic complications after intraoral anesthesia of the posterior superior alveolar nerve using articaine whereas review conducted by Ravi et al[22] states that the commonest technique causing ocular complications was the inferior alveolar nerve block (54.2%), followed by the posterior superior alveolar nerve block (30%). The commonest anaesthetic drug used was lignocaine (68%), followed by articaine (18.5%). Few cases utilized mepivacaine (5%), procaine (5.8%), prilocaine (1.6%) and butethamine (0.8%) in their study. Among these 90.7% of the agents contained a vasoconstrictor.

Lidocaine is most commonly used local anesthetic for most dental procedures but articaine can be considered as a good substitute. Further studies with larger sample size are further needed to evaluate the safety of articaine in various dental procedures.

REFERENCES

1. Malamed SF. Handbook of local anaesthesia. 4th ed. St. Louis, Mosby; 1997.
2. Oertel R, Rahn R, Kirch W. Clinical pharmacokinetics of articaine. ClinPharmacokinet 1997;33:417-25.
3. ThakareA ,Bhate K, Kathariya R. Comparison of 4% articaine and 0.5% bupivacaine anesthetic efficacy in orthodontic extractions: Prospective, randomized crossover study. ActaAnaesthesiologicaTaiwanica 52 (2014) 59e63.
4. Malamed SF, Gagnon S, Leblanc D. Efficacy of articaine: a new amide local anesthetic. J Am Dent Assoc 2000;131:635-642.
5. Malamed SF, Gagnon S, Leblanc D. Articaine hydrochloride: the study of safety of a new amide local anesthetic. J Am Dent Assc. 2001 ; 132: 177-185.
6. Winther JE, Nathalang B: Effectivity of a new local analgesic Hoe 40 045. Scand J Dent Res 80:272-78, 1972.
7. Winther JE, Patirupanusara B: Evaluation of carticaine–a new local analgesic. Int J Oral Surg3:422-27, 1974.
8. Raab WHM, Muller R, Muller HF: Comparative studies on the anesthetic efficiency of 2% and 4% articaine. Quintessence 41(7):1208-16, 1990.
9. Ruprecht S, Knoll-Kohler E: Comparative study of equimolar solutions of lidocaine and articaine for anesthesia. A randomized, double-blind cross-over study. Schweiz MonatsschrZahnmed101(10):1286-90, 1991.
10. Raab WHM, Reithmayer K, Muller HF: A process for testing anesthetics. DtschZahnarztl Z 45(10):629-32, 1990.
11. Lemay H, Albert G, HJlie P, Dufour L, Gagnon P, Payant L, LalibertJ R: L'articaine en dentisterie operatoire conventionnelle. Le Chirugien Dentiste de Frsnce.281(92):39-43, 1985.
12. Cowan A: Clinical assessment of a new local anesthetic agent–carticaine. Oral Surg 43(2):174-80, 1977.
13. Claffey E, Reader A, Nusstein J, Beck M, Weaver J. Anesthetic efficacy of articaine for inferior alveolar nerve blocks in patients with irreversible pulpitis. J Endod 2004;30(8):568-571.
14. Pogrel MA, Pogrel MA. Permanent nerve damage from inferior alveolar nerve blocks—an update to include articaine. Journal - California Dental Association 2007:35.
15. Garisto G, Andrew S. Gaffen, Herenia P. Lawrence, Howard C. Tenenbaum, Daniel A. Haas. Occurrence of paresthesia after dental local anesthetic administration in the United States. JADA 2010;141(7):836-844.
16. Wahl MJ, Schmitt MM, Overton DA, Gordon MK. Injection pain of bupivacaine with epinephrine vs. prilocaine plain.J Am Dent Assoc. 2002 Dec;133(12):1652-6.
17. Hintze A, Paessler L. Comparative investigations on the efficacy of articaine 4% (epinephrine 1:200,000) and articaine 2% (epinephrine 1:200,000) in local infiltration anaesthesia in dentistry— a randomised double-blind study. Clin Oral Investig 2006;10(2):145-150.
18. Malamed SF. Nerve injury caused by mandibular block analgesia. Int J Oral Maxillofac Surg. 2006a;35(9):876-7;
19. Malamed SF, Gagnon S, Leblanc D. A comparison between articaine HCl and lidocaine HCl in pediatric dental patients. Pediatr Dent 2000;22:307-11.
20. Katyal V. The efficacy and safety of articaine versus lignocaine in dental treatments: a meta-analysis. J Dent. 2010; 38(4):307-17.
21. Peñarrocha-Diago M, Sanchis-Bielsa JM. Ophthalmologic complications after intraoral local anesthesia with articaine. Oral Surg Oral Med Oral Pathol Oral Radiol Endod. 2000 Jul;90(1):21-4.
22. Ravi P, Gopi G, Shanmugasundaram S, Raja KK. V Ocular complications with dental local anaesthesia - a systematic review of literature and case report. S. Afr. dent. j. 2015;70(8):354-357.