VOLUME-6 | ISSUE-4 | APRIL - 2017 • ISSN No 2277 - 8179 | IF : 4.176 | IC Value : 78.46

Conservative management Of Recurrent Odontogenic Myxoma- A Case Report.

Dental Science

KEYWORDS: Odontogenic Myxoma, tumor, multilocular.

Dr Samit Jain	BDS, MDS, Associate Professor, Uttranchal Dental & Medical Research centre, Dehradun
Dr Sarika Jain	MS Gen Surgeon, Senior Resident, Government Medical college, Saharanpur.
Dr. Sankalp Verma	MDS ; SRI SAI HOSPITAL Moradabad, India

ABSTRACT

Odontogenic myxoma is a non-encapsulated benign tumor of the jaws that rarely occurs. It derives from the dental mesenchyme or periodontal ligament. It has been reported to be the second commonest odontogenic tumour in many countries. Many studies showed that small unilocular lesions should be successfully treated with enucleation and curettage followed by chemical bone cautery while Multilocular tumors exhibit a 25% recurrence rate and, therefore, must be treated more aggressively. Here a case of recurrent multilocular Odontogenic Myxoma was report which was treated conservatively.

Introduction: Odontogenic myxoma is a rare benign tumor of the jaws which, in most cases, grows slowly and asymptomatically. This slow growing tumour consist of an accumulation of mucoid ground substance with little collagen, the amount of which determines whether it can be called a myxofibroma. Only occasionally does odontogenic myxoma show the presence of odontogenic epithelium.1,2,3 The origin of odontogenic myxoma normally occurred from ectomensechyme. Besides this the tumor cells have been postulated to originate from normal or transformed fibroblasts4,5 or from other cells thorough mesenchymal or myofibroblastic differentiation.6 Some authors had previously associated its origin with a myxomatous change of an odontogenic fibroma3,7 or residual foci of embryonic tissue. Based on the information gathered from the available literature it is still somewhat arguable whether odontogenic myxoma is truly an odontogenic neoplasm. However, its histological similarity to the stellate reticulum of a developing tooth, its exclusive occurrence in close proximity to the tooth bearing parts of the jaws, the occasional association with a missing or unerupted tooth, the presence of odontogenic epithelium in a minority of cases and the fact that it rarely appears in other parts of the skeleton, offer support to an odontogenic origin.[3,8]

Radiographically, odontogenic myxomas appear most commonly as multilocular radiolucencies with an ill-defined boarders, though unilocular cyst-like tumors occur, especially when associated with impacted teeth or when discovered in childhood.9 Ideally, the septa that cause the multilocular feature are thin and straight, producing a tennis racket or stepladder pattern. In reality, the majority of the septa visible in the tumor are curved and coarse, causing a "soap bubble" or "honeycomb" appearance, though locating one or two straight septa can aide in the diagnosis of this tumor. Multilocular lesions are more aggressive and have more recurrence rate. Here a case is reported with multilocular odontogenic myxoma who was treated conservatively.

Case Report:

An otherwise healthy 34 years old female patient with unremarkable medical history reported with a swelling in relation to left submandibular region since 3 months. She has been operated 6 months back for the same lesion in other institution. Extra-oral examination revealed a diffuse swelling of about 3-4 cm starting from angle of mouth to inferior border of mandible. (Fig.1a)

Intra-orally left lower buccal vestibular was obliterated. Teeth were missing in relation to swelling except left mandibular third molar, which was present but was mobile clinically along with paresthesia in the distribution of left inferior alveolar nerve. (Fig.1b)

Radiographically, a multilocular radiolucency was seen on orthopantomograph. (Fig.1c) Patient couldn't provide any document related to previous surgery which was taken place 6 months back on the same site. An incisional biopsy was done under local anesthesia and specimen was sent for the histopathological examination which confirmed the diagnosis of odontogenic myxoma.(Fig.1d) As it was multilocular lesion with recurrence, mandibular resection was the treatment of choice but due to patient poor response and considering patient esthetics, a conservative approach was planned. A complete enucleation and curettage was done under general anesthesia with extraction of left mandibular third molar. Cornoy's solution was applied for 4 minutes on the bone and 2 minutes on soft tissues. Haemostatis was achieved and iodoform pack was placed with closure of flaps. The patient was kept on regular follow-up for 2 years. A regular change of iodoform pack was done weekly till satisfactory bone formation was seen radiographically. (Fig.1e)

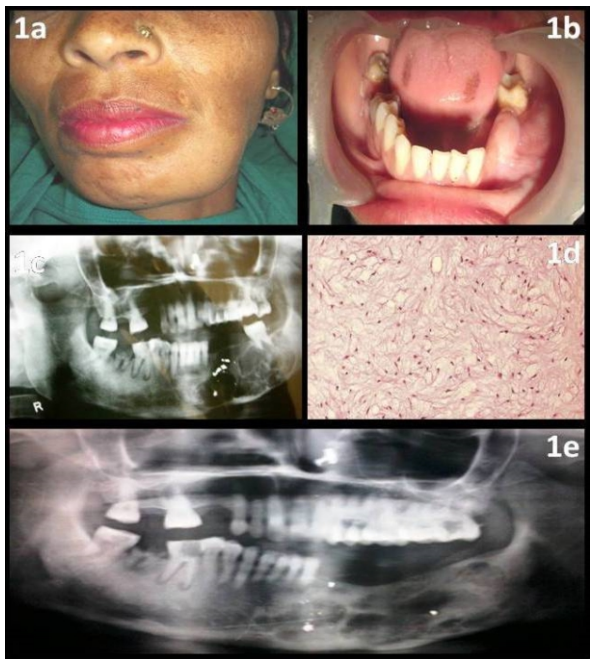

Discussion- Odontogenic myxoma is a non-encapsulated benign tumor of the jaws that rarely occurs. It derives from the dental mesenchyme or periodontal ligament. Previous studies refer the tip of the incidence in the third decade of the life, and the majority of the cases between 10 and 40 years-old. Our case surpasses the third decade of life, but can be addressed within the range referred in the literature. Globa¬lly, it represents 3 to 6% of all odontogenic tumors. Although it's most frequent location is the posterior mandible, other locations such as the incisive sector, upper maxilla and mandibular condyle must be considered.10 Present case showed multilocular odontogenic myxoma lesion in majority of mandibular body.

Clinically, myxoma has been described as a slow-growing asymptomatic mass. The presence of pain, paresthesia, ulce¬ration and dental mobility has been referred in the literature11. In our case paresthesia along with mobility of tooth was present. In the X-ray examination, it may show uni- or multilocular "soap-bubble" or "honey-panel" pattern, with cortical expansion and dental displacement. External and internal cortical displacement can be very evident, with bone destruction and soft tissue protrusion as in our case. No mid line cross over was observed. Although extensive surgery is recommended by many authors as odontogenic myxoma is locally aggressive lesion but here authors advocates conservative approach. The lesion was treated by enucleation and complete curettage followed by application of cornoy's solution and regular replacement of Iodoform pack till satisfactory bone formation was observed. Carnoy's solution (60% ethanol, 30% chloroform and 10% glacial acetic acid) is used as an adjuvant therapy to help eliminate epithelial microcysts and prevent recurrence. Thus our case showed that complete enucleation with curettage is a good choice of treatment for multilocular odontogenic myxoma.

Reference:

1. Farman AG, Nortje CJ, Grotepass FW, Farman FJ, Van Zyi JA. Myxofibroma of the jaws. Br J Oral Surg 1977: 15: 3–18.
2. Keszler A, Dominguez FV, Giannuzio G. Myxoma in childhood. An analysis of 10 cases. J Oral Maxillofac Surg 1995: 53: 518–521.
3. Kramer IRH, Pindborg JJ, Shear M. WHO. Histologic Typing of Odontogenic Tumours. Berlin: Springer-Verlag 1992: 7–9.
4. Takahashi H, Fujita S, Okabe H. Immunohistochemical investigation in odontogenic myxoma. J Oral Pathol Med 1991;20:114-9.
5. Prout RE, Hodson JJ. Analysis of the mucopolysaccharide of a myxoma of the mandible. Nature 1968;218:99-100.
6. Fujita S, Hideshima K, Ikeda T. Nestin expression in odontoblasts and odontogenic ectomesenchymal tissue of odontogenic tumors. J Clin Pathol 2006;59:240-5.
7. Thoma KH, Goldman HM. Central myxoma of the jaws. Am J Orthop 1947: 33: 532–540.
8. VAN DER WAAL I. Diseases of the Jaws: Diagnosis and Treatment. Copenhagen: Munksgaard 1991: 206.
9. McDonald, Ralph E., David R. Avery, and Jeffrey A. Dean. Dentistry for the Child and Adolescent. 8th ed. St. Louis, MO: Mosby, 2004. 163-64.
10. Halfpenny W, Verey A, Bardsley V. Miyoma of the mandibular condyle. A case report and review of the literature. Oral Surg Oral Med Oral Pathol Endod 2000;90:348-53.
11. Kangur TT, Dahlin DC, Turlington EG. Myxomatous tumors of the jaws. J Oral Surg 1975;33:523-8.