ORIGINAL RESEARCH PAPER
Volume-6 | Issue-11 | November-2017 | ISSN No 2277 - 8179 | IF : 4.176 | IC Value : 78.46
INTERNATIONAL JOURNAL OF SCIENTIFIC RESEARCH

" CORNEAL ENDOTHELIAL CHANGES IN HIV-INFECTED PATIENTS: A DESCRIPTIVE COMPARATIVE STUDY"

Ophthalmology

Dr. Shashi Ahuja MS Ophthalmology Additional Professor, Department of Ophthalmology Jawaharlal Institute of Postgraduate Medical Education and Research, Puducherry.

Dr Vijitha Vempuluru Sai* MS Ophthalmology Department of Ophthalmology, Jawaharlal Institute of Postgraduate Medical Education and Research, Puducherry. *(Corresponding Author)

Dr Abdoul Hamide MD General Medicine Senior Professor and Head, Department of Medicine, Jawaharlal Institute of Postgraduate Medical Education and Research, Puducherry.

ABSTRACT

It is well known that HIV-infected patients are at a risk of accelerated senescence systemically. Studies on corneal endothelium evaluating the effect of accelerated senescence have shown conflicting evidence. Therefore, whether accelerated senescence affects the corneal endothelium HIV infection is questionable. In our study, it was found that patients with HIV-infection have a lower endothelial cell count and higher average cell size as compared to seronegative individuals. It was also noted that patients with longer duration of HIV infection have increased central corneal thickness. Thus, specular microscopy can be used as a preoperative tool to assess apparently healthy corneas in HIV-infected patients.

KEYWORDS

Cornea, Corneal Endothelium, HIV, Accelerated senescence

INTRODUCTION

Human Immunodeficiency Virus(HIV) infection is characterised by increased susceptibility to comorbid diseases due to higher occurrence of risk factors like substance abuse, chronic inflammation, immunosuppression and anti-retroviral treatment. These factors increase vulnerability to stress and decrease functionality. This led to a hypothesis that the aging process is accelerated by HIV-infection.(1,2) The corneal endothelium is essential for maintaining the transparency of the cornea. Any cellular alterations in it thereby influences the health of the cornea. The endothelial cells have no substantial replicative potential in vivo. The endothelial cell density decreases with age as evidenced by morphological studies. It has also been observed that human corneal endothelium displays signs of oxidative DNA damage in response to stress.(3) The corneal endothelium can be observed by a variety of methods namely slit-lamp biomicroscopy, specular microscopy, and confocal microscopy. While subtle corneal endothelial changes can be missed on slit-lamp examination, specular microscopy and confocal microscopy assess corneal endothelium at a cellular level.(4) The specular microscope captures an image of the corneal endothelium. Commonly assessed endothelium parameters are: endothelial cell density (ECD), polymegathism (coefficient of variation in cell size, CV) and hexagonality index (6A). Central corneal thickness (CCT) or pachymetry can also be measured. These parameters portray the overall health of the corneal endothelium (5)

Recently the phenomenon of premature aging in HIV-infection has gained importance. Various parameters have shown changes consistent with premature aging.(6–12) The corneal endothelium is one such parameter and few studies have explored its potential as a marker of accelerated senescence in HIV-infected patients. A study conducted by Pathai et al showed that the corneal endothelial cells can serve as biomarkers for aging.(7) However a similar study conducted by Demirkaya et al has refuted this theory.(13) Therefore, whether accelerated senescence affects the corneal endothelium in HIV-infected patients is debatable. Moreover, the Indian subcontinent shares a significant burden of the world's HIV-infection and there is a paucity of literature to establish accelerated aging in HIV-infection.

METHODS

This was a descriptive comparative study of known patients of HIV (Group I) and sero-negative individuals (Group II) of comparative age and gender who underwent HIV testing for several purposes. Exclusion criteria were: pseudoexfoliation, previous photocoagulation, uveitis, glaucoma, corneal pathology, prior intraocular surgery, diabetes mellitus. A total of 130 patients were enrolled after obtaining an informed consent. Relevant history was obtained followed by detailed ophthalmic examination. Non-contact specular microscope (Konan Noncon Robo) was used to image the corneal endothelium. All the images were captured by a single observer in automatic mode to eliminate bias. Two images were captured per eye and both the eyes were photographed. Automated morphometric analysis was done to obtain: Mean corneal endothelial cell density (ECD expressed as cells/mm^2), Coefficient of variation of cell size (CV expressed as percentage), Hexagonality (6A expressed as percentage), Average cell size(expressed in µm^2), Central corneal thickness (CCT or Pachymetry expressed in µm). (Figure 1)

Figure 1: Specular Microscopic image showing corneal endothelial parameters

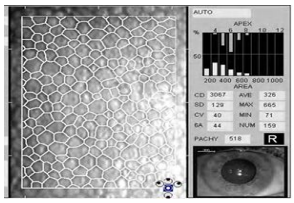

Statistical tests and analyses were based on the average values from both eyes. Data was analysed using OpenEpi version 3.0. The results i.e. ECD, CV, 6A, AVE, CCT were expressed as mean ± standard deviation (mean ± SD). The Student's t-test (parametric test for normal distribution) was employed to compare parameters between the two groups. Endothelial parameters in HIV-infected patients were assessed w.r.t. duration of disease, ART intake and CD_4 counts. $P \leq 0.05$ was considered to be statistically significant.

RESULTS

65 HIV-infected patients comprised of Group I and 65 sero-negative individuals were included as Group II.

DESCRIPTIVE DATA: HIV-infected group had 32 (49.2%) males and 33 (50.8%) females. Sero-negative group had 24 (36.9%) males and 41(63.1%) females. The difference in gender distribution was not statistically significant ($p = 0.1565$). Age-distribution was skewed. (Figure 2).

Figure 2: Age-wise distribution in Group I and Group II

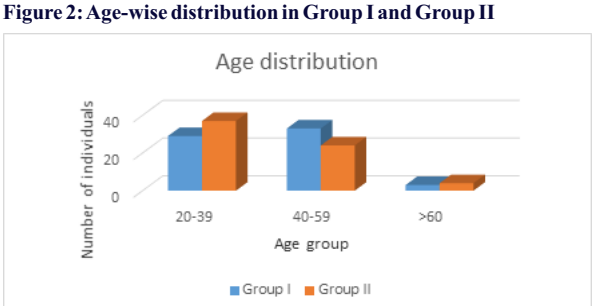

Table 1: Characteristics of HIV-infected patients

Duration of disease (Total: 65)	**< 5 year:** **>5 year:**	55 (84.6%) 10 (15.4%)
HIV retinopathy (Total: 65)	**Present:** **Absent:**	7 (11%) 58 (89%)
CD4 counts (cells/L) (Total: 65)	**<200 :** **>200:**	15 (21.1%) 51 (78.9%)
ART (Total: 65)	**On ART:** **ART Naïve:**	47 (72.3%) 18 (27.7%)

MAIN RESULTS: The mean ECD was lower and AVE higher in HIV-infected group, the difference being statistically significant (p value 0.0019 and 0.0214 respectively) (Table 2).

This derangement in ECD and AVE was noted to be maximum in older age-groups (>60 yrs). (Table 3)

Table 2: Mean values of endothelial cell parameters between Group I and Group II across all age groups

	ECD(cell/mm²)	CV(%)	6A(%)	Av. Cell size(µm²)	CCT(µm)
Group I	2755.82 ±191.21	38.38 ±3.84	46.70 ±3.96	360.96 ±35.85	538.51 ±34.92
Group II	2857.98 ±175.54	39.07 ±4.01	47.37 ±5.34	347.22 ±31.23	536.85 ±27.92
p value	**0.0019**	**0.319**	**0.416**	**0.0214**	**0.765**

Table 3: Comparison of mean Endothelial Cell Density and Average Cell Size between Group I and Group II different age groups expressed in (mean ± SD)

Age group (Years)	Group I (ECD) (cell/mm²)	Group II (ECD) (cell/mm²)	P value	Group I (AVE) (µm²)	Group II (AVE) (µm²)	p value
21-39	2829.33 ±118.71	2888.02 ±168.00	0.116	347.72 ±24.84	339.72 ±34.72	0.299
40-59	2699.65 ±216.37	2791.76 ±171.86	0.090	370.98 ±40.44	360.45 ±22.14	0.253
>60	2663.00 ±283.31	2977.50 ±164.28	0.120	378.67 ±40.62	337.25 ±19.00	0.127

There was no statistically significant difference in CV, 6A and CCT between the two groups though 6A and CCT showed derangement in HIV-infected patients. (Table 4).

Table 4: Comparison of coefficient of variation and hexagonality between Group I and Group II across different age groups expressed in (mean ± SD)

Age group (Years)	Group1 (CV)	Group II (CV)	p value	Group I (6A)	Group II (6A)	p value	Group I (CCT)	Group II (CCT)	p value
21-39	38.05 ±4.26	38.3 ±3.49	0.792	47.19 ±4.26	48.51 ±5.90	0.315	545.52 ±39.02	534.59 ±23.67	0.164
40-59	38.40 ±3.41	40.30 ±4.70	0.095	46.47 ±3.45	45.30 ±4.11	0.250	534.14 ±30.18	536.03 ±32.36	0.821
>60	40.50 ±4.82	38.75 ±2.90	0.572	44.50 ±6.76	49.31 ±2.34	0.233	518.83 ±38.87	562.69 ±30.37	0.152

OTHER ANALYSES

CD_4 counts: The mean ECD was higher in the sero-negative group (2737.66 ± 199.60 cell/mm²) as compared to sub group of HIV infected patients with CD_4< 200 cells/L (2857.98 ± 175.54 cell/mm²) and the difference was statistically significant (p = 0.0259). There was no statistically significant difference in the corneal endothelial parameters between individuals with CD_4 counts ≤ 200 cells/L and those with >200cells/L.

Duration of disease and ART: The average CCT with disease duration less than 5 years was significantly higher in patients with disease duration >5 years (558.53 ± 42.26 µm vs 534.87 ± 32.55 µm, p = 0.0479). The mean ECD in patients with longer disease duration was lower, however, the difference was not statistically significant. CV, 6A and AVE showed a similar trend (Table 5). ART intake did not affect the corneal endothelial parameters significantly (Table 5).

Table 5: Variation of corneal endothelial parameters in HIV infected patients according to duration of HIV and ART intake

HIV Duration	ECD(cell/mm²)	CV(%)	6A(%)	Av. Cell size (µm2)	CCT(µm)
<5 years	2759.25 ±195.09	38.29 ±3.94	46.18 ±3.68	360.28 ±34.07	534.87 ±32.55
>5 years	2736.93 ±176.51	38.90 ±3.35	46.63 ±5.50	364.70 ±46.47	558.53 ±42.26
p value	0.737	0.646	0.949	0.723	0.0479
ART intake	ECD(cell/mm²)	CV(%)	6A(%)	Av. Cell size (µm2)	CCT(µm)
Yes	2769.40 ±179.95	38.26 ±4.06	46.56 ±4.17	359.15 ±35.34	536.09 ±36.09
No	2720.35 ±219.50	38.71 ±3.29	47.06 ±3.44	365.67 ±37.77	544.83 ±31.72
p value	0.359	0.674	0.658	0.517	0.370

DISCUSSION

The estimated number of people living with HIV (PLHIV) in India is about 21 lakh (17-26 lakh).(14). Over the past years, diagnosis and treatment of HIV/AIDS have improved remarkably due to surveillance activities by the National AIDS Control Organisation (NACO).(15) Thus the longevity of PLHIV has increased due improved ART regimes and so has their susceptibility to non-AIDS-related morbidity including diseases of the heart, liver, kidney, bone and the central nervous system. This increased risk of PLHIV to develop age-related illnesses at an earlier age has lead to an assumption that aging is hastened in PLHIV, despite ART and well-suppressed viremia.(16,17)

There are various markers used to identify senescence related changes in the human body. Systemic markers include CDKN2A expression, 8-hydroxy-2'-deoxyguanosine levels, telomere length, etc. Ocular markers include changes in corneal endothelium, lens thickness, retinal nerve fibre thickness, and retinal arteriolar narrowing.(6) This study assessed corneal endothelium in HIV-infected patients to idenify subclinical changes which can be utilised as a biomarker of accelerated senescence, and to take adequate protective measures if the need were to arise for an intraocular surgery. With increase in incidence of cataracts as a result of increased longevity and accelerated senescence, assessment of the corneal endothelium has prognostic significance. (18)

The in ECD between the two groups was statistically significant. This was compatible with the study conducted by Pathai et al in which median ECD was 2614 cells/ mm²in HIV-infected and 2660 cells/ mm² in sero-negative individuals. However, variation in ECD did not reach a statistical significance in their study (p = 0.56).(7) The age-wise break-up of mean ECD showed a similar trend significant clinically, though not statistically significant. Similar observation was made by Demirkaya et al where after correcting for age the difference between corneal endothelial parameters between HIV infected patients and seronegative individuals was not statistically significant.(13) Age group >60 years showed maximum difference in ECD. These findings agreed with observations made by Pathai et al where increasing age was strongly associated with low ECD both in univariable and multivariable analysis.(7) However, in our study this did not reach a statistical significance due to smaller fraction in the sub-group.

In our study, mean ECD was lower in the sub-group of HIV-infected patients with CD_4< 200 cells/µL as compared to sero-negative and the difference was statistically significant (p value 0.0259). Pathai et al showed that patients with CD_4 counts <200 cells/µL were almost three times more likely to have a low cell density than those with CD_4 counts >200 cells/µL (OR = 2.77; 95%CI: 1.12–6.81).(7)

The mean ECD with disease duration >5 years was lower. The difference was not statistically significant . Demirkaya et al in their study showed significant association between longer duration of HIV-infection and lower endothelial cell density.(13)

ART intake and duration did not appear to influence the ECD significantly. This finding may be explained by the fact that the corneal endothelial cells once lost, cannot be replaced. Another conclusion drawn is that ART itself does not influence the corneal endothelium by accelerated senescence. The effect of ART on corneal endothelial parameters has not been studied earlier.

Mean AVE was higher in the HIV-infected group as compared to sero-negative group, the difference being statistically significant (p value

0.0214). This was in concordance with Pathai et al who showed that HIV was associated with higher polymegathism quartiles in univariable analyses (p value 0.04). (7) Demirkaya et al also demonstrated similar findings.(13) This result is in agreement with the hypothesis that the corneal endothelium reflects the expedited senescent changes in HIV-infected patients. CD_4 counts did not appear to influence AVE in our study unlike the observation made by Pathai et al.(7) Smaller proportion of patients with poor CD_4 counts in our study may account for this finding.

CV was not significantly different between the HIV-infected group and the sero-negative group in our study. CD_4 counts, duration of seropositivity and ART intake did not show significant correlation with CV which were similar to findings reported by Pathai et al.(7) The mean 6A was lower in the HIV infected group (46.70±3.96 %) as compared to the sero-negative group (47.37±5.34 %). The maximum derangement between the two groups was noted in the age group of >60years. Though not statistically significant , similar observation was made by Pathai et al. (6) CD_4 counts did not affect 6A, similar to studies conducted by Pathai et al and Demirkaya et al.(7,13) ART intake did not influence 6A to a significant extent as was the case with ECD.

Effect of ART on CV and 6A was not assessed in previous studies. In our study it appeared to be deranged in patients on ART for >5 years than those on ART for <5 years, though it failed to reach statistical significance.

CCT is a measure of functionality of the corneal endothelium and increased CCT is suggestive of impaired functionality. CCT was not assessed in any of the previous studies in HIV-infected patients. Our study showed higher mean CCT in HIV infected patients was than in sero-negative patients, though not statistically significant. Another observation which carries clinical relevance made was that the difference in the mean CCT in the age group >60 years between the two groups was 43.66 µm. Mean CCT in the sub group of HIV infected patients with CD_4< 200 cells/µL was higher as compared to sero-negative though it failed to reach a statistical significance.

The mean CCT among patients with disease duration >5 years was significantly higher (difference 23.66 µm, p value 0.0479). This study is the first to note this finding and the increase in CCT was similar to observations made by Su et al and Wong et al in chronic illnesses, explained by the common factor of accelerated aging. (19,20) Wong et al stated that increased CCT may be explained by the presence underlying inflammation in chronic diseases. (20) This suggests that there may be early functional loss of endothelium with increasing duration of HIV similar to chronic diseases.

Duration of ART showed no significant difference. It may be inferred that longer duration of ART results in suppression of viraemia, thus slowing down the senescence related changes and improvement in functionality. However, the structural changes are irreversible as seen with ECD, 6A and CV.

HIV-infection was associated with decreased ECD and increased polymegathism. Increasing duration of HIV showed an increase in mean CCT values. Thus, HIV-infection results in derangement in structural as well as functional parameters and these alterations are consistent with premature senescence.

Guaraldi et al found that non-infectious morbidity was higher in HIV patients.(21) Studies show that cardiovascular disease accounts for 30% of mortality. Since HIV-infected persons are at increased risk of cardiovascular illnesses screening is helpful.(22) Senescene markers can provide information about the immune-senescence occurring in PLHIV and this includes ocular parameters such as corneal endothelial parameters. (6,23)

Vascular endothelial dysfunction has emerged a major mechanism involved in the increased cardiovascular disease risk seen in the HIV population.(21) Boulanger and Lopez et al studied micro-particles from endothelium and platelets as biomarkers of endothelial dysfunction in HIV. (23,24) Coexistent vascular endothelial dysfunction and accelerated corneal endothelial cell loss, is known to occur in diabetes mellitus.(23,25) However, if the underlying etiology is chronic inflammation is not proven. Further studies may establish an association between ocular and systemic markers of accelerated senescence and increased cardiovascular risk.

Limitations: The duration of HIV-infection was based on history and time of diagnosis. The actual duration may vary due to possibility of harbouring undiagnosed asymptomatic infection. Another factor in our study that confines interpretation was the smaller proportion of patients in sub-groups. Though this study offers information on senescence-related corneal endothelial changes in Indian subcontinent, we also feel a larger sample size with even distribution in sub-groups can establish stronger evidence.

Conclusion: HIV-infected patients have a deranged corneal endothelium when compared to seronegative individuals, the difference greater in older sub-groups. CD_4 counts and HIV duration influence the ECD and CCT respectively. ART does not significantly alter the corneal endothelial parameters.

REFERENCES

1. Joyce NC, Zhu CC, Harris DL. Relationship among oxidative stress, DNA damage, and proliferative capacity in human corneal endothelium. Invest Ophthalmol Vis Sci. 2009 May;50(5):2116–22.
2. Deeks SG, Phillips AN. HIV infection, antiretroviral treatment, ageing, and non-AIDS related morbidity. BMJ. 2009;338:a3172.
3. Joyce NC. PROLIFERATIVE CAPACITY OF CORNEAL ENDOTHELIAL CELLS. Exp Eye Res. 2012 Feb;95(1):16–23.
4. Benetz B, Yee RW, Bidros M, Lass JH. Specular Microscopy. In: Krachmer J, Mannis M, Holland E,eds Cornea. 3rd ed. Philadelphia: Elsevier Mosby; 2011. p. 178–98.
5. McCarey BE, Edelhauser HF, Lynn MJ. Review of Corneal Endothelial Specular Microscopy for FDA Clinical Trials of Refractive Procedures, Surgical Devices and New Intraocular Drugs and Solutions. Cornea. 2008;27(1):1–16.
6. Pathai S et al. Ocular parameters of biological ageing in HIV-infected individuals in South Africa: Relationship with chronological age and systemic biomarkers of ageing. Mech Ageing Dev. 2013;134(9):400–6.
7. Pathai S et al. Corneal Endothelial Cells Provide Evidence of Accelerated Cellular Senescence Associated with HIV Infection: A Case-Control Study. PLOS ONE. 2013; 8(2):e57422.
8. Pathai S et al. Accelerated biological ageing in HIV-infected individuals in South Africa: a case-control study. AIDS Lond Engl. 2013;27(15):2375–84.
9. Pathai S et al. Increased ocular lens density in HIV-infected individuals with low nadir CD4 counts in South Africa: evidence of accelerated aging. J Acquir Immune Defic Syndr 1999. 2013;63(3):307–14.
10. Pathai S et al. Frailty in HIV-infected adults in South Africa. J Acquir Immune Defic Syndr 1999. 2013;62(1):43–51.
11. Pathai S et al. Differing spectrum of HIV-associated ophthalmic disease among patients starting antiretroviral therapy in India and South Africa. Trop Med Int Health TM IH. 2011;16(3):356–9.
12. Pathai S, Bajillan H, Landay AL, High KP. Is HIV a model of accelerated or accentuated aging? J Gerontol A Biol Sci Med Sci. 2014;69(7):833–42.
13. Demirkaya N et al. Visual function and corneal endothelium analysis in patients with well-suppressed HIV infection: a matched case-control study. Invest Ophthalmol Vis Sci. 2015;56(7):1147–1147.
14. WHO | HIV/AIDS [Internet]. [cited 2016 Aug 7]. Available from: http://www.who.int/gho/hiv/en/
15. 20_Part-B NACO - Annual report _NACO_2014-15.pdf [Internet]. [cited 2016 Jul 17]. Available from: http://www.naco.gov.in/upload/2015%20MSLNS/Annual%20report%20_NACO_2014-15.pdf
16. Deeks SG. HIV infection, inflammation, immunosenescence, and aging. Annu Rev Med. 2011;62:141–55.
17. Deeks SG. Immune dysfunction, inflammation, and accelerated aging in patients on antiretroviral therapy. Top HIV Med Publ Int AIDS Soc USA. 2009 ;17(4):118–23.
18. Rasmussen LD et al. Risk of cataract surgery in HIV-infected individuals: a Danish Nationwide Population-based cohort study. Clin Infect Dis Off Publ Infect Dis Soc Am. 2011; 53(11):1156–63.
19. Su DHW et al. Central corneal thickness and its associations with ocular and systemic factors: the Singapore Malay Eye Study. Am J Ophthalmol. 2009 Apr;147(4): 709–16.e1.
20. Wong CW, Wong TY, Cheng C-Y, Sabanayagam C. Kidney and eye diseases: common risk factors, etiological mechanisms, and pathways. Kidney Int. 2014 Jun;85(6):1290–302.
21. Guaraldi G et al. Premature Age-Related Comorbidities Among HIV-Infected Persons Compared With the General Population. Clin Infect Dis. 2011 Dec 1;53(11):1120–6.
22. Microsoft Word - WHO Background paper on integration of NCDs Peter Lamptey FOR DISPATCH.doc - [Internet]. [cited 2016 Aug 8]. Available from: http://www.who.int/global-coordination-mechanism/working-groups/WHO_Background_paper_on_integration_of_NCDs_Peter_Lamptey_FOR_DISPATCH.pdf
23. Boulanger C-M, Leroyer A-S, Amabile N, Tedgui A. [Circulating endothelial microparticles: a new marker of vascular injury]. Ann Cardiol Angéiologie. 2008 Jun;57(3):149–54.
24. López M et al. Endothelial dysfunction in HIV infection--the role of circulating endothelial cells, microparticles, endothelial progenitor cells and macrophages. AIDS Rev. 2012 Dec;14(4):223–30.
25. Schultz RO et al. Corneal endothelial changes in type I and type II diabetes mellitus. Am J Ophthalmol. 1984 Oct 15;98(4):401–10.