ORIGINAL RESEARCH PAPER

Volume-8 | Issue-6 | June-2019 | PRINT ISSN No. 2277 - 8179

INTERNATIONAL JOURNAL OF SCIENTIFIC RESEARCH

CORRELATION BETWEEN OCULAR MANIFESTATIONS AND PLATELET COUNT IN DENGUE FEVER

Ophthalmology

Dr. Padmajothi M. S Professor, Department of Ophthalmology, Sri Devaraj Urs Medical College, Tamaka, Kolar

Dr. Chaitra M. C* Assistant Professor, Department of Ophthalmology, Sri Devaraj Urs Medical College, Tamaka, Kolar *Corresponding Author

Dr. M. Madhumita Post graduate, Department of Ophthalmology, Sri Devaraj Urs Medical College, Tamaka, Kolar

ABSTRACT

Purpose: To evaluate the presence or absence of ocular manifestations in serologically established cases of dengue fever & to correlate the platelet count with the severity of ocular complications in serologically established cases of dengue.

Methods: A Case series of 40 patients were involved in this study. Data were collected from patients admitted with diagnosis of Dengue fever eye, confirmed by serological tests (IgM and IgG ELISA) in in-patients irrespective of presence or absence of eye manifestations in our hospital. After taking informed consent, demographic details and detailed history were taken and Ophthalmic examination which included visual assessment (either bedside or by Snellens chart in ambulatory patients), anterior segment examination and posterior segment examination by direct and indirect ophthalmoscope and 90D lens. Platelet count at the time of examination was documented.

Results: 40 cases were serologically positive (IgM and IgG ELISA) for dengue. 33 cases had thrombocytopenia (82.5%). 25 cases had ocular manifestations, out of which 19 cases had petechial subconjunctival haemorrhage and 6 cases had dot blot haemorrhages in the retina. Patients who had subconjunctival haemorrhage had platelet count ranging between 30,000- 50,000 cells/ microlitre and patients with dot and lot haemorrhages in retina had platelet counts ranging between 20,000 – 25,000 cells/microlitre.

Conclusion: A relevant ophthalmological evaluation must be stressed in every patient afflicted with dengue fever in order to detect these complications at the right time and to prevent any residual impairment of vision.

KEYWORDS

Dengue Fever, Ocular Manifestations, Platelet count.

INTRODUCTION:

In the recent years Dengue fever has emerged as one of the most important arthropod tropical infections with an estimated 2.5 billion people at risk all over the world.[1] Arboviruses are viruses of vertebrates which multiply in blood sucking insects and are biologically transmitted by hematophagous insect vector (bite of female anopheles Aedes aegypti) to vertebrate hosts. Over last 15 to 20 years infection with dengue virus is witnessing a global resurgence. The annual incidence globally now exceeds 5,00,000 cases and is still rising despite the environmental control.[2] Any of the four serotypes of the dengue virus may be responsible for an epidemic. Infection with one serotype has lifelong immunity against that serotype. Also it has transient and partial immunity against subsequent infection by other serotypes. Sequential infections with other serotypes may increase the risk of more serious systemic disease, such as dengue hemorrhagic fever (DHF) or dengue shock syndrome (DSS), which are life-threatening.

The clinical manifestations of dengue infection varies from asymptomatic to severe life threatening illness[3]. Dengue hemorrhagic fever or Dengue Shock Syndrome may be fatal in 40% to 50% of untreated patients, however, with appropriate treatment the mortality can be brought down to one to five percent[4]. A favourable temperature < 200C and stagnant water for the breeding of Aedes aegypti is required for an Epidemic transmission. The resurgence of infections is attributed to decay in public health infrastructure, lack of mosquito control, unplanned urbanization and global population explosion. Increase in air travel and excellent mode of transport of pathogens also contributes spread. The DHF / DSS remained a disease of children and young adults for two decades after its identification in the 1950s.

The epidemics from Malaysia and Delhi, which occurred recently, show more affection of adults than children. The reasons for this change in epidemiology of DHF are not clear.[1] Laboratory diagnosis of dengue virus infection depends upon demonstration of specific antibodies in serum samples by haemagglutination inhibition, complement fixation, neutralization test or ELISA.[5] Dengue as a disease has been poorly studied and few lacunae remain in the understanding of the presentations, the complications and the treatment of the disease. Ocular manifestation of DF have received little attention in published literature. There are isolated reports of DF who mainly presented with visual impairment due to posterior segment involvement[6]. Other manifestation included retinal haemorrhages and retinopathy. DF and DHF can cause ophthalmic symptoms that are not previously well-described in the literature. Diminution of vision typically coincides with the nadir of thrombocytopenia and occurs 1 week after onset of fever.[7] Clinical features include retinal edema, blot haemorrhages, vasculitis foveolitis, optic neuropathy. Less common features are exudative retinal detachment, cotton wool spots, and anterior uveitis, periphlebitis, branch retinal vein occlusion and vitreous hemorrhage. Prognosis is good as the disease is often self-limiting, resolving spontaneously even without treatment. However, patients may experience relative central scotoma that may persist for months. The use of steroids is controversial in treating this inflammatory eye condition.

In our personal experience, 3 cases, of which one was a 13 year old girl and two were males of about 45 years of age presented with acute, bilateral, severe chorioretinitis with macular edema who had gross visual disturbance were observed. This led to the formulation of this scientific study to correlate between the platelet count, ophthalmic manifestations and the visual impairment associated with it.

OBJECTIVES:

To evaluate the ocular manifestations in serologically established cases of Dengue fever and to correlate the platelet count with the severity of ocular complications in serologically established cases of Dengue.

METHODS

A Case series of 40 patients belonging to all age groups irrespective of presence or absence of ocular manifestations, were included in this study. Data were collected from patients admitted with diagnosis of Dengue fever, confirmed by serological tests (IgM and IgG ELISA) at R L Jalappa Hospital & Research Center, Kolar. After taking informed consent, demographic details and detailed history were taken. Patients with history of hypertension, Diabetes mellitus and anemia were excluded from the study.

All patients underwent a complete Ophthalmic examination which included visual assessment (either bedside or by Snellens chart in ambulatory patients), anterior segment evaluation by slit lamp biomicroscopy and posterior segment examination by direct and

indirect ophthalmoscope and 90D lens. Platelet count at the time of examination was documented.

INCLUSION CRITERIA

Patients belonging to all age groups, who were serologically positive for dengue fever with or without ocular manifestations were included in this study.

EXCLUSION CRITERIA

Patients with history of Hypertension, Diabetes mellitus and Anemia were excluded from this study.

RESULTS

All patients who were serologically positive (IgM and IgG ELISA) for Dengue fever were examined. Keeping the exclusion parameters in mind, a total of 40 patients underwent a comprehensive ophthalmic examination. The platelet count at the time of examination was documented. The mean time interval of presentation of ocular features in these patients was in the range of 6 – 12 days.

Out of the 40 cases, 33 cases had thrombocytopenia (82.5%) in which 25 cases had ocular manifestations. Out of these, 19 cases had petechial subconjunctival haemorrhage with platelet count ranging between 30,000- 50,000 cells/microlitre and 6 cases had dot blot haemorrhages in the retina with platelet count ranging between 20,000 – 25,000 cells/microlitre.

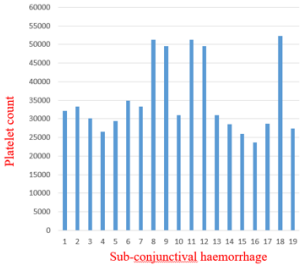

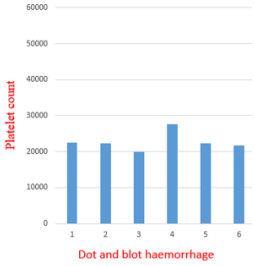

DISCUSSION

Dengue fever, also known as break bone fever, is a communicable disease transmitted by the bite of Aedes mosquitoes. It is one of the major public health problem affecting people of tropical and subtropical countries.[8]

The various manifestations of Dengue are believed to be a result of either direct viral invasion or a complex immune-mediated process. It has been speculated that viral invasion of endothelial cells, dendritic cells, monocytes, and hepatocytes causes apoptosis and cellular dysfunction, followed by the transient aberrant immune response, resulting in CD4/CD8 ratio inversion and cytokine overproduction, deleterious effects on these cells. Overproduction of interlukin-6 triggers the formation of autoantibodies against platelets and endothelial cells resulting in further immune mediated damages.

Subconjunctival haemorrhages, retinal haemorrhages and exudates could be due to generalized increased capillary permeability, plasma leakage, and haemorrhagic diathesis associated with endothelial dysfunction destruction and consumptive coagulopathy[6]. Pathogenesis of cotton wool spots could be related to occlusion of pre-capillary arterioles in the retinal nerve fiber layer by immune complex deposition. Lim et al[9], in their study suggested the possibility of specific autoantibodies being produced against retina, retinal pigment epithelium or choroid, but exact mechanisms responsible for the various ocular alterations in dengue still remain unknown. Gomber et al, reported that there was no significant association between thrombocytopenia and haemorrhagic manifestations, signifying that there may be other factors like platelet dysfunction and disseminated intravascular coagulopathy, responsible for bleeding. Less common features are exudative retinal detachment, cotton wool spots, and anterior uveitis, periphlebitis, branch retinal vein occlusion and vitreous hemorrhage. Blurring of vision coincides with the nadir of thrombocytopenia and occurs 1 week after onset of fever. According to Harutoglou et al[10], some findings resolve spontaneously even without treatment.

In our study ocular manifestations were almost similar, with 47.5% cases had petechial subconjunctival haemorrhage with platelet count ranging between 30,000- 50,000 cells/ microlit and 15% cases had dot blot haemorrhages in the retina with platelet counts ranging between 20,000 – 25,000 cells/microliter.

Kapoor et al[11] studies showed prevalence of ocular findings in 40.3% of patients, and 37.3% patients had anterior segment findings in the form of petechial and diffuse subconjunctival hemorrhage . In our study, the prevalence was 62.5% of which 47.5% had petechial hemorrhages. The most common ocular manifestation in our patients was subconjunctival hemorrhage followed by dot blot retinal hemorrhages in the retina. It was similar to another study by Agarwal et al[12] as well. However in our study patients having vitreous haemorrhage, optic neuropathy, periorbital ecchymosis, ptosis and anterior uveitis were not observed.

The appropriate anticipation of these ocular manifestations and early diagnosis has the significant potential to prevent, minimize and treat the common and disabling complications due to Dengue haemorrhagic fever & dengue shock syndrome.

CONCLUSION

There is a resurgence of dengue fever affecting all age groups, more commonly the younger age group in the recent times. The prognosis for the ophthalmic manifestations in dengue fever is good with an improved visual acuity and resolution of ocular signs in most patients. Thus a relevant ophthalmological evaluation must be stressed in every patient afflicted with dengue fever in order to detect these complications at the right time and to avoid any residual impairment of vision.

REFERENCES

1. Pande JN, Kabra SK. Dengue hemorrhagic fever and shock syndrome. Natl Med J India. 1996; 9(6): 256-8.
2. World Health Organization Key issues in dengue vector control towards the operationalisation of a global strategy: report of consultation. (CTD/FIL(Den)/IC 96.1). Geneva. Organization. 1995.
3. Hussian I, Afzal F, Shabbir A, Adil A,Zahid A, Tayyib M. Ophthalmic manifestation of Dengue fever. Ophthalmology update 2012;10:93-6.
4. Cohen SN, Halstead SB. Shock associated with dengue infection. J Paediatr 1966; 68(3): 448-55.
5. Halstead SB. The XXth century dengue pandemic: need for surveillance and res. World Health Stat Q 1992; 45 (2-3): 292-8.
6. Cruz-Villegas V, Berrocal AM, Davis JL. Bilateral choroidal effusions associated with dengue fever. Retina 2003;23:576–8.
7. Harpreet K Kapoor; SaloniBhai et al. Ocular manifestations of dengue fever in East Indian epidemic.Can J Opthalmol 2006;41:741-6.
8. National Vector Borne Disease Control Programme. Dengue Cases and Deaths in the Country Since 2008. Available at: http://nvbdcp.gov.in/den-cd.html (last accessed on November 4, 2012).
9. Lim WK, Mathur R et al. Ocular manifestation of dengue fever. Ophthalmology 2004:111:2057-64.
10. Haritoglou C, Scholz F, Bialasiewicz A, Klauss V. [Ocular manifestation in dengue fever]. Ophthalmologe 2000 Jun;97(6):433-6.
11. Kapoor HK, Bhai S, John M, Xavier J. Ocular manifestations of dengue fever in an East Indian epidemic. Can J Ophthalmol 2006;41:741–6.
12. Agarwal R, Jain. K, Manoher JM. Ocular manifestations of dengue hemorrhagic fever and its relation to platelet count. IJSR 2017;6:39-41.