ORIGINAL RESEARCH PAPER

Volume-7 | Issue-12 | December-2018 | PRINT ISSN No 2277 - 8179

INTERNATIONAL JOURNAL OF SCIENTIFIC RESEARCH

CORRELATION OF CAROTID COLOUR DOPPLER AND MRI BRAIN IN PATIENTS SUFFERING FROM CEREBROVASCULAR DISEASE

Radiodiagnosis

Dr. Hiral Hapani* Assistant Professor, Department of Radiodiagnosis,PDU Medical College and Civil Hospital, Rajkot-360001, Gujarat, India *Corresponding Author

Dr. Anjana Trivedi Professor and Head of Department, Department of Radiodiagnosis,PDU Medical College and Civil Hospital, Rajkot-360001, Gujarat, India

Dr. Bhargav Patel 2nd Year Resident,Department of Radiodiagnosis,PDU Medical College and Civil Hospital, Rajkot-360001, Gujarat, India

ABSTRACT

The present study was conducted with an objective to find the correlation between carotid doppler suggesting plaques and stenosis and MRI of those patients suggesting arterial ischemia/infarction. 50 patients which were diagnosed as having acute cerebral ischemia on MRI brain were analysed with carotid Doppler in gray scale, colour Doppler and then spectral waveform and the result was obtained by correlating the findings of both the investigations. Carotid Doppler is an important non invasive diagnostic tool which can be used for screening in asymptomatic patients who have risk of cerebrovascular events.

KEYWORDS

Colour Doppler, MRI, Cerebrovascular Stroke, carotid

INTRODUCTION:

Carotid artery atherosclerosis is a major cause of disabling stroke[1]. and it is thought to be the predominant etiology of stroke in the Western countries[2]. Stroke is the third leading cause of death and the primary cause of disability in the world. "Stroke" is clinical event which responsible for sudden onset of neurological deficit.

Imaging modalities available for the diagnosis are MRI, Contrast enhanced CT, carotid doppler for imaging of atherosclerotic plaques in carotid artery and angiography. More recently, imaging studies have suggested plaque composition as an independent risk factor for ischemic stroke[3].

MRI imaging techniques have permitted serial monitoring of atherosclerotic disease evolution and the identification of intraplaque risk factors for accelerated progresion[4]. This study was conducted with an objective to find the correlation between carotid doppler suggesting plaques and stenosis and MRI of those patients suggesting arterial ischemia/ infarction.

According to SRU (Society of radiologists in ultrasound) consensus for diagnosis and stratification of ICA stenosis recommendations have been given which are as follows:

Normal: ICA PSV is <125 cm/sec and no plaque and intimal thickening visible sonographically

<50 % Stenosis: ICA PSV is <125 cm /sec and intimal thickening is visible
50 -69 % stenosis: ICA PSV is 125-230 cm/sec and plaque is visible sonographically

>70% stenosis but less then near total occlusion: ICA PSV >230 cm/sec and visible plaque and luminal narrowing

Near occlusion of ICA: velocities are not used here and luminal narrowing is the only criteria that is used

Total occlusion of ICA: No detectable patent lumen, there may be increased in velocity in contralateral ICA

Sonographic characteristics of the plaques were described using the modified G-W classification[11,12]: type 1 – uniformly anechoic or hypoechoic; type 2 – predominantly (>50%) hypoechoic; type 3 – predominantly (>50%) hyperechoic; type 4 – uniformly hyperechoic; and type 5 – uniformly echogenic with posterior shadowing (the so-called calcified plaque).

OBJECTIVES:

The present study was conducted with an objective to find the correlation between carotid Doppler suggesting plaques and stenosis and MRI of those patients suggesting arterial ischemia/infarction. So that by correlating the findings of both investigations, it can be made out whether carotid doppler can be used as screening tool in patients with high risks of having ischemic strokes or not.

MATERIALS AND METHODS:

The present cross sectional study was conducted in P.D.U. Medical college, Rajkot between January to December, 2017 on 50 cases of acute arterial ischemia as suggested by MRI brain via studying T1W, T2W, Diffusion weighted, STIR Sequence. After stabilization of cases, by gray scale examination on Carotid Doppler was done for intimo-medial thickness, presence, location and characterization of plaques were assessed. Spectral Doppler analysis was done and measurements of Peak systolic velocity, end diastolic velocity were obtained.

Patients with symptoms of stroke and transient ischemic attack such as transient episodes of neurological dysfunction, sudden weakness or numbness, hemi-paresis, focal neurological deficits, sudden loss of consciousness, altered sensorium, aphasia, slurring of speech, diminution or loss of vision are included in the study.

Those cases that had evidance of hemorrhagic stroke are excluded from the study.

RESULTS:

Out of 50 patients of stroke, 64 % were males and 36 % were females. It was observed that 40 % patients were aged 60 years or above. The mean Intimo-medial thickness in stroke patients was 1.76 mm. Multiple plaques were seen in 48% of stroke patients.

TABLE 1: Intimo-medial thickness of Carotid Artery

Intimo- medial thickness	TIA* (%)	Stroke (%)
<1 mm	58	16
1-2 mm	27	58
2-3 mm	10	12
3-4 Mm	5	11
>4 mm	0	3
Total	100	100

*Transient Ischemic Attack

TABLE 2: Number and multiplicity of plaques

Plaques in patient	TIA* (%)	Stroke (%)
None	12(24)	8 (16)
1	30(60)	18 (36)
2	8(16)	24 (48)
Total	50(100)	50 (100)

*Transient Ischemic Attack

Internal Carotid Artery was the most common site of plaque in stroke patients (45.7%),

while it accounted for 26% of plaques in transient ischemic attack patients. Most of the plaques (78%) in Transient ischemic attack patients were smooth while in stroke patients, approximately 42% plaques were smooth surfaced. Irregular plaques were much more commonly seen in stroke patients (46.7% in stroke versus 16% in Transient ischemic attack). Ulcerated plaques were seen exclusively in stroke patients (10.3%). Majority of plaques in stroke patients (46.7%) caused 50-69% stenosis.

Type I was the most common type of plaque causing <50% stenosis while TYPE II was the most common type causing 50 or more stenosis. 14% of stroke patients had no stenosis on carotid doppler evaluation. 58% of patients had ipsi- lateral carotid stenosis, 28% had bilateral stenosis. While 80% of patients with <50 % stenosis had small infarct on MRI brain, just 27.2% of patients with >50% stenosis had small infarct. 72.7% of patients with >50% stenosis had large infarct on MRI brain while only 20% of patients with <50% stenosis had large infarct.

TABLE 3: Type of plaques v/s degree of stenosis in ischemic attack patients

% of stenosis	Type of plaques					Total
	1	2	3	4	5	
<50	3 (9.3)	1(3.1)	6 (18.7)	5 (15.6)	17 (53.1)	32
50-69	1 (8.3)	5 (41.6)	1(8.3)	1(8.3)	4 (33.4)	12
70 OR MORE	-	-	-	-	-	-
NEAR OCCLUSION	-	-	-	-	-	-
TOTAL OCCLUSION	-	-	-	-	-	-

TABLE 4: Correlation of percentage stenosis with size of infarct

% of stenosis	Infarct size		Total
	Small	Large	
< 50 % Stenosis	16(80 %)	4(20 %)	20
> 50 % Stenosis	6(27.2 %)	16(72.7 %)	22

TABLE 5: Type of plaques v/s degree of stenosis in stroke patients

% of Stenosis	Type of plaques					Total
	1	2	3	4	5	
<50	7(38.8)	2 (11.1)	5 (27.7)	2 (11.1)	2 (11.1)	18
50-69	5 (17.8)	12 (42.8)	3 (10.7)	2 (7.1)	4 (14.2)	28
70 OR MORE		6 (42.8)	5 (35.7)	3 (21.4)	2 (14.2)	14
NEAR OCCLUSION		2 (100)				2
TOTAL OCCLUSION	2 (100)					2

Normal Left common carotid artery color Doppler waveform in a 45-year-old male

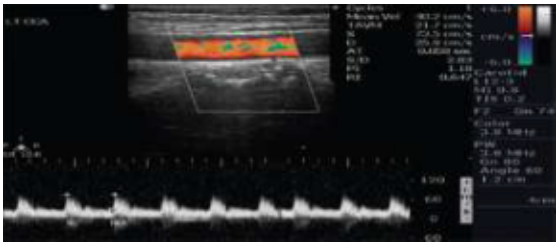

Calcific plaque at common carotid artery bifurcation in a 79-year-old female.

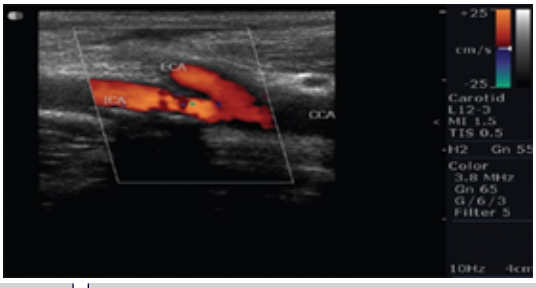

Complete occlusion of left internal carotid artery with hypoechoic plaque in a 72-year-old male.

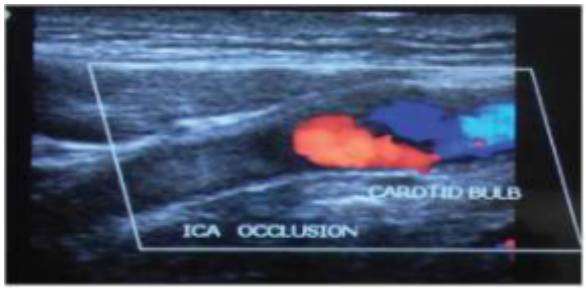

DISCUSSION:

Intimo-medial thickness is considered as a marker for atherosclerotic disease not only in the cerebrovascular system[5]. It is believed that thickening of the intimo-medial complex greater than 0.8 mm is abnormal and may represent the earliest changes of atherosclerotic disease. The mean intimo-medial thickness in TIA and stroke patients was 1.1 mm and 1.7 mm respectively. In this study 68% and 81% of patients showed evidence of plaques in transient ischemic attack and stroke group of patients respectively.

The multiplicity of plaques was approximately thrice in stroke patients as compared to transient ischemic attack patients. Most of the plaques (78%) in transient ischemic attack patients were smooth surfaced while in stroke patients, irregular surfaced and ulcerated plaques together accounted for 58% of plaques.

Geroulakos et al[6] classified ultrasonographic carotid plaques in 5 different types of stenosis, and correlated plaque type with symptomatology, showing the predominance of echolucent plaques in symptomatic patients with stenosis > 70 percent. Lusby et al[7] showed that "haemorrhage in carotid atheromatous plaques plays a unique and major role in the development of cerebrovascular disease".. Seeger et al[8] reported that the composition of plaques from symptomatic patients is significantly different from those asymptomatic. The former contains more total lipid and cholesterol, and less collagen and calcium.

Majority of the plaques (78.7%) caused <50% stenosis in transient ischemic attack patients while the majority (45.7%) caused 50-69% stenosis in stroke patients. This is because intra-plaque haemorrhage (IPH) and ulceration are considered unstable and lead to abrupt increases in plaque size. So larger plaques (stenosis greater than 70%) were mostly Types 1 and 2 and typically found in symptomatic patients.

In this study 80% of patients with <50 % stenosis had small infarct on MRI brain, while only 20% of these patients had large infarct. It was seen that 72.7% of patients with >50% stenosis had large infarct on MRI brain, just 27.2% of these patients had small infarct. Singh et at[9] in an interesting paper describing structural MRI findings in 98 asymptomatic carotid arteries with moderate stenosis (50-70%) and subsequent one year evolution to symptomatic status: 36 (36.7%) had IPH on NMR (Nuclearmagnetic resonance), with 6 cerebrovascular events, ie 16%, (2 stroke and 4 AIT) related to carotid IPH showed, compared to the absence of events in the carotid without IPH. Their statistical analyzes confirmed that the detection of IPH on NMR was associated with an increased risk of cerebrovascular events. In another relevant work involving MRI, Cheung et al[10] investigated the presence of IPH in the carotid arteries of 217 patients who had symptomatic stenosis less than 50%. IPH was detected in 13% related to the hemisphere ipsilateral symptoms and 7% contralateral.

CONCLUSION:

This study has shown that Carotid Doppler is an important non invasive diagnostic tool for screening in high risk asymptomatic patients, with history of cerebrovascular events and for determining treatment protocol. Thus it should be used as a first line screening investigation in these patients.

REFERENCES

1. Whitlow PL, Lylyk P; Londero H Mendiz, OA; Mathias K, Jaeger H, Parodi, J, Schönholz C, Milei, J. Carotid Artery Stenting Protected With an Emboli Containment System. Stroke. 2002;33:1308-1314.
2. The global burden of disease: 2004 update. World Health Organization (WHO)Press;

2008. http://www.nhlbi.nih.gov/health/healthtopics/ topics/catd/ [Online]
3. Golledge J, Greenhalgh RM, Davies AH. The symptomatic carotid plaque. Stroke 2000;31:774e81.
4. Watanabe Y, Nagayama M. MR plaque imaging of the carotid artery. Neuroradiology. 2010;52(4):253-74.
5. Latika Sibal, Sharad C Agarwal, Philip D Home. Carotid intima-media thickness as a surrogate marker of cardiovascular disease in diabetes. Diabetes, Metabolic Syndrome and Obesity: Targets and Therapy 2011:4 23–34.
6. Geroulakos G, Ramaswami G, Nicolaides A. Characterization of symptomatic and asymptomatic carotid plaques using high-resolution real-time ultrasonography. Br J Surg 1993; 80: 1274-77.
7. Lusby RJ, Ferrel LD, Ehrenfeld WK, Stoney J, Wylie EJ: Carotid plaque hemorrhage. Its role in the production of cerebral ischemia. Arch Surg 1982;117:1479-88.
8. Grant E et al. Carotid Artery Stenosis: Gray Scale and Doppler US.Diagnosis-Society of Radiologists in Ultrasound Consensus Conference Radiology 2003; 229-340-6.
9. Singh N, Moody AR, Gladstone DJ, et al. Moderate Carotid Artery Stenosis: MR Imaging–depicted Intraplaque Hemorrhage Predicts Risk of Cerebrovascular Ischemic Events in Asymptomatic Men. Radiology 2009; 252:((2)502-8.
10. Cheung H, Moody A, Singh N et al. Late Stage Complicated Atheroma in Low-Grade Stenotic Carotid Disease: MR Imaging Depiction—Prevalence and Risk Factors. Radiology 2011:260 (3) 841-7.
11. Gray-Weale A.C., Graham J.C., Burnett J.R., Byrne K., Lusby R.J. Carotid artery atheroma: comparison of preoperative B-mode ultrasound appearance with carotid endarterectomy specimen pathology. J Cardiovasc Surg. 1988;29:676–681.
12. Geroulakos G., Ramaswami G., Nicolaides A., James K., Labropoulos N., Belcaro G. Characterization of symptomatic and asymptomatic carotid plaques using high resolution real-time ultrasonography. Br J Surg. 1993;80:1274–1277