ORIGINAL RESEARCH PAPER
Volume-7 | Issue-5 | May-2018 | PRINT ISSN No 2277 - 8179
INTERNATIONAL JOURNAL OF SCIENTIFIC RESEARCH

CROSS SECTIONAL IMAGING OF CONGENITAL ABNORMALITIES OF PULMONARY VENOUS DRAINAGE

Radiodiagnosis

Yameen Majid Wani Lecturer Department of Radiodiagnosis and Imaging , Govt Medical College Srinagar

Shabir Ahmad Bhat* Associate Professor Department of Radiodiagnosis and Imaging , Govt Medical College Srinagar *Corresponding Author

Mir Abida Department of Physiology Govt Medical College Srinagar

INTRODUCTION:

Anomalous pulmonary venous drainage (APVR) is a congenital heart disease characterized by abnormal drainage of the pulmonary veins into the systemic circulation resulting in mixing of systemic and pulmonary venous blood in the right atrium. The abnormalities vary in severity from an incidental findings without any clinical symptoms to quite severe condition which if left untreated carries significant mortality. Echocardiography can give a clue to this diagnosis, however the definitive diagnosis often cannot be given by echocardiography due to poor acoustic window. In such situations cross sectional imaging like magnetic resonance (MR) imaging and computed tomography (CT) is usually used to as an alternative to conventional angiography and cardiac catheterization. Many neonates with APVR also require cross sectional imaging for complete anatomic delineation of the defect, no clarity on the type of TAPVC on echocardiography and associated congenital cardiac anomalies. CT may be particularly advantageous in critically ill neonates with obstructive TAPVR.

ANOMALIES OF PULMONARY VENOUS DRAINAGE

The common abnormalities of pulmonary venous drainage include total anomalous pulmonary venous return and partial anomalous pulmonary venous return.

Total Anomalous Pulmonary Venous Return -TAPVR

TAPVR is a condition in which all four pulmonary veins aberrantly drain, directly or indirectly, into the systemic circulation, through any of the tributaries of the Sinus venosus (Superior vena cava, inferior vena cava, coronary sinus, azygos vein, portal vein, ductus venosus or hepatic veins). It is further divided on the basis of location of drainage into supracardiac, cardiac, infracardiac, and mixed types.

Supracardiac TAPVR

is most common type, where all the pulmonary veins drain into superior vena cavae via a horizontal confluence posterior to the left atrium which then forms an ascending vertical vein behind the left atrial appendage (Fig 1). The vertical vein then cources upwards to drain into the brachiocephalic vein . The distal end of brachiocephalic vein may at times be narrowed leading to obstruction . As a result of the anomalous drainage the SVC and right heart is dilated due to the volume overload. The only source of flow to the left side of heart is a patenet foramen ovale or a atrial septal defect, out of the two one is always present

Cardiac TAPVR is another type of TAPVR whereby the pulmonary confluence drains into right atrium via coronary sinus to right SVC, azygous vein or direct drainage to right atrium

Infracardiac TAPVR is the third type of TAPVR whereby the pulmonary venous confluence drains via a descending vein to the portal vein (Fig 2). The descending vein traverses the diaphragm via the esophageal hiatus. Other forms of infracardiac TAPVR include drainage into ductus venosus, hepatic veins, or inferior vena cava. Infracardiac PAPVC usually causes significant clinical symptoms due to quite high association of obstruction (>90%)

Mixed TAPVR is last type where patients can have variable and at times complex combinations of anomalous pulmonary drainage

PARTIAL ANOMALOUS PULMONARY VENOUS RETURN (PAPVR)

Occurs when one or more, but not all, of the pulmonary veins aberrantly drain into the systemic circulation via the superior vena cava, inferior vena cava or right atrium. PAPVR is further classified into-

Supracardiac PAPVR , which is the commonest where some pulmonary veins drain into the right superior vena cava, left superior vena cava, or their tributaries. The most common is drainage of right pulmonary vein to the SVC

Cardiac PAPVR the pulmonary veins connect directly to the right heart via coronary sinus.

Infracardiac PAPVR the common pulmonary vein travels down anterior to the esophagus through the diaphragm to connect to the IVC , which is termed as Schmittar syndrome. Scimitar syndrome may be associated with hypoplasia of the right lung and right pulmonary artery hypoplasia

Most cases of PAPVC except are detected in adult and are usually asymptomatic



Fig 1 Supracardiac TAPVR- Pulmonary veins form an anomalous common venous confluence, just superior to the left atrium which in turn leads to an ascending left vertical vein drains into the left innominate vein which in turn joins the SVC. Both the innominate vein andSVCaredilated

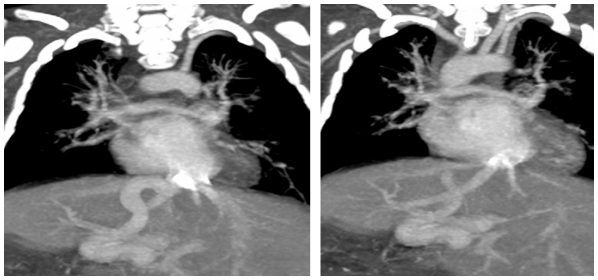

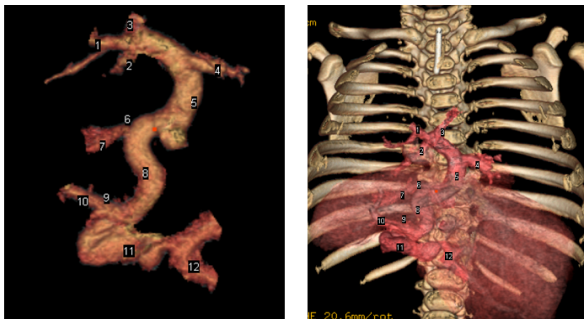

Fig 2 Infracardiac TAPVR Right and left sided pulmonary veins form a common

venous confluence continuing as a midline vertical vein, posterior to the left sided atrium and drains into right sided portal vein

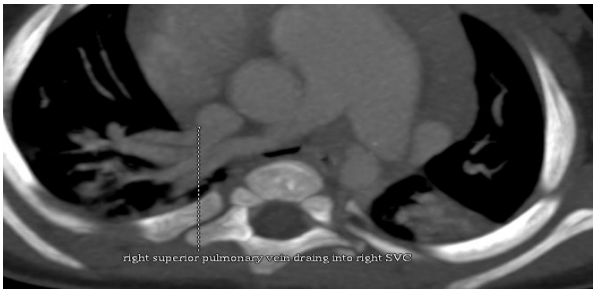

Fig 3: Supracardiac PAPVR Right superior pulmonary vein drains into the right SVC.