Volume : 5 | Issue : 3 | March 2016 • ISSN No 2277 - 8179 | IF : 3.508 | IC Value : 69.48

Research Paper

Cross-Sectional Prevalence Study of Intervertebral Disc Degeneration And It's Relation with Age, Obesity and Back Pain.

Medical Science

KEYWORDS : : MRI spine, intervertebral disc, herniation, bulge

Dr. Harsh vardhan — Assistant Professor,Department of Radiodiagnosis and Modern imaging, Government new medical college and hospital kota, rajasthan (india) 324010

Dr Nidhi Agrawal — Assistant Professor 2Department of Pathology, Government new medical college and hospital kota, Rajasthan (india) 324010

ABSTRACT

The prevalence of degenerative discs (DD) in 59 male; 41 female patients belong to rural population having mean age of 48.29 years; mean BMI (Body Mass Index) 22.196 kg/ m2 associated with pain, radiculopathies and neurological deficit presenting to the various in & out patient departments of Medical College. Patients with sedentary life style had maximum number of degenerative disc pathologies; while had ambulatory life style had maximum percentage of infective/inflammatory disc pathologies. 98.3 % male patients had degenerative lesions while 92.5 % of female patient had degenerative changes. Age group 61-70 years to be maximum involved. In the lumbar region maximum changes were seen at L5-S1 level (25.7 %); cervical region at C5-C6 level (12.2 %) and at thoracic region at D12-L1 level (24.2 %).

INTRODUCTION

The spinal column is a complex anatomical structure which is composed of vertebrae, intervertebral discs and ligaments. All these components undergo degenerative changes and morphologic alterations during life[1]. The intervertebral discs constitute the principal connections between the vertebrae and have two main functions: to serve as shock absorbers and to allow movement of the spinal column[2].. Movement at a single disc level is limited, but all of the vertebrae and discs combined allow for a significant range of motion[3].

There are many imaging modalities for assessing intervertebral discs. On plain X-ray films, soft tissues of the intervertebral discs are not differentiated. Plain X-ray has a limited role in the assessment of disc degeneration, since early degenerative changes within the disc cannot be detected (unless it contains foci of calcifications or ossifications) [4,5].

But the important drawbacks of this method are the relatively high dose of ionizing radiation and intrinsically limited soft tissue contrast resolution between different soft tissues.

Intradiscal structure can only be grossly evaluated and its sensitivity at the early phases of disc degeneration is poor[6].

MRI is the most sensitive imaging method for evaluating the intervertebral disc and has become the primary imaging modality for investigation of the spine[7]. In addition to the noninvasive nature of this modality, MRI provides excellent anatomic detail of the spine, superb soft tissue contrast discrimination and multiplanar imaging capability[7,8].

MATERIALS AND METHODOLOGY

100 patients (mean age 48.49 years. age range 13-85 years; 59 male 41 female) presenting to the various in & out patient departments of Medical College, with symptoms of discogenic pathologies were taken up for study.

Exclusion Criteria: -

- Patients having non-discogenic spinal pathologies.

Methodology: -

- Each patient's name, age, sex, occupation, habits, height & weight, spinal cord trauma, weight, & clinical symptoms were taken

MRI procedures:

Non-Contrast MRI examination were performed by using closed type Superconductive 1.5 Tesla MRI on every patient..

The following sequences were used: Sagittal T1, Sagittal T2, Axial T1, Axial T2, Coronal T1, STIR coronal & T2 Haste myelographic sequence

Prevalence rates of MRI findings were reported for each spinal level for discs as mentioned in Table 1.

Results:

- In my study, commonest age group presenting with discogenic pathologies were in 31 to 40 years (23 %) with female preponderance; while that in 11 to 20 years and 21 to 30 years had male preponderance. In my study male: female ratio was 1.43:1. Degenerative lesion was present in 98.3 % male, 92.5 % female.(table 1)

- Degeneration in discs were maximum in 60-70 years age (100%) group followed by 31 to 40 years age group (95 % and while no degenerative changes were seen in below 10 years age group. (table1)

- Patients with sedentary life style (55 patients) had maximum number of degenerative disc pathologies; while had ambulatory life style (45 patients) had maximum percentage of infective/inflammatory disc pathologies. In my study patients in BMI group 18-25 had maximum number of disc pathologies; while all obese patients (BMI > 25) had degenerative disc pathologies. Grade III changes were predominately occurs in mean BMI of 26.5.

DISCUSSION

My study cross-sectional prevalence study of disc degeneration in a rural working population and it's relation with age, obesity and back pain in 100 patients makes an attempt to show efficacy of MRI in diagnosing Disc pathologies.

SYMPTOMATOLOGY

In my study, the commonest presenting complain of patients were low back pain. Radiculopathies 56% and neurological deficit 14 % . Whereas, P. Kjaer et al study had shown low back pain to be 66 % 9 and Takatalo et al had shown 52 % in their studies[9].

AGE & SEX:

D Weishaupt et al study had shown in 40 -50 years age group maximum number of disc pathologies (39 %) occurred11. Takatalo et al revealed in 11-20 years age group discogenic pathologies were predominant in female patients in their

Volume : 5 | Issue : 3 | March 2016 • ISSN No 2277 - 8179 | IF : 3.508 | IC Value : 69.48

study[10,.]. My results were contradictory with those of the above mentioned authors.

In obese patients (BMI > 25 kg/m2) degenerative changes were common and occurred predominately at L4-L5 disc level . All my patients were symptomatic

Morio Matsumoto et al in their study concluded that degenerative changes were observed in approximately half of the asymptomatic subjects. They observed that patients with BMI > 25 had more number of degenerative disc pathologies as compared to those with BMI < 25[11].

My study also showed that in young age group (47 %) had increased number of discogenic pathologies as compared to middle age (21 %) and older people (32 %)).

M. Liuke et al in their study showed that BMI above 25 kg/m2 increases the risk of disc degeneration, with a stronger effect of high BMI at young age than in middle age[12,].

MANAGEMENT:

In my study out of 100 patients only 55 patients had to undergo operative treatment. Rest of the patients needed conservative management.

F aichner et al study concluded that magnetic resonance imaging may become the method of choice in the diagnosis of structural spinal cord diseases[13].

In 2 (3.6 %) cases surgeon had disagreement at the level of discectomy as there was a gap of 3 months between the MRI and surgery.

K. Halldin et al in their study showed that in 15% of the patients, the surgeon and radiologist's diagnosis differed.

The difference could probably be explained by shrinking or absorption of the disc herniation during the time between radiological examination and operation[14].

Clinical Implications

The study findings suggest that disc degeneration is determined BMI, age as well as life style. It can be concluded that MRI is an accurate, noninvasive means of evaluating disc, which can be performed on an outpatient basis. Normal and degenerated discs can be well differentiated by the different MRI signals. It is a highly sensitive imaging modality.

TABLE 1: :CLASSIFICATION OF DEGENERATIVE PATHOLOGIES ACCORDING TO INTERVERTEBRAL DISC LEVEL:

GROUP	DISC PATHOLOGIES		C3-C4	C4-C5	C5-C6	C6-C7	C7-D1	D3-D4	D4-D5	D5-D6	D6-D7	D7-D8	D8-D9	D9- D10	D10-D11	D11-D12	D12-L1	L1-L2	L2-L3	L3-L4	L4-L5	L5-S1	S1-S2
A	HERNIATION																						
		SUBARTICULAR	0	0	0	0	0	0	0	0	0	0	0	0	0	0	0	0	1	0	0	1	0
		EXTRAFORAMINAL	0	0	0	0	0	0	0	0	0	0	0	0	0	0	0	0	0	1	3	0	
		PARACENTRAL	0	0	2	1	1	0	0	2	0	0	0	0	0	0	1	1	3	3	7	5	0
B	PROTRUSION	PARACENTRAL	2	1	2	4	0	0	0	0	0	0	0	0	0	0	0	0	2	5	9	11	0
		POSTERIOR	3	5	11	8	2	0	0	1	0	1	2	1	1	3	1	0	7	6	11	10	1
C	BULGE	PARACENTRAL	1	2	4	2	0	0	0	0	0	0	0	0	1	1	1	1	5	10	9	9	
		POSTERIOR	6	10	13	14	1	2	0	0	2	0	0	0	0	1	2	2	5	9	12	4	0
		DIFFUSED	2	5	10	1	0	0	2	1	1	0	1	1	0	1	1	2	8	11	16	5	2
D	ANNULAR TEAR	RADIAL	1	3	3	1	1	0	0	0	0	0	0	0	0	0	1	1	2	7	10	5	
		TRANSVERSE	0	1	0	1	0	0	0	0	0	0	0	0	0	1	0	0	1	2	4	3	
		CONCENTRIC	0	0	0	0	0	0	0	0	0	0	0	0	0	0	0	1	1	2	2	3	
E	RUPTURE		0	0	1	0	0	0	0	0	0	2	0	0	0	1	2	0	1	0	1	0	0
F	MIGRATION		0	0	1	0	0	0	0	0	0	0	0	0	0	0	0	0	0	1	1	1	0
G	SEQUESTRATION		0	0	0	0	0	0	0	0	0	0	0	0	0	0	0	0	0	0	0	1	0
H	EXTRUSION		0	0	1	1	0	0	0	0	0	1	0	0	0	0	0	1	0	1	3	3	0

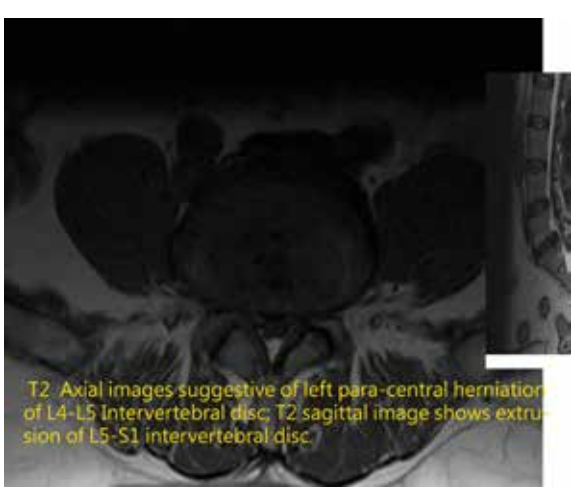

REFERENCES

1. Prescher A, Anatomy and pathology of the aging spine. European Journal Radiology , 1998;27:181–195.
2. Inoue H, Takeda T. Three-dimensional observation of collagen framework of lumbar intervertebral discs, Acta Orthopaedica Scandinavica, 1975; 46:949–956.
3. Provencher, Matthew T. MD; Abdu, William A. MD. Historical Perspective: Giovanni Alfonso Borelli: "Father of spinal Biomechanics" Spine January 2000, Volume 25 - Issue 1 - 131.
4. Herzog, RJ. The radiologic assessment for a lumbar disc herniation. Spine 1996, 21:19S–38S.
5. Hampton AO & Robinson JM. The roentgenographic demonstration of rupture of the intervertebral disc into the spinal canal after the injection of lipodol. American Journal Roentgenol, 1936 :782–803.
6. Haughton V. Medical imaging of intervertebral disc degeneration. Spine, 2004: 29:2751–2756.
7. Parizel PM, Van Goethem JW, Ozsarlak O, De Schepper AM. Pattern recognition of degenerative disorders in the lumbar spine. Guidelines to MR image interpretation. Journal Belge de Radiologie - Belgisch Tijdschrift voor Radiologica, 2003: 86:222–226.
8. Saifuddin A, McSweeney E, Lehovsky J. Development of lumbar high intensity zone on axial loaded magnetic resonance imaging. Spine 2003; 28:E449–E451.
9. Kjaer P. Low back pain in relation to lumbar spine abnormalities as identi-

fied by magnetic resonance imaging. Faculty of Health Sciences, University of Southern Denmark. Ref Type: Thesis/Dissertation- 2004; 40-110.

10. Stadnik TW, Lee RR, Coen HL, Neirynck EC, Buisseret TS, Osteaux MJ. Annular tears and disk herniation: prevalence and contrast enhancement on MR images in the absence of low back pain or sciatica. Radiology 1998 ; 206:49–55
11. 11 Jarvik JJ, Hollingworth W, Heagerty P et al. The Longitudinal Assessment of Imaging and Disability of the Back , Study: baseline data. Spine 2001; 26:1158-66.
12. 12 .Modic MT, Masaryk TJ, Ross JS, Carter JR. Imaging of degenerative disk disease. Radiology, 1988; 168:177–186.
13. 13. F aichner, w poewe, w rogalsky, k wallnofer, j willeit f gerstenbrand. Magnetic resonance imaging in the diagnosis of spinal cord diseases Journal of Neurology, Neurosurgery and Psychiatry 1985;48: 1220-1229.
14. 14. K. Halldin , B. Lind, K. Rönnberg, J. Göthlin, G. Gadeholt-Göthlin, B. Zoëga and H. Brisby. Three-dimensional radiological classification of lumbar disc herniation in relation to surgical outcome, International Orthopaedics Springer-Verlag 2008 10.100-107.