ORIGINAL RESEARCH PAPER

Volume-8 | Issue-2 | February-2019 | PRINT ISSN No 2277 - 8179

INTERNATIONAL JOURNAL OF SCIENTIFIC RESEARCH

# CROUZON CRANIOFACIAL DYSOSTOSIS IN TWO SIBLINGS: A RARITY

Paediatrics

**Sadaf Choudhary*** Post-Graduate student, D.Y.Patil Medical College, Hospital & Research Centre, Nerul, Navi Mumbai* Corresponding Author

**Anand Sude** Associate Professor, D.Y.Patil Medical College, Hospital & Research Centre, Nerul, Navi Mumbai

**Keya Lahiri** Professor, D.Y.Patil Medical College, Hospital & Research Centre, Nerul, Navi Mumbai

## ABSTRACT

Craniofacial dysostosis is an autosomal dominant condition with a prevalence rate of 15% in one million newborns and 4.8% amongst craniosynostosis. It is caused by the mutation in the Fibroblast growth factor receptor 2 (FGFR-2) gene. We present a case of crouzon syndrome in two siblings aged 6 and 4 years of age.

The older sibling, born of 3rd degree consanguineous marriage presented with complains of abnormal shape of the head since birth with decreased vision noticed one year back. Both the siblings had cranial and facial dysmorphism. On examination, both were stunted with tall forehead, frontal bossing, proptosis, hypertelorism, depressed nasal bridge, and mandibular prognathism. Ophthalmic evaluation of the elder child was suggestive of strabismus, bilateral optic atrophy with refractory error and shallow orbits. Intraoral examination revealed a high arched palate. Younger sibling showed bilateral chronic papilloedema. Computerized tomography of both patients demonstrated craniosynostosis. MRI orbit of the younger sibling denoted intracranial hypertension secondary to craniosynostosis.

## KEYWORDS

Craniofacial dysostosis, Crouzon syndrome, Fibroblast growth factor.

### 1. INTRODUCTION:

Crouzon syndrome was first described by a French neurosurgeon, Octave Crouzon, in 1912. [1] It is a rare genetic disorder and is transmitted as an autosomal dominant genetic condition. Crouzon syndrome is caused by mutation in the fibroblast growth factor receptor 2 (FGFR2) genes.[2]The disease is characterized by premature synostosis of coronal and sagittal sutures, which begins in the first year of life.[3] Features of the condition include craniosynostosis, midfacial hypoplasia, maxillary retrusion, hypertelorism, and shallow orbits, which give rise to ocular proptosis.[4] Intraoral manifestations include man-dibular prognathism, overcrowding of upper and lower teeth, and V-shaped maxillary dental arch.[1] Crouzon syndrome occurs in approximately 1 in 25,000 births worldwide.[5] Crouzon syndrome makes up approximately 4.8% of all cases of craniosynostoses.[6] No known race or sex predilection exists.[3] The differential diagnosis of Crouzon syndrome includes simple craniosynostosis as well as Apert syndrome, Carpenter syndrome, Saethre-Chotzen syndrome, and Pfeiffer syndrome.[7]

### 2. Case Report:

A 6 year old boy born of 3rd degree consanguineous marriage, hailing from Maharashtra, India presented to the paediatric department with complains of abnormal shape of the head noticed by parents when the child was one year of age. He also complained of decreased vision in the right eye since 5 years of age which was progressive. Both the patient and his younger 4 year old sibling had cranial and facial dysmorphic features. There was no history of convulsions, motor or sensory deficits, cranial nerve involvement in both the siblings. Neither did they have history suggestive of increased intracranial tension. Birth and developmental history of both patients was normal. The siblings belonged to lower class and were immunized till 9 months of age.

On examination, the older sibling had grade II protein energy malnutrition with grade II stunting, while the younger child had grade I protein energy malnutrition with grade II stunting. Head to toe examination of both children revealed tall forehead, frontal bossing, proptosis, hypertelorism, depressed nasal bridge, and mandibular prognathism.

Ophthalmic evaluation of the elder child was suggestive of strabismus, bilateral optic atrophy with refractory error and shallow orbits. Intraoral examination revealed a high arched palate.



*Figure 1, 2- Anterior & lateral profile of the older child*

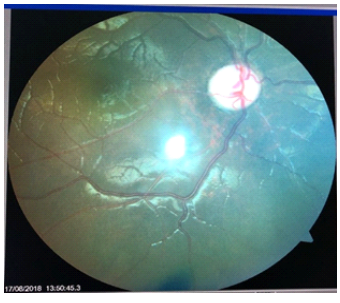

*Figure 3- Fundus examination of older child depicting Optic atrophy.*

Ophthalmic examination of the younger sibling showed chronic papilloedema. Computerized tomography of the skull demonstrated craniosynostosis. MRI orbit of the younger sibling denoted intracranial hypertension secondary to craniosynostosis. On the basis of these clinical and radiological findings, a diagnosis of Crouzon Syndrome was made. Other conditions with craniosynostosis viz. Apert's Syndrome, Carpenter Syndrome were ruled out.



*Figure 4, 5- Anterior and lateral profile of younger sibling*

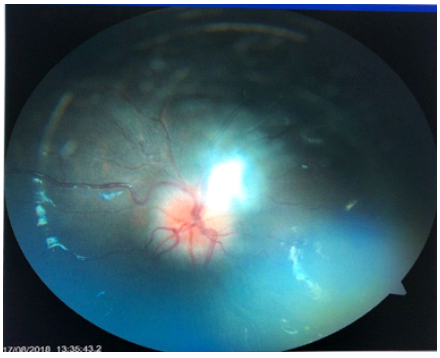

*Figure-6: Fundus examination of younger child showed chronic papilloedema*

## 3. DISCUSSION:

The genetic defect results from mutation in the fibroblast growth factor receptor 2 (FGFR-2) which results in the early fusion of the skull bones during the development of the foetus. Craniosynostosis commonly begins during the first year of life and is usually complete by 2–3 years of age. In our patient, the features started developing from the birth gradually given by history of the parents. Ocular proptosis, a feature occurring in 100% of the cases, is secondary to shallow orbits. In our patient all the features of craniosynostosis as well as feature of ocular proptosis was seen. With the advent of molecular technologies, the gene for Crouzon syndrome could be localized to the FGFR2 gene, at the chromosomal locus 10q25.3-q26, and more than 30 different mutations within the gene have been documented in separate families.[8] Hypertelorism was a universal finding in the affected individuals and is thought to arise due to a decrease in growth of the sphenozygomatic and sphenotemporal sutures[4] and the presence of mental retardation is rare in these children.[11]

## 4. CONCLUSION:

The phenotypic features of Crouzon syndrome may be absent at birth and may evolve gradually during the first few years of life.[9, 10] Genetic counselling is paramount as it would have prevented the birth of another affected sibling.

## REFERENCES:


1. Crouzon LE. Dysostose cranio-faciale héréditaire. Bulletin de la Société des Médecins des Hôpitaux de Paris. 1912;33:545–555.
2. Fries PD, Katowitz JA. Congenital craniofacial anomalies of ophthalmic importance. Surv Ophthalmol. 1990 Sep-Oct;35(2):87–119. [PubMed]
3. Hlongwa P. Early orthodontic management of Crouzon syndrome: a case report. J Maxillofac Oral Surg. 2009 Mar;8(1):74–76. [PMC free article] [PubMed]
4. Kreiborg S. Crouzon syndrome. Scand J Plast Reconstr Surg. 1981;18(Suppl):1–198. [PubMed]
5. Cohen MM Jr. Craniosynostosis update 1987. Am J Med Genet (Suppl) 1988;4:99–148. [PubMed]
6. Gray TL, Casey T, Selva D, Anderson PJ, David DJ. Ophthalmic sequelae of Crouzon syndrome. Ophthalmology. 2005 Jun;112(6):1129–1134. [PubMed]
7. Regezi JA, Sciubba JJ. Oral pathology - clinical pathologic correlations. 4th ed. Philadelphia: W.B. Saunders; 1999. pp. 477–478.
8. Jeftha A, Stephen L, Morkel IA, Beighton P. Crouzonoder-moskeletal syndrome. J Clin Pediatr Dent. 2004 Winter;28(2):173–176. [PubMed]
9. Atkinson FR. Hereditary craniofacial dysostosis or Crouzon's syndrome disease. Med Press Circular. 1937;195:118–124.
10. Golabi M. Radiographic abnormalities of Crouzan syndrome. A survey of 23 cases. Proc Greenwood Genet Ctr. 1984;3:102.
11. Jarund M, Lauritzen C. Craniofacial dysostosis: airway obstruction and craniofacial surgery. Scand J Plast Reconstr Surg Hand Surg. 1996;30:275–279. [PubMed]