ORIGINAL RESEARCH PAPER
Volume-6 | Issue-10 | October-2017 | ISSN No 2277 - 8179 | IF : 4.176 | IC Value : 78.46
INTERNATIONAL JOURNAL OF SCIENTIFIC RESEARCH

CRYSTALLIZE TO DEFINITIZE CANCER.

Pathology

Dr. Hina Mehrotra	Pg student.ITS dental college,hospital and research centre. Greater Noida.
***Dr. Heena Sadiq**	Registrar .Department of oral pathology and microbiology.Indra Gandhi government dental college .Jammu *Corresponding Author
Dr Rubeena Anjum	Prof. and Hod. Department of Oral pathology and Microbiology .Indra Gandhi Government dental college.Jammu
Dr. Pragya Goyal	3rd year post graduate .Oral medicine diagnosis and radiology.DY Patil school of dentistry
Dr. Pooja Kasana	Private practioner.BDS,MDS(Department of oral pathology and microbiology).greater Noida
Dr. Shahid Masood shaikh	MDS. Consultant paediatric dentist.Masina hospital.Mumbai

ABSTRACT

AIM: To determine the pattern of the crystallization of cupric chloride for screening of OSCC and to find out the correlation, if any, between number of Transverse Form (TF) and clinical and histopathological grades of OSCC

Materials and Methods: Thirty three diagnosed patients of OSCC and 10 healthy individuals were selected. One drop of blood was mixed into 1 cc of distilled water at room temperature to give a final dilution of 6% hemolyzed blood. 0.1 to 0.2 cc of blood sample was then subjected to crystallization test by adding 10cc of 20% cupric chloride solution at room temperature.

Results: In healthy control group, the typical pattern was an eccentrically placed centre of gravity with needles arranged in radiating fashion, while in OSCC group, there was 'transverse form' (TF) formation. The sensitivity and specificity of this test was found to be 95% and 96%, respectively.The positive and negative predictive values were found to be 97.96% and 98.55%,
respectively. The mean TF frequency was found to be increasing from grade I (3.20 ± 1.5%) to grade II (653 ± 2.23%) and difference was statistically significant (P = 0.0001). However, there was no correlation between mean TF frequency and TNM stages of OSCC.

Conclusion: It is a simple, economical, reliable, test which is less time-consuming and less invasive screening procedure. It can be used for early detection of OSCC and also used to screen all cancer cases of OSCC. Early detection of cancer is possible even before biopsy in suspected cases. Biopsy should be advised in the positive cases.

KEYWORDS

Crystallization test, oral cancer, oral squamous cell carcinoma, screening test

INTRODUCTION: Cancer is an age old disease and oral squamous cell carcinoma being the 10th most common cancer in the world shows challenges in its diagnosis until it attains advanced stage[1].Pfeiffer in the year 1938 introduced a new method for cancer detection by mixing CuCl2 with blood of cancer patient[2].

The oral squamous cell carcinoma accounts for 3-5% of all the malignancies[1]. It arises from the oral epithelium which constitutes 90% of the oral cancer. Most of them are not diagnosed until they have attained at least the T2 stage. The failure of early diagnosis and its frequency to advance into its deadly stages contribute to its continued poor prognosis.[3] The mortality rate of cancer can be reduced tremendously if detected, diagnosed, and treated at early stages.(3)For its early detection we require a test which is simple, economical, reliable, less time-consuming, and less invasive.

After working on the phenomena of crystallization Kopaczewski in the year 1933 concluded that different patterns of crystallization are produced on different rates and amplitude by the molecular movements which are involved in the evaporation process both by organic and inorganic salts.[2]

Crystallization test using cupric chloride solution was first developed by Pfeiffer in the year 1938.The physical forces which maintain the integrity of the molecules and chemicals forms the basis of this test. The presence of malignancy is diagnosed with the presence of a hallmark sign of crystallization i.e 'transverse form' (TF) formation.[2]

The presence of different crystallization pattern in healthy and diseased individuals is due to the pivotal role of colloidal proteins in dilute solution of blood. The abnormal proteins exhibit changes in the position of amino and sulphydryl groups exhibiting its specific pattern in cancer.[2]

The present study was carried out in the oral malignancies which concluded that it is a simple, reliable, economical, time saving and less invasive diagnostic procedure which can also be used for mass screening program.

The present study was carried out to determine the efficacy of the crystallization test for screening of oral Squamous cell carcinoma (OSCC) and to find out the correlation, if any, between number of transverse forms in the clinical and histopathological grades of OSCC.

MATERIALS AND METHODS

Subject population:

The study was carried out in the Department of Oral Pathology and Microbiology at ITS Dental College, hospital and research centre, Greater Noida.[33] histopathologically diagnosed cases of OSCC and 10 cases of normal healthy patients were selected. Inclusion criteria for OSCC patients were that they should not have undergone any therapy for cancer treatment prior to this study. All cases were subjected to screening for systemic diseases by physicians. Appropriate investigations both imaging and biochemical were done to rule out any systemic disease in the suspected cases. All OSCC cases were free from any systemic disorders. Histopathological grading of OSCC was carried out by using Broaders grading system. AJCC system for lip and oral cavity cancer was used for TNM staging. As control group healthy individuals were taken. All the subjects were in age group of 20 years to 80 years, with mean age of 55 years. The peak age incidence was 5th decade of life.60% were males and 40% were females. The most affected site was tongue (7 cases), buccal mucosa (9 cases), floor of the mouth (6 cases), lips (5 cases), esophagus (4 cases) and alveolar ridge (2 cases).

Method for crystallization:

Blood sample was drawn by pricking the ring finger under complete aseptic condition. A blood drop was collected into 1 cc of doubled distilled water at room temperature to give it a final dilution of 6% hemolyzed blood. 0.1 to 0.2 cc of blood sample was then added to 10 cc of 20% cupric chloride solution in a calibrated test tube at room temperature. The mixture was immediately poured into the pre-warmed flat-bottom petri-dish.[3] petridishes were carefully prepared, one of which had $cucl^2$ alone, one mixed with the blood of the healthy individual and one with the OSCC patient.These were placed in the incubator at a temperature of 28°C to 32°C with the humidity of 35% to 55% in an isolated room.

Crystallization was allowed without any vibrational disturbances for 19 hrs. The pattern of crystallization was carefully studied through hand lens in day light. The presence of Transverse Forms was considered as positive for the crystallization test. The number of Transverse Forms was also counted for correlating them with histopathological grades and the clinical stages.

Results and observation:

The TNM classification was applied to classify clinical cases and histological grading was done according to Annoeroth et al.(1987)[4]

The cupric chloride solution alone showed thick textured crystals with needles arranged at an arbitrary angle. The needles either showed side branching in fan-shaped manner or lengthwise linear growth. As observed by Sabarth and Williams (1975) secondary and tertiary branches can also be seen. This pattern is called "muddle formation"[5].The control group exhibits single eccentric pattern with orderly arrangement of radiating crystals emanating from the centre towards the periphery. OSCC group showed a set off TF, which consists of transverse needles with wing- like formation on either or both sides. Secondary and tertiary branching was absent in TF. The needles of the central radiation failed to pierce through the TF.

Discussion:

Blood acts as a unique medium that reflects various biochemical changes occurring in the body because of malignancy. The components of the cell surface and enzymes involved in the metabolism of nucleic acids are shed within the blood circulation during malignancy. Thus blood can be used as a less invasive diagnostic tool because of the biochemical changes which occur in the blood due to malignancy.[6]Similar kind of molecular forces maintain the cohesion of molecules in the crystalline form, which are responsible for the peculiar pattern forming tendency in any particular crystalline substance.Thus malignancy in the body can be detected easily through the agency of physical forces which maintain the integrity of molecular structures and cohesion of chemical substances.[7]

The increased concentration of diamines and polyamines in the blood during malignancy are basically the intermediate products of the protein metabolism.[8] It is concluded in the earlier studies that the colloidal proteins in dilute solution of blood play a pivotal role in the formation of different crystallization pattern in health and diseased state. Thus, the proteins or degraded products of proteins i.e. polyamines and diamines may be responsible for a particular cancer-specific pattern in crystallization test i.e. TF.

In the present study, crystallization pattern obtained was quite similar to those reported by earlier workers. However, the variations such as presence of two or more centres of gravity with wing-like formations with or without blank spaces between 2 crystals were also observed which go in accordance with Sabarth and Williams (1975)[5]

In our study, side branches were seen arising from the central radiating needles that resembled TF. Examination with the help of magnifying lens was done which showed that these were side branching which arise from the central radiating crystals.

The present study showed positive predictive value in 88.5 % cases and 69.7% showed negative predictive value in oral squammous cell carcinoma cases.All the earlier studies showed more reliability than the present study. Pfeiffer E2 showed (91%), Gruner OC2 (96%), Quadeer7 (100%), Shaikh S (90%)8 and Gulati SP et al.9(92%)

Mean TFs were correlated well with the histopathological grade 1 and grade II, and the difference was found to be statistically significant. No correlation was found within the clinical stages and there is less previous data related to the present study thus comparison was not possible.Maximum number of TFs were reported in poorly defined oral squammous cell carcinoma which goes in correlation with the earlier studies[2,9]

In our study 26 cases out of 33 cases of OSCC showed positive result. [7] case exhibited negative results. As the crystallization test is based on the physical phenomena which makes it a highly sensitive procedure, shortcomings in the form of negative results are due to the failure in maintaining required physical conditions in such cases.

Thus, it is concluded from the present study that crystallization test is a simple, reliable, economical, less time-consuming, and less invasive screening test which can be used easily for the early detection of oral squammous cell carcinoma.This test can be applied at community level, especially for high-risk group patients, which will guide us to identify the potential candidates. These potential candidates can be further evaluated for oral cancer with more confirmatory tests.

Further studies are needed having large sample to establish the crystallization test to be more reliable as a screening tool for OSCC. We recommend that the research focuses on crystallization patterns in metabolic disorders where alterations in polyamines and di-amines are expected.

STATISTICAL ANALYSIS OF CRYSTALLIZATION TEST.

	OSCC(cucl)	OSCC(Biopsy)	CHI-SQUARE	P VALUE
POSITIVE	26	23	20.435	.001
NETGATIVE	7	10		
TOTAL	33	33		
PPV	88.5%			
NPV	69.7%			

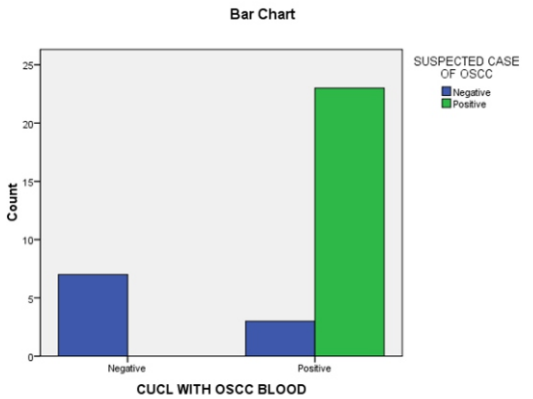

Figure legends:



fig1:cucl poweder



Fig 2:20g cucl mixed in 100ml water to make 20% cucl



Fig 3:poured into the disposable prewarmed (32degree) petridish



Fig 4: 1cc of 6% hemolysed blood mixed with the cucl



Fig 5:kept in the BOD incubator for 18-19hrs at 32degree



Fig 6: Observed with hand lens and then in stereomicroscope



18 male 15 female (age range- 20-60y)



weighing machine to measure cucl



cucl powder



beakers to measure water



BOD





Pure cucl pattern: Crystallization patterns of cupric chloride solution alone showing muddle formation



Crystallization patterns of cupric chloride solution in control group showing centre of gravity and radiating crystals



hand lens view of well OSCC



\

hand lens view of mod OSCC



hand lens view of poorOSCC



21,22,23: steromicroscope view of well differentiated OSCC,Moderately differentiated OSCC,poorly differentiated OSCC

REFERENCES

1. Sarode et al.Efficacy of crystallization test for screening of oral squamous cell carcinoma with clinico-pathological correlation. Indian J Dent Res 2013;24:464-7.
2. Gruner OC. Expericence with the Pfeffer crystallization method for diagnosis of cancer. J Canadian Med Assoc 1940;43:99-106.
3. Guggenheimer J, Verbin RS, Johnson JT, Horkowitz CA, Myers EN.Factors delaying the diagnosis of oral and orophyryngeal carcinomas. Cancer 1989;64:932-5.
4. classification
5. Sabarth E, Williams HN. Sensitive crystallization process as demonstration of formative forces in the blood. 2nd ed. Spring Valley, New York: Anthroposophic Press; 1975.
6. Burkhardt A. Advanced method in the evaluation of premalignant lesions and carcinomas of the oral mucosa. J Oral Pathol 1985;14:751- 78.
7. Quadeer A. New approach for detection of malignancy by crystallization test. Ph.D. thesis for (medicine) degree in Anatomy, Nagpur University, 1988.
8. Savory J, Shipe JR. Serum and urine polyamines in cancer. Ann Clin Lab Sci 1975;5:110-4.
9. Gulati SP, Sachdeva OP, Sachdeva A, Adlakha RP, Kakkar V. Crystallization test for detection of head nad neck cancer. ORL J Otorhinolaryngol Relat Spec 1994;56:283-6.