ORIGINAL RESEARCH PAPER

Volume-8 | Issue-7 | July - 2019 | PRINT ISSN No. 2277 - 8179

INTERNATIONAL JOURNAL OF SCIENTIFIC RESEARCH

CT EVALUATION OF NECK MASSES- A RETROSPECTIVE STUDY OF 100 CASES

Radiology

Dr. Saumil Desai* Associate Professor, Department of radiology, GCRI *Corresponding Author

Dr. Darshan Thummar 2nd year resident in radiology department, GCRI

ABSTRACT

BACKGROUND: Before advent of cross section imaging radiologists were of limited help in diagnosis of neck lesions, especially those involving deep neck spaces of suprahyoid neck (SHN).

AIM: Aim of our study is to characterise neck lesion by its morphological characteristics and enhancement pattern, outlining the extent, assessment of lymphadenopathy, look for criteria for operability and histopathological confirmation.

METHODS & MATERIALS: In this study 100 cases of neck masses were evaluated retrospectively in our department. The CT scan was performed prior to the treatment in all these patients. CT imaging feature includes location, size/diameter, degree & pattern of enhancement, intraluminal/exophytic, internal necrosis & hemorrhage, local spread, nodal & distant metastasis.

RESULTS: Out of 100 patients studied 27% were benign and 73% were malignant neck lesions, overall there was a male preponderance with a male to female ratio of 2.1:1. Benign lesion were common in the age group of 16-45 yrs. while malignant lesions were more common in the elderly age group of >45 years. Most of the benign (26%) and malignant lesions (81%) showed heterogeneous enhancement pattern. Bone invasion seen in 15% benign lesions, 19% of malignant lesions and cartilage invasion seen in 7% of malignant lesions. On correlation with HPE, among malignant lesions most common was Squamous cell carcinoma (48%) and among benign lesions most common was nonspecific inflammation. The sensitivity and specificity of study is 95.7% & 77.5% respectively, with positive predictive value and negative predictive value of 90.4% & 88.9% respectively and Accuracy is 90%.

KEYWORDS

Neck masses, Computed tomography, histopathological confirmation.

INTRODUCTION:

Imaging of the neck is always a challenge to general radiologist. It is very close and compact Arrangement of vital structures coupled with compact deposition of deep cervical fascia (DSF) Makes neck imaging difficult.

As technology advances in the use of CT its application in head and neck lesions has increased.

Multi slice CT scan is especially advantageous in defining the critical relationships of tumor and lymph node metastases and for functional imaging of the hypopharynx and larynx not only in the transverse plane but also in the coronal plane [1].

In every region of the head and neck multiplanar reconstructions are useful as additional planes [2]. The main reason for head and neck imaging is to evaluate the true extent of disease to best determine surgical and therapeutic options [3]. This process includes evaluation of the size, location, and extent of tumor infiltration into surrounding vascular and visceral structures. Second, nodal staging should be assessed in an effort to increase the number of abnormal nodes detected by physical examination and, more important, to precisely define their location by a standard classification system that can be understood and consistently applied by the radiologist, surgeon, radiation oncologist, and pathologist [4].

CT is fast, well tolerated, and readily available but has lower contrast resolution and requires iodinated contrast and ionizing radiations [5].

AIMS AND OBJECTIVES:

To assess role of contrast enhanced CT in evaluation of neck masses in respect of:

1. Characterization based on location, morphologicalcharacteristics and enhancement pattern.
2. Outlining the extent in terms of involvement of adjacent structures, vessels and possible lymphadenopathy.
3. Assessment of operability.
4. Surgical and Histopathological correlation whenever possible.

MATERIALS & METHODS

This study was conducted patients with clinically suspected neck lesions or patients who were diagnosed to have neck lesion on ultrasound and were referred to CT for further characterization from peripheral centers in Gujarat, neighboring states like Madhya Pradesh, Rajasthan and Maharashtra. All patients were scanned in the SIEMENS EMOTION 6, a six slice CT scanner. A total number of 100 patients were included in the study. The study was conducted in Department of Radiology of Gujarat Cancer Research Hospital attached to BJ medical college, Ahmedabad. A provisional diagnosis was made after CT scan and these findings were correlated with histopathology/ surgical findings as applicable.

STUDY DESIGN:

The study was an observational prospective study. Patients who were clinically evident & suspected to have neck masses were subjected to CT examination.

INCLUSION CRITERIA:

1. Patients with neck swelling.
2. Patients with symptoms pertaining to neck.
3. All patents with suspected neck mass.
4. Patients in whom a neck lesion was detected on ultrasound study.

EXCLUSION CRITERIA:

1. All patients with history of trauma, will be excluded from my study.
2. Patients with neck lesion but in whom contraindications to contrast administration were present such as contrast hypersensitivity or high renal parameters.

OBSERVATIONS AND RESULTS

Table 1: Age Distribution - Demographic Profile (n=100)

Age	Frequency (%)
1-15 years	10 (10%)
16-30 years	17 (17%)
31-45 years	24 (24%)
46-60 years	29 (29%)
> 60 years	20 (20%)
Total	100

In the present study maximum percentage of patients were in the age group of 46-60 years (29%) followed by 31-45 years (24%). Mean age is 44.5 years.

Table 2: TYPES OF LESION (N=100)

Type of lesion	No. of lesions	percentage
Benign	27	27%
Malignant	73	73%

In my study out of 100 patients, 73% cases were malignant and 27% cases were benign.1Most common age group for benign lesions was 16-45 years. The current study shows higher incidence of benign lesions among males with a male to female ratio of 1.45:1.

Table 3: Distribution Of The Lesions According To Neck Spaces (N=100)

Location	Benign (n=27)	Malignant (n=73)
Visceral space	5 (19%)	22 (30)%
Buccal space	0 (0%)	4 (5%)
Masticator space	2 (7%)	6 (8%)
Pharyngeal mucosal space	2 (7%)	14 (19%)
Posterior cervical space	3 (11%)	17 (23%)
Submandibular space	1 (4%)	3 (4%)
Suprasternal space of burns	1 (4%)	0 (0%)
Perivertebral space	4 (15%)	0 (0%)
Carotid space	2 (7%)	1 (1%)
Parapharyngeal space	2 (7%)	1 (1%)
Parotid space	5 (19%)	5 (7%)

Most common space to be involved in benign lesions was visceral space (19%) and parotid space (19%).

Most common space to be involved in malignant lesions was visceral space (30%) followed by posterior cervical space (23%).

Benign lesions showed solid type of lesions most commonly (45%), followed by cystic type (19%) of lesions.

Most of the in benign lesions showed either mild enhancement (26%) or heterogenous type (26%).

Most of the malignant lesions (80%) showed heterogenous type of enhancement pattern, followed by homogenous type of enhancement pattern There were 19% of malignant lesions (n=14) and 22% benign lesions (n=6) which showed calcification.

Bone erosion was seen in 19% and cartilage erosion was seen in &% of malignant lesion. 15% of benign lesion showed bone erosion that was in two cases of ameloblastoma, which was primary benign bone tumor caused lytic erosion of the mandible and two cases of angiofibroma.

Necrosis was most common feature in malignant lesions, 30% of malignant lesions showed necrosis & 7% of malignant lesions showed cystic areas. Cystic areas were most commonly seen in benign lesions, 33% of the benign lesions showed cystic areas.

There were 40& of malignant lesion which showed space invasion and only 8% of benign lesions showed adjacent space involvement.

Table 4: Nodal Status And Distant Metastasis (N=100)

Nodal Status	Benign(n=27)	Malignant(n=73)
None (0)	26 (96%)	21 (29%)
Metastatic LN (1)	0 (0%)	46 (63%)
lymphoma (2)	0 (0%)	6 (8%)
Inflammation (3)	1 (4%)	0 (0%)

There were total of 16 lymph node lesions with primary lymphoma or metastasis from outside the neck region with no primary in the neck. However in total metastatic nodes with primary in head and neck region and outside the neck region seen in 63% patients out of n=73.

Total 6 (9%) cases of lymphoma were seen.

Distant metastases was seen in 8 cases. Lung was the most common site for distant metastasis. Lung metastates seen in 4 cases.

In benign lesion nodes only one case of nonspecific inflammatory lymph node seen[6].

Table 5: Correlation Of Ct/hpe Diagnosis (N=100)

Diagnosis	Malignant	Benign
CT	69	31
Histopathological examination (HPE)	73	27

	HPE Diagnosis				
CT Diagnosis	**Malignant**	**Benign**	**Total**		
Malignant	66	3	69	95.7%	**sensitivity**
Benign	7	24	31	77.5%	**specificity**
Total	73	27	100		
	90.4%	88.9%	p value <0.0001		
	PPV	**NPV**			

$$\text{Accuracy} = \frac{\text{Number of true positive + Number of true negatives}}{\text{Number of true positive + False positive + Number of true negatives + False negative}}$$

$$= \frac{66+24}{66+3+24+7} = \frac{90}{100} = 0.90 = 9$$

Out of 100 cases studied with CT scan total lesions distinguished as benign 69 and malignant 31. After correlation with HPE malignant lesions turned out to be 73 and benign lesions were 27.

The sensitivity and specificity of study is 95.7% & 77.5% respectively, with positive predictive value and negative predictive value of 90.4% & 88.9% respectively. Accuracy is 90%.

DISCUSSION

The present clinical study was conducted in Department of Radio-diagnosis Gujarat cancer and research institute. During the period of august 2011 to October 2013 a total of 100 cases of neck lesions were evaluated at the Department of Radio-diagnosis on patients presenting with neck swelling or on patients in whom a neck mass was picked up on ultrasound study . Patients were evaluated with Multidetector CT (Siemens- somatom emotion 6) . Provisional diagnosis was given and was correlated with histopathological and postoperative diagnosis. The clinical, radiological & histopathological data of the patients have been presented in the following sections.

Demographic profile:

Out of 100 cases studied 27% were of benign etiology and 73% were of malignant etiology. There were more number of malignant lesions as ours is tertiary institute for cancer.

Most (59 %, out of n=27) of the benign lesions of the head and neck region was below the age of 45 years. Most common age range was 31-45 yrs.

In present study incidence of benign lesions was common among males with a male to female ratio of 1.45:1

In the present study male predominance of malignant lesions were detected with a male to female ratio of 2.5:1.

Regarding the CT characteristics of benign and malignant neck lesions:

Solid nature or soft tissue density of lesion was most common in the malignant lesions (88%), followed by solid cystic type which was seen in thyroid gland lesions and salivary gland tumors (5%) & lytic sclerotic type (5%) which was seen in bone tumors. One case of metastatic germ cell tumor showed cystic density.

Lytic sclerotic nature of lesions was seen in 3 cases of osteosarcoma and 1 case of burkitt's lymphoma of mandible.

Benign lesions showed solid type of characteristics most commonly (45%, of n=27), followed by cystic type (19%) and solid cystic (19%) type of lesions. 11% (n=3) of cases showed fat density.

Necrosis

In present study Necrosis was present in 30% of the malignant lesions.

Calcification

In present study calcification noted in 19% (n=14) of malignant lesions and 22% (n=6) of benign lesions.

Of malignant lesions calcification was seen in thyroid malignancies (n=6, 8%) followed by malignant bone tumor (n=4, 6%).

Most common benign lesions that showed calcification are hemangiomas (n=2, 7%) among the benign lesions, attributing to the presence of phleboliths.

Bone involvement

CT scan has the capability to delineate the bone erosion or destruction

with the highest accuracy in the imaging modalities. This is where the CT scan has definite advantage over the MRI. When malignant mass causes bone destruction, CT and MRI can be used as complimentary to each other, without the bias to one modality.

In the present study CT demonstrated bony changes in 15% (n=4) of benign lesions and 19% (n=14) of malignant lesions. Benign lesions caused cortical expansion with or without bony erosions in two cases of ameloblastoma and two cases of benign nasopharyngeal angiofibroma showed bone erosion, one of which showed intraorbital as well as intracranial extension. Malignant lesions caused bony erosions and bony invasions. Cartilage involvement is seen in 7% of malignant cases, most commonly seen in laryngeal malignancy.

Lymph nodes

Size criteria and central necrotic area used to differentiate benign and malignant lymph- nodes .

Lymph nodes were found to be the most common malignant neck lesions in my study. There were total of 17 lymph node with both benign and malignant etiology, lesions with primary lymphoma (8%, out of n=73) or metastasis elsewhere from outside the neck region (13%, of n=73). One case of reactive lymph node hyperplasia seen. There were metastatic lymphnodes (47%, out of n=73) from primary in the neck region seen, in addition.

There were total 6 cases of lymphoma seen.

Distant metastases

Distant metastases was seen in 8 cases, lung was the most common site for distant metastases, seen in 4 cases.

HPE distribution of lesions

In current study most common histopathological pattern in malignant lesions was Squamous cell carcinomas (48%) followed by lymphoma (10%).

Most common histopathological pattern in benign lesions was diffuse nonspecific inflammation followed by pleomorphic adenoma.

Statistics

In present study there were total of 100 cases which had undergone CT scan, on imaging we could provisionally characterize the lesions into 69 malignant cases and 31 benign cases. Final HPE report turned out to be 73 malignant cases and 27 benign cases.

The sensitivity and specificity of study is 95.7% & 77.5% respectively, with positive predictive value and negative predictive value of 90.4% & 88.9% respectively with accuracy of 90%. p value of the test is <.0001.

Sensitivity and specificity correlates with study done by **Malard O et al (2004)[7] Amin MF et al** (2012)[8], **Gary M. K. Tse, et al (2004)** [9].

SUMMARY AND CONCLUSION

This is a prospective study of 100 patients conducted in patients with clinically suspected neck lesions or patients who were diagnosed to have neck lesion on ultrasound. This study is an attempt to understand the role of CT scan in characterization of neck lesions and defining their extent of involvement. Histopathological examination was mode of confirmation of diagnosis.

- Among 100 cases studied 27% were benign and 73% were malignant neck lesions.
- Overall there was a male preponderance with a male to female ratio of 2.1:1.
- Benign lesion were common in the age group of 16-45 yrs. with a male to female ratio of 1.45:1.
- Malignant lesions were more common in the elderly age group of >45 years with a male to female ratio of 2.5:1
- Among the malignant neck lesions the most common was Metastatic lymph-node mass followed oropharyngeal malignancy.
- The most common space involvement was visceral space followed by posterior cervical space.
- Most of the benign (26%) and malignant lesions (81%) showed heterogenous enhancement pattern.
- Hyper dense enhancement pattern was seen in vascular lesions.
- Necrosis was most common among malignant lesions (30%).
- Bone invasion seen in 15% benign lesions, 19% of malignant lesions and cartilage invasion seen in 7% of malignant lesions.
- Most common histopathological pattern among malignant lesions was Squamous cell carcinoma (48%) and among benign lesions most common was nonspecific inflammation.
- The sensitivity and specificity of study is 95.7% & 77.5% respectively, with positive predictive value and negative predictive value of 90.4% & 88.9% respectively and Accuracy is 90%.

From this study we conclude that, contrast enhanced CT scan of the neck has improved the localization and characterization of neck lesions. If there is accurate delineation of disease by CT scan provides a reliable pre-operative diagnosis, plan for radiotherapy ports and post treatment follow up. The most important advantage lies in its ability to detect bony lesions (erosions and expansion). Multidetector CT (MDCT) enables for thinner collimation with use of MPR, MIP, VRT and SSD images which improves the localization of the neck lesions. The faster scan acquisition, less susceptibility to deleterious artefacts from patient motion, ability to be performed in patients with implanted electrical devices are its advantages. CT is a more practical imaging modality due to its relatively lower cost, making it more accessible to patients of lower socioeconomic strata. However, histopathology still remains the gold standard as CT is not 100% accurate.

Image 1

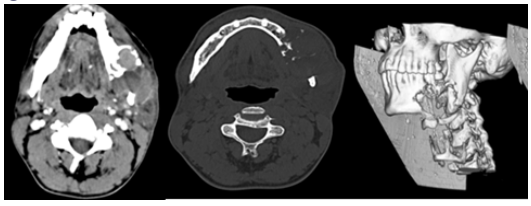

A case of 45 y old male patient, showing expansile lytic lesion involving left ramus of soft tissue enhancing component, bone window image showing bone expansion and erosion while 3D reconstruction showing lesion in left ramus and angle of mandible, diagnosed as ameloblastoma.

Image 2

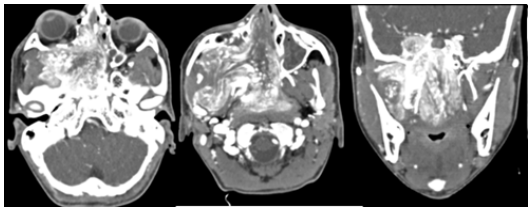

A 20 y old male patient, CECT images showing intensely enhancing nasopharyngeal angiofibroma with extensive bone destruction and showing intracranial and intraorbital extension.

Image 3

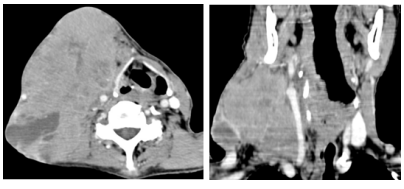

A 48y m with large heterogeneously enhancing nodal mass on right side of neck, histopathologically diagnosed as lymphoma (case series-10)

Image 4

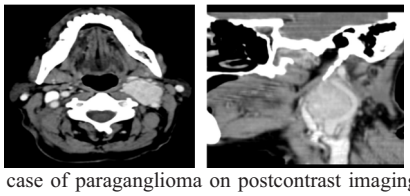

A 60y f, a case of paraganglioma on postcontrast imaging showing intense enhancement causing splaying of external and internal carotid arteries.

Image 5

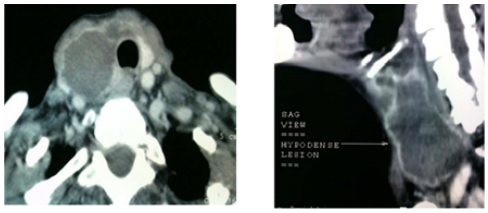

Axial and sagittal CECT images showing large peripherally enhancing hypodense lesion in right lobe and isthmus of thyroid gland, diagnosed as thyroid abscess.

REFERENCES

1. Franz J. Wippold II. Neck; Computed Body Tomography with MRI Correlation , Lee, Joseph K. T, Sagel, Stuart S, Stanley, Robert J, Heiken, Jay P 4th Edition volume I .2006 Lippincott Williams & Wilkins: 145-215.
2. Martinez CR, Gayler B, Kashima H, et al. Computed tomography of the neck. Radiographics 1983; 3: 9 -40.
3. H Greessa ,A Nömayra, B Tomandlb, M Blankc, M Lella, M Lenza.2D and 3D Visualisation Of Head And Neck Tumors From Spiral-Ct Data (2000) European Journal Of radiology March 2000 ; 33(3): 170-177.
4. Alberico RA, Husain SH, Sirotkin I. Imaging in head and neck oncology.(2004) Surg Oncol Clin N Am. 2004 Jan;13(1):13-35.
5. Baum U, Greess H, Lell M, Nömayr A, Lenz M. Imaging of head and neck tumors-methods: CT, spiral-CT, Multislice-spiral-CT. Eur J Radiol. (2000) Mar; 33(3):153-60.
6. Curtin Hd, Ishwaran H, Mancuso AA, Dalley RW, Caudry DJ, McNeil BJ.Comparison of CT and MR imaging in staging of neck metastases.Radiology. 1998 Apr;207(1):123-30.
7. Malard O, Toquet C, Jegoux F, Bordure P, Beauvillain de Montreuil C, Gayet-Delacroix M. Computed tomography in TN stage evaluation of oral cavity and oropharyngeal cancers. Clin Imaging. 2004 Sep-Oct; 28(5): 360-7.
8. Amin MF, El Ameen NF. Diagnostic efficiency of multidetector computed tomography versus magnetic resonance imaging in differentiation of head and neck paragangliomas from other mimicking vascular lesions: comparison with histopathologic examination. Eur Arch Otorhinolaryngol. 2013 Mar;270(3):1045-53. doi: 10.1007/s00405-012-2084-6. Epub 2012 Jun 27.
9 King AD, Tse GM, Ahuja AT, Yuen EH, Vlantis AC, et al. Necrosis in metastatic neck nodes: diagnostic accuracy of CT, MR imaging, and US. Radiology. 2004 Mar; 230(3):720-6.