ORIGINAL RESEARCH PAPER

Volume-7 | Issue-1 | January-2018 | PRINT ISSN No 2277 - 8179

INTERNATIONAL JOURNAL OF SCIENTIFIC RESEARCH

CT IMAGING FEATURES OF PANCREATITIS

Radiodiagnosis

Sharad B. Gadgil Associate Professor, Department of Radio- Diagnosis, Dr. Vasantrao Pawar Medical College Hospital & Research Centre, Nashik, Maharashtra, India.

Zoya Patni* Junior Resident (III), Department of Radio- Diagnosis, Dr. Vasantrao Pawar Medical College Hospital & Research Centre, Nashik, Maharashtra, India. *Corresponding Author

Rounak R. Bagga Junior Resident (III), Department of Radio- Diagnosis, Dr. Vasantrao Pawar Medical College Hospital & Research Centre, Nashik, Maharashtra, India.

Mahesh H. Yadav Junior Resident (II) Department of Radio- Diagnosis, Dr. Vasantrao Pawar Medical College Hospital & Research Centre, Nashik, Maharashtra, India.

ABSTRACT

BACKGROUND: Pancreatitis has highly variable clinical presentation and severity. Computerized tomography (CT) is the modality of choice for investigating pancreatitis. CT is not only very helpful to evaluate focal as well as diffuse lesions but also in evaluating the extent, nature of the lesion and involvement of adjacent structures can be clearly demonstrated.

PURPOSE: The objective of our study was to study the CT findings of Pancreatitis and its associated features in a tertiary care centre.

MATERIALS & METHODS: CT scan of 49 patients with pancreatitis were studied. All the CT scans were performed on Siemens Somatom Perspective (128 slice) machine.

RESULTS: Majority of the patients in this study had imaging features of acute pancreatitis which comprised of 91.8 % of patients. Interstitial edematous pancreatitis (IEP) was the most common type of pancreatitis seen in 71.4 % of patients. In IEP, majority of the patients i.e. 77% had moderately severe pancreatitis and associated pseudocyst was seen in 37 % of these patients. Abdominal pain and fever were the most common complaint. Alcoholism showed strong association with pancreatitis.

CONCLUSION: From this study we can infer that pancreatitis show characteristic findings on CT study. These imaging characteristics coupled with clinical history and laboratory finding helps us to achieve an accurate diagnosis. Imaging techniques enable us to assess, grade and stage pancreatitis with a fair degree of reliability non-invasively. It also helps in designing a management plan for better patient care.

KEYWORDS

Interstitial edematous Pancreatitis (IEP), Necrotizing pancreatitis, Pseudocyst.

INTRODUCTION

The term **"Pancreatitis"** refers to inflammation of the pancreas. It is highly variable in clinical presentation and severity. In majority of the patients, the course is mild and self-limiting, but in some patients it may become fulminant and progress to multisystem organ failure and death [(1)]. Because of this potential for catastrophic deterioration, the stratification of severity is essential. Diagnosis and treatment of these pancreatic pathologies is widely based on clinical symptoms, laboratory and radiological findings.

Conventional radiography and USG has a limited role and value in diagnosis of pancreatitis. MDCT (Multidetector CT) is the primary modality for evaluation of pancreatitis. CT has greatly improved the visualization of pancreas. It is far superior to ultrasound as we can better visualise the pancreatic anatomy and surrounding structures and localize lesions [(2)].This article focuses on the imaging modality of CT and on its application in the evaluation of pancreatitis to arrive at the results.

AIMS AND OBJECTIVES

1. To note the CT imaging findings in case of pancreatitis.
2. To categorize and classify pancreatitis.
3. To study and evaluate associated CT features of acute and chronic pancreatitis.

MATERIALS AND METHODS

This prospective study was carried out over a period of 8 months (January-August2017), with due permission from the ethics committee. The CECT Abdomen of 49 patients was performed, who were referred to the Department of Radiodiagnosis at Dr. Vasantrao Pawar Medical College, Hospital, Nashik with varied complaints. The clinical and demographic data were recorded after due consent to correlate the findings. The patients not willing to give consent were not included in the study.

All the CT scans were done on Siemens Somatom Perspective (128 slice) machine. CT scan of abdomen with axial and coronal reconstruction was performed which is a pre-requisite for detailed evaluation of pancreatic lesions. The density or attenuation of non-enhanced pancreas is normally the same as that of soft tissue, or somewhere between 30-50 Hounsfield units (HU). This increases to 100 to 150 HU after intravenous administration of contrast agents. Normally the Pancreas shows homogeneous enhancement.

A focused pancreatic protocol CT was taken which includes a pancreatic, portal venous and delayed phase. The use of neutral oral contrast media like water is preferred, as it allows superior image reconstruction. A Pancreatic phase refers to the late arterial phase which is taken after a delay of 40-45 sec after contrast injection. It is highly useful for differentiation as in this phase there is maximal tissue differentiation. Portal venous phase is taken after a delay of 60-65 sec after contrast injection.

RESULTS

The present study was carried out at department of Radio diagnosis and imaging at a medical college hospital & Tertiary centre from January-August2017. A total 49 patients were examined and their CT imaging features were studied with the aim of describing pancreatitis. The salient observations are as follows:

- The study comprised of 81.6 % (n=40) males and 18.4 % (n=9) females, between age groups of 00 - 80 years. Majority of the patients in this study i.e. 55.1% were in the 21 to 40 years age group with 40years as the median age (Table 1).
- Pain in abdomen and fever showed association with 100% cases and was the most common complaint. Vomiting (41%) followed by weight loss (16%) are the other most common complaint in our study.
- Alcoholism showed strong association with acute pancreatitis in 62 % of the patients and in 50% of the patients with chronic pancreatitis (Table 2).
- In this study, acute pancreatitis is seen in 91.8 % of the patients (n=45) and chronic in 8.2% (n=4). Amongst those, 77.8% patients have IEP and 22.2 % have necrotizing pancreatitis.
- In IEP majority of the patients i.e. 77% had moderately severe pancreatitis, 23% of patients had mildly severe pancreatitis (Table 3).
- Majority of the patients in IEP i.e. 37 % have associated pancreatic

pseudocysts followed by APC seen in 20% of cases. In necrotizing pancreatitis 50% patients have WON and 50 % have ANC (Table 4).

- The most common finding in association with pancreatitis is pleural effusion seen in 63 % followed by ascites seen in 46% of the patients (Table 5).
- Location wise pseudocysts and WON were seen to occur most commonly in the tail of pancreas seen in 77.8% of the cases and showed most common association with dilated main pancreatic duct (MPD) in 56 % of the patients.
- All the patients with chronic pancreatitis show associated calcifications within the pancreatic parenchyma and one patient had an associated pseudocyst.

DISCUSSION

The pancreas is a retroperitoneal organ having exocrine as well as endocrine function. Since the pancreas is located relatively deep in the abdomen, its imaging by conventional methods has proved to be challenging. After the advent of MDCT detailed visualization and definition of deeper and smaller structures and subtle changes of density of the normal and abnormal pancreas are now possible. The scope of multiplanar reconstruction with MDCT scanners has improved remarkably the ability to visualize and understand complex anatomical structures and relationships (Figure 1A to 1F).

PANCREATITIS

Inflammation of the pancreas is known as pancreatitis. It may further be classified as acute or chronic pancreatitis. Acute pancreatitis is characterized and graded based on its severity according to the Revised Atlanta's classification of 2013 as follows.

CLASSIFICATION:

1. Acute pancreatitis
a. Interstitial edematous pancreatitis (IEP).
b. Necrotizing pancreatitis
2. Chronic pancreatitis
a. Calcifying chronic pancreatitis
b. Obstructive chronic pancreatitis
c. Autoimmune pancreatitis

ACUTE PANCREATITIS

Acute pancreatitis, an inflammatory disease of the pancreas, is mild and resolves itself without serious complications in 80% of patients, but it has complications and a substantial mortality in up to 20% of patients[3].

Etiology: Excessive alcohol intake and gallstones are the most common etiological factors. Other known causes include viral infections, such as mumps, cytomegalovirus and glandular fever, parasite infections, pancreas divisum, annular pancreas, abdominal trauma, surgery, ERCP, hypercalcaemia, hyperparathyroidism, hyperlipidemia, drugs including steroids, thiazide diuretics and azathioprine, polyarteritis, and systemic lupus erythematous.

Symptoms: One of the first symptoms of acute pancreatitis is pain in the epigastric region. The pain may be severe or constant in the abdomen or it may be radiating to the back and other areas. Other symptoms include nausea, vomiting and fever.

Complications: Presence of acute peripancreatic collections, pancreatic and extra-pancreatic pseudocysts, acute necrotic collections, walled off necrosis, pseudoaneurysms with bleeding retroperitoneally or into the gut, fat necrosis, which may lead to hypocalcaemia, ascites, and splenic vein thrombosis, pleural effusion and bowel abnormalities are associated complications.

1. INTERSTITIAL EDEMATOUSPANCREATITIS (IEP):

IEP is a diffuse inflammatory process involving the, pancreatic and peripancreatic tissues, causing interstitial edema, enlargement and minimal organ dysfunction. The recovery is usually uneventful. It is the milder and more common form of acute pancreatitis, seen in 85% of patients [4], and typically resolves within a week [5].

CT findings: Homogeneously enhancing pancreatic parenchyma with peripancreatic fat stranding, with / without acute peripancreatic collection or pseudocyst (Figure 2).

2. NECROTIZINGPANCREATITIS:

Necrotizing pancreatitis has imaging features similar to that of acute pancreatitis but is associated with necrosis, organ failure and/or local complications.

Necrotizing pancreatitis presents in three configurations:
Combined pancreatic and peripancreatic necrosis (75%),
Peripancreatic necrosis alone (20%)
Pancreatic necrosis alone (< 5%) [6,7].

CT findings: Heterogeneously enhancing pancreatic parenchyma with non-enhancing areas (areas of necrosis) within, with/without air foci and acute necrotic collection or walled off necrosis (Figure 3A and 3B).

CT Classification Systems and CT Imaging Features

Pancreatitis in its many forms often presents complex diagnostic and management challenges. The severity of pancreatitis in this study has been scored using the Revised Atlanta's classification (2013).

The disease severity is divided into mild, moderate and severe in accordance with Table 6.

CHRONIC PANCREATITIS:

It is a progressive fibro-inflammatory disorder characterized by intermittent or continuous abdominal or back pain (or both) due to the persistence of structural damage of the pancreas usually caused by many years of alcohol abuse. This damage result in loss of pancreatic parenchyma, functional insufficiency (endocrine and exocrine) and complications such as biliary stricture, pseudocyst, and pseudoaneurysm.

Other causes of chronic pancreatitis are congenital conditions such as pancreas divisum, cystic fibrosis, hypercalcemia, hyperlipidemia or hypertriglyceridemia, some drugs and certain autoimmune conditions.

There are three principal forms of chronic pancreatitis:

1. Calcifying chronic pancreatitis:

Acinar destruction, perilobular fibrosis with acute and chronic inflammatory cells, characterizes this type of chronic pancreatitis. A large proportion of cases present with recurrent bouts of abdominal pain and the eventual development of intraductal calculi. Causative factors include alcohol and tobacco use. There are hereditary, tropical, idiopathic, and senile forms; the senile form is often painless [8].

2. Obstructive chronic pancreatitis:

Atrophy of the upstream pancreas due to tumor or post inflammatory ductal stricture leads to persistent obstruction of the pancreatic duct and is leads to obstructive chronic pancreatitis. It is often painless, occasionally it presents with clinically acute pancreatitis. Intraductal calculi are generally not seen[9].

3. Autoimmune pancreatitis:

This is a chronic systemic lymphoplasmacytic inflammatory process involving the pancreas and other organs.

CT findings:

Pancreatic parenchymal atrophy, calcifications, irregular ductal dilation and strictures are seen. The most specific CT manifestation of chronic pancreatitis is pancreatic calcifications or calculi (Figure 6A and 6B). Calcification is almost always inside the ductal system.

Pancreatic and Peripancreatic Fluid Collections

The most common complications of pancreatitis are pancreatic and peripancreatic fluid collections. These collections may be completely liquefied (fluid) or non-liquefied. In the revised Atlanta classification, an important distinction is made between fluid and non-liquefied collections[10].

1. Acute peripancreatic fluid collections (APFCs):

Non-encapsulated collections which arise typically less than 4 weeks after the onset of acute pancreatitis are known as acute peripancreatic fluid collections. They are peripancreatic, rarely become infected, and generally resolve spontaneously [11]. Acute peripancreatic fluid collections are predominantly found adjacent to the pancreas, without extension within the pancreatic parenchyma, and commonly reside within the lesser sac or anterior pararenal space [12]. 5% to 15% of acute

peripancreatic fluid collections persist beyond 4 weeks and are likely to become pseudocysts [13].

CT appearance: They exhibit a homogeneous fluid appearance - hypodense on CT

2. Pseudocysts:

Pseudocyst occurs as a complication of acute pancreatitis in approximately 10%–20% of cases [14].APFC may gradually transition into a pseudocyst within 4 weeks from onset of acute IEP. According to the revised Atlanta classification, pseudocysts contain no nonliquefied components within the fluid collection. The pseudocyst contains fluid with increased amylase and lipase activity due to communication with the pancreatic ductal system. However, many pseudocysts seal off such a communication and vanish spontaneously.

CT appearance: Pseudocysts exhibit fluid density (< 15 HU) within a well-defined capsule and are well-circumscribed, usually round or oval peripancreatic fluid collections. The capsule is smooth and symmetric and varies in appearance from barely perceptible to uniformly thick and may enhance after contrast agent injection (Figure 4). The presence or absence of communication of the pseudocyst with the pancreatic duct can be demonstrated and can be shown on contrast-enhanced CT images and curved planar reconstructions this helps in the management. An infected pseudocyst is diagnosed on CT images by the presence of gas within the pseudocyst[15].

3. Acute necrotic collections (ANCs):

Acute necrotic collections are non-encapsulated collections of inflammatory fluid and necrotic pancreatic or peripancreatic tissue that arise within the first 4 weeks of necrotizing pancreatitis. Acute necrotic collections are usually asymptomatic and undergo progressive liquefaction and decrease in size [16, 17]. Un-like acute peripancreatic fluid collections, acute necrotic collections may reside within the pancreatic parenchyma and are frequently associated with necrosis of the main pancreatic duct [18, 19]. An ANC may or may not have a connection to the disrupted pancreatic ductal system within the necrosis.

CT appearance: The identification of solid necrotic material on imaging is crucial for differentiating acute necrotic collections from acute peripancreatic fluid collections. Acute necrotic collections appear heterogeneous because of their liquefied and nonliquefied components, seen as irregular hyperdensities among hypodense fluid on CT.

4. Walled off necrosis (WON):

After 4 weeks from onset of necrotizing pancreatitis any apparent fluid collection that occupies or replaces portions of the pancreatic parenchyma should be called a WON. When necrotic tissues and acute necrotic collections mature and form a capsule a WON develops. The capsule is nonepithelialized, and the collection may contain septations within.

The outdated terms “organized pancreatic necrosis,” “necroma,” “pancreatic sequestration,” “pseudocyst associated with necrosis,” and “subacute pancreatic necrosis” are not to be used [4].

Approximately 90% of walled-off necrosis are located in the body or tail, but they can also be distant from the pancreas and frequently extend into the paracolic gutters [4,20,21].

CT appearance: A walled-off necrosis is an encapsulated fluid-density collection within a region that was previously necrotic tissue [22, 23]. WON contains necrotic pancreatic parenchyma or necrotic fat (Figure 5).

Distinction between WON and pseudocysts- Walled-off necrosis and pseudocysts may appear similar on imaging [24]. Specific findings on CT indicative of walled-off necrosis over pseudocyst are larger size, extension to the paracolic or retrocolic space, irregular border, fat attenuation debris, thick or multiple septations, and pancreatic parenchymal deformity or discontinuity [23]. Dilatation of the main pancreatic duct (> 4 mm) favours pseudocyst. The aforementioned findings have an accuracy rate of approximately 80% for differentiating walled-off necrosis from pseudocyst [23].

Other Complications:

1. Disconnected Pancreatic Duct Syndrome
2. Secondary Infection
3. Vascular Complications and Haemorrhage
4. Varices.
5. Pleural effusion.
6. Ascites.

CONCLUSION

Clinical findings of pancreatitis overlap, so imaging plays a great role in diagnosis. CT is the imaging modality of choice for evaluation of pancreatitis and allows better tissue characterisation and anatomical delineation. From this study we can indicate that pancreatitis show characteristic findings on pre and post contrast CT study. Complications of the pancreatitis can be better evaluated by CT which can help in diagnosis as well as treatment planning. Combination of contrast enhanced CT, clinical and laboratory findings add much more information in differentiation and grading of the pancreatitis non-invasively.

DECLARATIONS

Funding: None
Conflict of interest: None declared
Ethical approval: Not required

TABLE1. DEMOGRAPHIC PROFILE

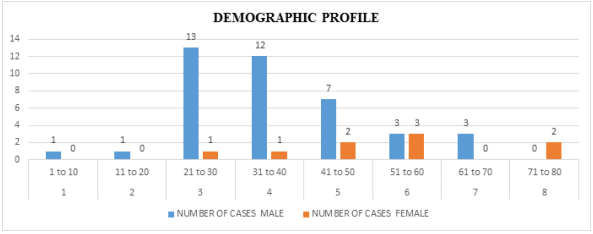

TABLE 2. ASSOCIATION OF ALCOHOLISM WITH PANCREATITIS

Pancreatic pathology	Number of patients with associated alcohol consumption
Acute pancreatitis	28(62%)
Chronic Pancreatitis	2(50%)
Total	30

TABLE 3: CLASSIFICATION OF PANCREATITIS ON THE BASIS OF SEVERITY ACCORDING TO REVISED ATLANTAS CLASSIFICATION OF 2013

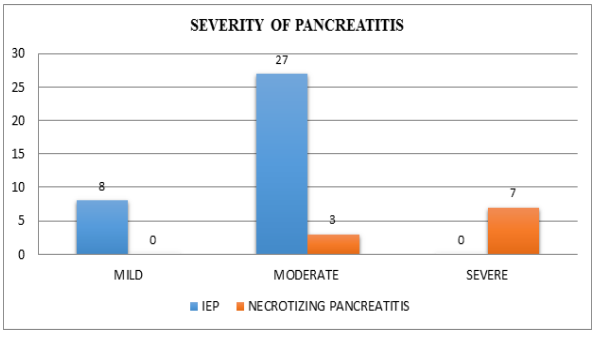

TABLE 4: TYPES OF COLLECTIONS IN PANCREATITIS ACCORDING TO REVISED ATLANTAS CLASSIFICATION OF 2013

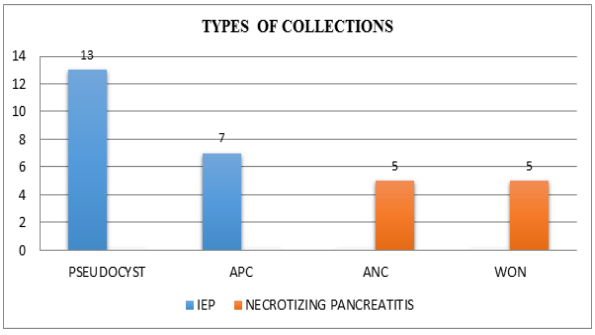

Table 5: Associated CT Findings with Pancreatitis

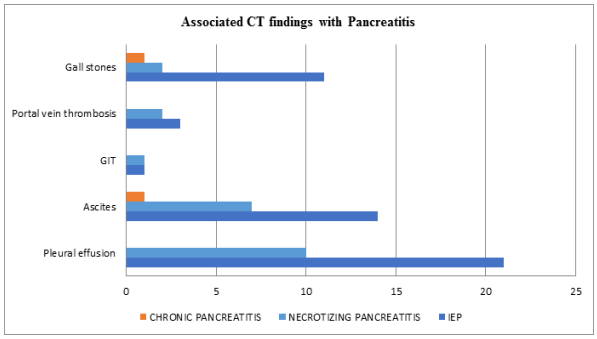

TABLE 6: DEGREE OF SEVERITY IN REVISED ATLANTA CLASSIFICATION

Table: Degree of severity in Revised Atlanta classification (25).
Mild acute pancreatitis -
• No organ failure • No local or systemic complications
Moderately severe acute pancreatitis-
• Organ failure that resolves within 48 h (transient organ failure) and/or • Local or systemic complications without persistent organ failure
Severe acute pancreatitis-
• Persistent organ failure (>48 h) • Single organ failure • Multiple organ failure

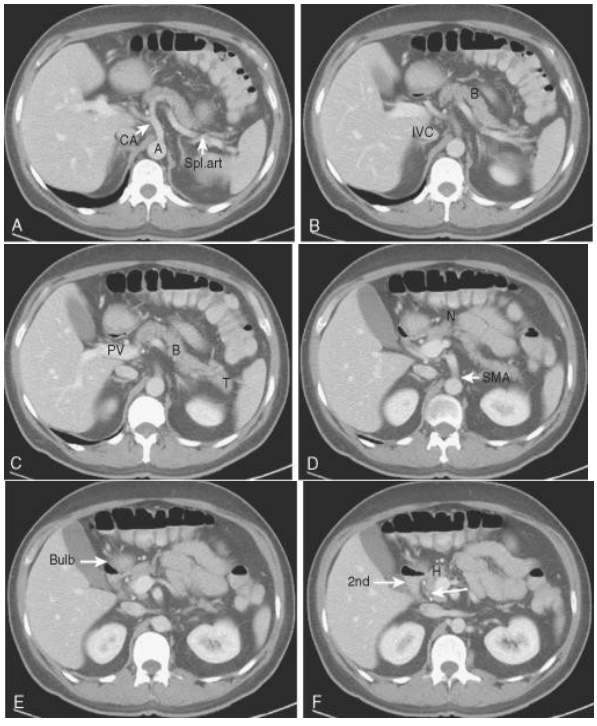

Figure 1A to 1F. Normal Anatomy of Pancreas and its Relations (Axial Cuts at the Level of Pancreas)

AXIAL CT SCAN CUTS:
CA- celiac artery.
A-aorta.
IVC- inferior vena cava.
B- body.
PV- portal vein.

H- Head of pancreas.
SMA- Sup. mesenteric artery. T- Tail of pancreas.
2nd - 2nd part of duodenum.

ACUTE PANCREATITIS

ACUTE INTERSTITIAL PANCREATITIS



Figure 2. Acute Pancreatitis with Acute Peripancreatic Collection

Image Features-
Straight arrow- Acute peripancreatic collection
Curved arrow- Dilated main pancreatic duct
Line arrow- Homogeneously enhancing Bulky pancreas

NECROTIZING PANCREATITIS

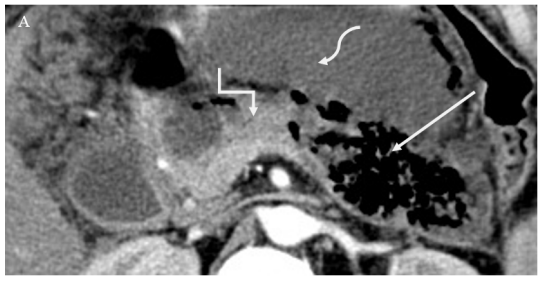

FIGURE 3A. ACUTE NECROTIZING PANCREATITIS.

Image Features-
Straight arrow- Air within the pancreatic collection
Curved arrow- Acute necrotic collection
Line arrow- Heterogeneously enhancing pancreas with necrotic areas

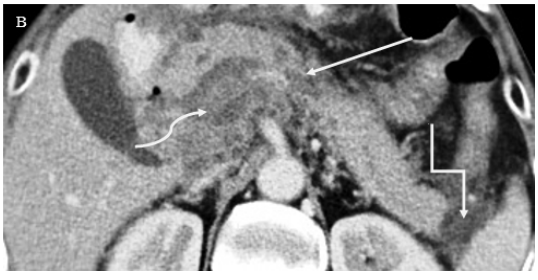

FIGURE 3B. ACUTE NECROTIZING PANCREATITIS

Image Features-
Straight arrow- Heterogeneously enhancing pancreas with
Curved arrow- Areas of necrosis within the pancreas
Line arrow- Acute necrotic collection

PANCREATIC COLLECTIONS
PSEUDOCYST



FIGURE 4. PANCREATIC PSEUDOCYST

Image Features-
Straight arrow- Pseudocyst
Curved arrow- Dilated main pancreatic duct

WALLED OFF NECROSIS (WON)



FIGURE 5. WALLED OFF NECROSIS (WON)

Image Features-
Straight arrow- Walled off necrosis (WON)

CHRONIC PANCREATITIS

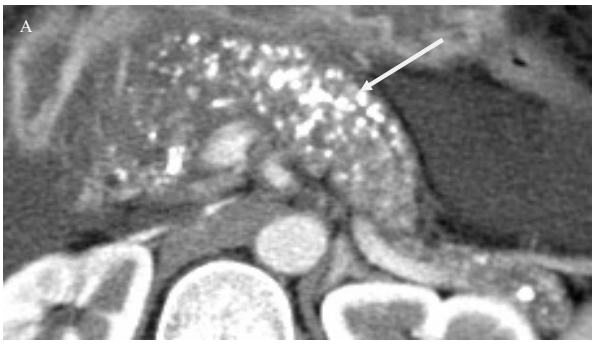

FIGURE 6A. CHRONIC PANCREATITIS

Image Features-
Straight arrow- Multiple calcifications noted throughout pancreatic parenchyma



Figure 6B. Chronic Pancreatitis with Pancreatic Pseudocyst

Image Features-
Straight arrow- Multiple calcifications noted throughout pancreatic parenchyma
Curved arrow- Pseudocyst

REFERENCES

1. Balthazar JE. Acute Pancreatitis: Assessment of Severity with Clinical and CT Evaluation. Radiology 2002; 223: 603-13.
2. Williford ME, Foster Jr WL, Halvorsen RA, Thompson WM. Pancreatic pseudocyst: comparative evaluation by sonography and computed tomography. American Journal of Roentgenology. 1983;140(1):53-57.
3. Lund H, Tønnesen H, Tønnesen MH, Olsen O. Long-term recurrence and death rates after acute pancreatitis. Scand J Gastroenterol 2006; 41: 234-238
4. Banks PA, Freeman ML; Practice Parameters Committee of the American College of Gastroen- terology. Practice guidelines in acute pancreatitis. Am J Gastroenterol2006; 101:2379–2400
5. Singh VK, Bollen TL, Wu BU, et al. An assess- ment of the severity of interstitial pancreatitis. ClinGastroenterolHepatol2011; 9:1098–1103.
6. Thoeni RF. The revised Atlanta classification of acute pancreatitis: its importance for the radiolo- gist and its effect on treatment. Radiology 2012; 262:751–764.
7. SakorafasGH, TsiotosGG, Sarr MG. Extrapan- creatic necrotizing pancreatitis with viable pan- creas: a previously under-appreciated entity. J Am CollSurg1999; 188: 643–648
8. Etemad B, Whitcomb DC: Chronic pancreatitis: Diagnosis, classification, and new genetic developments. Gastroenterology 2001;120:682-707.
9. Kloppel G, Detlefsen S, Feyerabend B: Fibrosis of the pancreas: The initial tissue damage and the resulting pattern. Virchows Arch 2004;445:1-8.
10. Sarr MG, Banks PA, Bollen TL, et al. Re- vision of the Atlanta classication of acute pancreatitis. Acute Pancreatitis Classification Workgroup, April 2008. http://www.pancreasclub.com/resources/AtlantaClassification. Accessed April 8, 2011.
11. Banks PA, Bollen TL, Dervenis C, et al. Classification of acute pancreatitis: 2012—revision of the Atlanta classification and definitions by interna- tional consensus. Gut 2013; 62:102–111
12. StringfellowGV, Casola G, Wittich GR, Shankar S, Shamos R. Management of fluid collections in acute pancreatitis. In: BegerHGW, Büchler MW, Kozarek RA, et al., eds. The pancreas: an integrated textbook of basic science, medicine, and surgery, 2nd ed. Malden, MA: Blackwell, 2009:344–355.
13. Cannon JW, Callery MP, Vollmer CM Jr. Diagno- sis and management of pancreatic pseudocysts: what is the evidence? J Am CollSurg2009; 209:385–393
14. Memi A, Parildar M. Interventional radiolog- ical treatment in complications of pancreati- tis. Eur J Radiol 2002;43(3):219–228.
15. Ashley SW, Perez A, Pierce EA, et al. Necrotizing pancreatitis: contemporary analysis of 99 consecutive cases. Ann Surg2001;234(4):572–579; discussion 579–580.
16. Rana SS, Bhasin DK, Reddy YR, et al. Morpho- logical features of fluid collections on endoscopic ultrasound in acute necrotizing pancreatitis: do they change over time? Ann Gastroenterol2014; 27:258–261
17. Easler J, Papachristou GI. The morphologic evo- lution of necrotic pancreatic fluid collections and their management: asymptomatic—delay, defer and don't panic! Ann Gastroenterol2014; 27:191– 192
18. Brun A, Agarwal N, Pitchumoni CS. Fluid collec- tions in and around the pancreas in acute pancreatitis. J ClinGastroenterol2011; 45:614–625.
19. Bharwani N, Patel S, Prabhudesai S, Fothering- ham T, Power N. Acute pancreatitis: the role of imaging in diagnosis and management. Clin Ra- diol2011; 66:164–175.
20. Papachristou GI, Takahashi N, Chahal P, Sarr MG, Baron TH. Peroral endoscopic drainage/de- bridement of walled-off pancreatic necrosis. Ann Surg2007; 245:943–951.
21. Munene G, Dixon E, Sutherland F. Open transgas- tric debridement and internal drainage of symp- tomatic non-infected walled-off pancreatic necro- sis. HPB (Oxford) 2011; 13:234–239.
22. Türkvatan A, Erden A, Türkoğlu MA, Seçil M, Yüce G. Imaging of acute pancreatitis and its complications. Part 2. Complications of acute pancreatitis. DiagnInterv Imaging 2015; 96:161– 169.
23. Takahashi N, Papachristou GI, Schmit GD, et al. CT findings of walled-off pancreatic necrosis (WOPN): differentiation from pseudocyst and prediction of outcome after endoscopic therapy. EurRadiol2008; 18:2522–2529.
24. RamiaJM, de la Plaza R, Quinones-Sampedro JE, Ramiro C, Veguillas P, Garcia-Parreno J. Walled-off pancreatic necrosis. Neth J Med 2012;70:168–171.
25. Banks P a., Bollen TL, Dervenis C, et al. Classification of acute pancreatitis--2012: revision of the Atlanta classification and definitions by international consensus. Gut. 2013;62(1):102-111. doi:10.1136/gutjnl-2012-302779.