ORIGINAL RESEARCH PAPER
Volume-6 | Issue-10 | October-2017 | ISSN No 2277 - 8179 | IF : 4.176 | IC Value : 78.46
INTERNATIONAL JOURNAL OF SCIENTIFIC RESEARCH

CT SCAN AND ULTRASOUND EVALUATION OF NECK MASSES WITH HISTOPATHOLOGICAL CORRELATION

Radiodiagnosis

***Dr. Shishir R Rawekar**	Junior Resident in Dept. of Radio diagnosis, AVBRH, Sawangi (M), Wardha. *Corresponding Author
Dr. Suresh V Phatak	Professor & HOD in Dept. of Radio diagnosis, AVBRH, Sawangi (M), Wardha.
Dr. Rajendra T Rawekar	Associate Professor in Dept. of Medicine, AVBRH, Sawangi (M), Wardha.
Dr. Saherish Khan	Junior Resident in Dept. of Radio diagnosis, AVBRH, Sawangi (M), Wardha.
Dr. Hemant Thakur	Junior Resident in Dept. of Radio diagnosis, AVBRH, Sawangi (M), Wardha.

ABSTRACT

INTRODUCTION: Neck lesions are the masses arising from the major structures and lymph nodes in the neck. Diagnosis and characterisation of neck masses is important in planning of further management. Ultrasound being the primary modality of imaging, it helps in characterisation of lesion and in guided biopsies in superficial lesions. Multislice CT scan is useful in correctly delineating the extension of lesion.

AIM & OBJECTIVES: Prospective evaluation of neck masses by Multislice CT scan and Ultrasound.

1. To evaluate & characterise various neck masses using Multislice CT scan and high-resolution ultrasound.
2. To correlate imaging findings with cytological/histopathological findings.

MATERIAL & METHODS: A prospective study was conducted (1st June 2015 to 31st May 2017) in department of Radiodiagnosis AVBRH, Sawangi (M), Wardha, Maharashtra. A sample size of 100 patients with clinically palpable neck masses were evaluated radiologically irrespective of age and sex. The study is performed on CT scan machine of Philips 16 slice BRILLIANCE 190P and Aloka Prosound Alpha 7 USG machine with a high resolution probe having frequency (5-15 MHz) linear transducer with patients consent.

RESULTS: Higher incidence of neck masses was found in females with a male to female ratio of 0.57: 0.95. Benign lesions were predominantly found in 11-20yrs and malignant lesions in 41-50yrs of age group. Most of the lesions in the current series were seen in visceral space (38%). On ultrasound 50% of patient showed benign characteristic, 39% showed malignant characteristic. On further evaluation with CT scan 46% of patient showed benign characteristic, 43% showed malignant characteristic.

CONCLUSION: Ultrasound in conjunction with CT scan is useful in diagnosing and planning the management of the lesions better than imaging with either of the modality alone. In few benign lesions in paediatric age group where diagnostic accuracy of USG is 100% like in cases of cystic hygroma, Thyroglossal cyst and type two Branchial cleft cyst CT scan could be avoided to prevent un-necessary radiation exposure.

KEYWORDS

INTRODUCTION

Neck is the complex part of human body. Neck anatomically is divided into anterior and posterior triangles, which is composed of major structures and lymph nodes. Inferior border of mandible, sternocleidomastoid muscle and the midline of the neck form the boundary of anterior triangle of neck. Sternocleidomastoid muscle, trapezius muscle and clavicle form the boundary of posterior triangle of neck. Major structures in the neck include thyroid gland, hyoid bone, and thyroid cartilage with its notch, cricothyroid membrane, cricoid cartilage, trachea, carotid bulb, parotid gland and submandibular salivary glands. For better understanding and classification cervical lymph nodes are divided into multiple levels. Level I is comprised of submandibular and submental nodes; level II, III & IV is comprised of nodes along the internal jugular vein deep to sternocleidomastoid muscle; level V is comprised of nodes in posterior triangle; level VI is comprised of prelaryngeal and pretracheal nodes which lie between carotid sheaths in the anterior triangle. Some major structures are non-palpable and some are normal yet palpable, which are often confused with pathology (1).

Neck lesions are the masses arising from these major structures and lymph nodes in the neck. Neck masses can be solid, cystic or mixed. Neck masses are found in adults and as well as paediatric age groups. Neck masses in adults includes congenital anomalies, inflammatory masses, masses due to trauma, and masses due to metabolic, neoplastic & idiopathic conditions(2). Masses found in paediatric age group can be congenital, inflammatory and neoplastic.

The radiologic evaluation of the neck masses is an important adjunct to the clinical history and physical examination. In this study neck masses will be evaluated with the help of Multislice CT scan and ultrasound scan. Contrast enhanced CT scan is usually recommended to patient for cross-sectional imaging in adults and children presenting with a neck mass and who have no contraindications to selected contrast agents(3). Contrast is useful in assessing tumour margins, detecting neck abscesses, malignant nodes that are not pathologically enlarged (4-6). Plain CT scan is recommended in patients with a neck mass suspected of benign swollen major salivary gland due to an obstructing sialolith. Multislice CT correctly delineates the extent of lesion e.g. in solitary rhabdomyosarcoma. CT scan is cost effective than MRI and as it is best technique for imaging bony matrix it helps in identifying small soft tissue calcification. In previous studies it is found that Multislice CT examination in paediatric age group is useful as it reduces frequency and severity of motion artefacts by reducing time of scan as compared to MRI (7).

Ultrasound is investigation of choice in paediatric age group and initial diagnosis as it is cost effective than CT scan as there is no radiation exposure and sedation is not required. It is useful in differentiating solid from cystic neck lesions, measuring the size of node, in discriminating high flow from low flow vascular malformation (8-11) and for image guided biopsies of non-palpable and superficial small lesions. It is also found that Colour Doppler Ultrasound helps to distinguish between metastatic and inflammatory neck nodes as well (12-14).

MATERIAL & METHODS

This was a prospective study conducted in Acharya Vinoba Bhave Rural Hospital, Sawangi (M), Wardha, Maharashtra, India between July 2015 to July 2017. A sample size of 100 patients with neck

swelling irrespective of age, sex duration of history and etiology referred to department of Radiodiagnosis from ENT, Surgery and Oral Maxillofacial Surgery department will be included. After obtaining written consent from patient in local language and ethical clearance, patients will undergo history recording, CT scan and ultrasonography evaluation with histopathological sampling wherever possible. All the clinically diagnosed cases of neck masses irrespective of age and sex will be included in the study. All post operative patients and patients having previous history of any allergy or significant past history of allergy to iodinated contrast media and patients with impaired renal function test will be excluded.

Ultrasound will be the primary modality of imaging and patients will be referred to CT scan for further evaluation. CECT will be performed on Philips 16 slice BRILLIANCE 190P machine with parameters of 90^0 view angle, 350mm length 120 kV and 50 mAs for surview lateral for localization of lesion to include maximum epicenter. Afterwards scanning is done in axial section with 3mm slice thickness and 1.5mm increment in thickness, 120 kV and 250mAs, standard resolution, collimation of 0.16x0.75 mm, pitch of 0.938, gantry rotation time of 0.75 second. Non-ionic iodinated contrast medium was given 2ml/kg of body weight of patient with pressure of 325psi at the rate of 3ml/sec through 18/20/22 gauge i.v. canula. An arterial phase is taken 13second after contrast injection, venous after 40seconds and delayed after 3mins. Coronal and sagittal images are then reformatted. Ultrasound will be done on Hitachi Arietta S70 USG machine with a high-resolution linear transducer of frequency (3-15 MHz). FNAC was done by 21-24 gauge Hypodermic needles wherever possible.

RESULTS AND OBSERVATIONS:

This is a prospective study to find the efficiency of Multislice CT scan and USG in the evaluation of neck lesions with histopathological correlation.

Table I: Age and Gender Distribution of the Neck Lesion (N=100)

Age Group (yrs.)	Number (N=100)			Percentage (%)
	Females	Males	Total	
<10	4(6.45%)	2(5.26%)	6	6
11 – 20	9(14.51%)	4(10.52%)	13	13
21 – 30	7(11.29%)	3(7.8%)	10	10
31 – 40	11(17.74%)	4(10.52%)	15	15
41 – 50	11(17.74%)	12(31.70%)	23	23
51 – 60	12(19.35%)	7(18.42%)	19	19
61 – 70	7(11.29%)	4(10.52%)	11	11
71 – 80	1(1.63%)	1(2.63%)	2	2
81 – 90	0(0%)	0(0%)	0	0
91 – 100	0(0%)	1(2.63%)	1	1
Total	62	38	100	100

Graph I: Age-wise distribution of patient studied

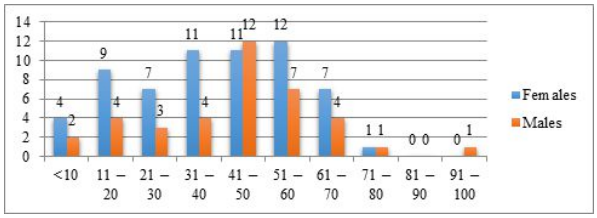

Graph II: Gender-wise distribution of patients

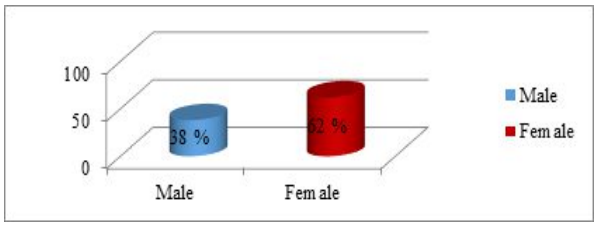

The current study shows higher incidence of neck mass among females with a male to female ratio of 0.57: 0.95.

Table II: Distribution of Neck Mass According to Space (N=100)

Neck spaces	Frequency	Percent (%)
Masticator space	1	1
Buccal space	6	6
Parotid space	13	13
Parapharyngeal space	0	0
Retropharyngeal space	0	0
Prevertebral space	1	1
Carotid space	13	13
Submandibular space	16	16
Visceral space	38	38
Pharyngeal mucosal space	2	2
Posterior cervical space	10	10
Total	100	100

Graph III: Distribution of Neck Mass According to Space (N=100)

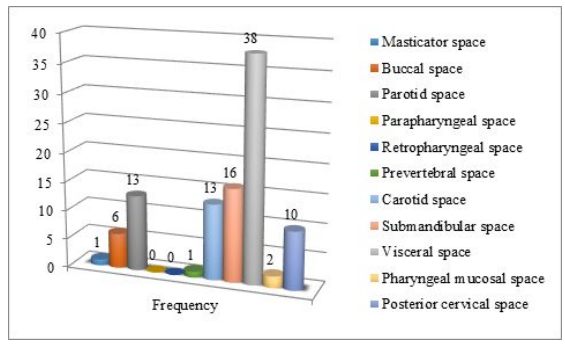

Most of the lesions in the current series were in visceral space followed by Submandibular space constituting 38% and 16 % respectively of the total sample size.

Table III: Ultrasound characteristics of neck masses (N=100)

Sonographic features	Characteristics	Benign (N=50)		Malignant (N=39)		Inflammatory (N=11)	
		No.	(%)	No.	(%)	No.	(%)
Shape	Round	5	10	5	13	0	0
	Oval	28	56	4	10	6	55
	Lobular	16	32	5	13	4	36
	Polygonal	1	2	25	64	1	9
Margins	Ill-defined	1	2	30	77	1	9
	Well defined	49	98	9	23	10	91
Echo-intensity	Anechoic	13	26	0	0	0	0
	Isoechoic	11	22	0	0	0	0
	Hypoechoic	16	32	38	97	11	100
	Hyperechoic	6	12	0	0	0	0
	Mixed	4	8	1	3	0	0
Architecture of lesion	Homogeneous	30	60	0	0	0	0
	Heterogeneous	20	40	39	100	11	100
Presence of necrosis	Present	0	0	28	72	1	9
	Absent	50	100	11	28	10	91
Posterior echoes	Enhanced	24	48	1	3	8	73
	Unchanged	19	38	22	56	3	27
	Attenuated	7	14	16	41	0	0
USG characteristics of tissue	Cystic	18	36	0	0	0	0
	Solid	23	46	31	79	1	9
	Mixed	9	18	8	21	10	91
Vascularity	Avascular	24	48	0	0	0	0
	Slow flow	15	30	2	5	3	27
	Medium to high flow	11	22	37	95	8	73

On ultrasound 50% of patient showed benign characteristic of lesion, 39% showed malignant characteristic and 11% showed inflammatory changes.

Table IV: CT Characteristics of Malignant Neck Mass (N=43)

Malignant Lesions	Lesion density			Contrast Enhancement			Necrosis		Calcification		Bony Invasion		Adjacent Space Invasion		Margins	
	Soft tissue (40 to 60 HU)	Fluid (0 to 30 HU)	Fat (130 to -70 HU)	Homogeneous	Heterogeneous	peripheral	-ve	+ve	Present	Absent	Absent	Present	Absent	Present	Ill defined	Well defined
CA Thyroid	15	0	0	0	15	0	0	15	14	1	13	2	1	14	13	2
CA Parotid	6	0	0	0	6	0	0	6	4	2	4	2	2	4	5	1
CA SMG	4	0	0	0	4	0	0	4	3	1	1	3	2	2	3	1
Metastatic LN	1	4	0	0	1	4	1	4	2	3	5	0	2	3	1	4
CA Buccal mucosa	6	0	0	2	4	0	3	3	4	2	1	5	3	3	6	0
Ewing's sarcoma	2	0	0	0	2	0	2	0	2	0	0	2	0	2	2	0
CA mandible	2	0	0	0	2	0	0	2	2	0	0	2	1	1	2	0
CA Pharynx	2	0	0	0	2	0	0	2	1	1	1	1	1	1	2	0
CA Larynx	1	0	0	0	1	0	0	1	0	1	1	0	0	1	1	0
Subtotal	41	2	0	2	37	4	6	37	32	11	26	17	12	31	35	8
Total	43			43			43		43		43		43		43	

Table V: CT Characteristics of Benign Neck Mass (N=46)

Benign Lesions	Lesion density			Contrast Enhancement				Necrosis		Calcification		Bony Invasion		Adjacent Space Invasion		Margins	
	Soft tissue (40 to 60 HU)	Fluid (0 to 30 HU)	Fat (130 to -70 HU)	absent	Homogeneous	Heterogeneous	peripheral	-ve	+ve	Present	Absent	Absent	Present	Absent	Present	Ill defined	Well defined
Follicular adenoma	8	0	0	0	2	6	0	8	0	2	6	8	0	8	0	2	6
Pleomorphic adenoma	6	0	0	0	0	6	0	3	3	4	2	6	0	4	2	0	6
Thyroglossal cyst	0	3	0	0	0	0	3	3	0	0	3	3	0	3	0	0	3
Ranula	0	3	0	3	0	0	0	3	0	0	3	3	0	2	1	0	3
Branchial cleft cyst	0	1	0	0	0	0	1	1	0	0	1	1	0	1	0	0	1
Cystic hygroma	0	2	0	0	0	0	2	2	0	0	2	2	0	2	0	0	2
MNG	6	0	0	0	0	6	0	6	0	6	0	6	0	5	1	0	6
Warthin's tumour	1	0	0	0	1	0	0	1	0	0	1	1	0	1	0	0	1
Lymphangioma	0	8	0	6	0	0	2	8	0	0	8	8	0	5	3	0	8
Liopma	0	0	1	1	0	0	0	1	0	0	1	1	0	0	1	0	1
Benign LN	7	0	0	0	5	2	0	5	2	2	5	7	0	5	2	1	6
Subtotal	28	17	1	10	8	20	8	41	5	14	32	46	0	36	10	3	43
Total	46			46				46		46		46		46		46	

Table VI: CT Characteristics of Inflammatory Neck Mass (N=11)

Inflammatory Lesions	Lesion density			Contrast Enhancement			Necrosis		Calcification		Bony Invasion		Adjacent Space Invasion		Margins	
	Soft tissue (40 to 60 HU)	Fluid (0 to 30 HU)	Fat (130 to -70 HU)	Homogeneous	Heterogeneous	peripheral	-ve	+ve	Present	Absent	Absent	Present	Absent	Present	Ill defined	Well defined
Hashimoto's thyroiditis	6	0	0	0	6	0	6	0	0	6	6	0	6	0	0	6
Tubercular lymphadenitis	2	0	0	0	0	2	0	2	2	0	2	0	0	2	0	2
Sternocliedomastoid abscess	1	0	0	0	0	1	1	0	0	1	1	0	1	0	1	0

Kimura's disease	1	0	0	0	1	0	1	0	0	1	1	0	0	1	0	1
Acute sialadenitis	1	0	0	0	1	0	1	0	0	1	1	0	0	1	1	0
Subtotal	11	0	0	0	8	3	9	2	2	9	11	0	7	4	2	9
Total	11			11			11		11		11		11		11	

Table VII: Distribution of lesion according to Ultrasound, CT scan and Histopathological diagnosis (N=100)

Nature of lesion	Ultrasonography		CT scan		Histopathology	
Benign lesions	No.	%	No.	%	No.	%
- Follicular adenoma	8	14	8	16	6	12
- Pleomorphic adenoma	8	14	6	10	6	12
- Thyroglossal cyst	3	8	3	8	3	9
- Ranula	3	8	3	8	3	9
- Branchial cleft cyst	1	2	1	3	1	3
- Cystic hygroma	2	5	2	5	2	5
- Multinodular colloid goiter	8	14	6	10	6	12
- Warthin's tumour	1	2	1	3	1	3
- Lymphangioma	8	19	8	21	8	23
- Liopma	1	2	1	3	1	3
- Benign lymphadenopathy	7	12	7	13	5	9
Total benign	50	100	46	100	42	100
Malignant lesions	No.	%	No.	%	No.	%
- CA Thyroid	13	36	15	37	17	38
- CA Parotid	4	13	6	15	6	14
- CA Submandibular gland	4	9	4	8	4	7
- Metastatic lymphadenopathy	5	15	5	14	7	16
- CA Buccal mucosa	6	13	6	12	6	11
- Ewing's sarcoma	2	4	2	4	2	4
- CA Mandible	2	4	2	4	2	4
- CA Pharynx	2	4	2	4	2	4
- CA Larynx	1	2	1	2	1	2
Total malignant	39	100	43	100	47	100
Inflammatory lesions	No.	%	No.	%	No.	%
- Hashimoto's thyroiditis	6	55	6	55	6	55
- Tubercular lymphadenitis	2	18	2	18	2	18
- Sternocliedomastoid abscess	1	9	1	9	1	9
- Kimura's diseases	1	9	1	9	1	9
- Acute sialadenitis	1	9	1	9	1	9
Total inflammatory	11	100	11	100	11	100
Total (N)	100	100	100	100	100	100

In present study, out of 100 cases studied, 42 (42%) came out to be of benign aetiology, 47 (47%) were of malignant aetiology and 11 (11%) were of inflammatory in origin after histopathological correlation. Most common benign lesions in the series were Lymphangioma followed by Pleomorphic adenoma, Multinodular goiter and follicular adenoma. Most common malignant lesions in the series were thyroid malignancy followed metastatic lymphadenopathy and CA parotid. Most common inflammatory lesions in the series were hashimoto's thyroiditis followed by tubercular lymphadenopathy.

Table VIII: Ultrasound & Histopathological correlation of benign v/s malignant lesions

		HISTOPATHOLOGICAL DIAGNOSIS		
		MALIGNANT	BENIGN	
USG DIAGNOSIS	MALIGNANT	39	0	39
	BENIGN	8	42	50

Table IX: CT Scan & Histopathological correlation of benign v/s malignant lesions

		HISTOPATHOLOGICAL DIAGNOSIS		
		MALIGNANT	BENIGN	
CT SCAN DIAGNOSIS	MALIGNANT	43	0	43
	BENIGN	4	42	46

Table X: Relative values of USG and CT scan in differentiating Benign & Malignant neck lesions

	Sensitivity (%)	Specificity (%)	X2	Postive Predictive Value (%)	Negative Predictive Value (%)	P-value
USG	82.98	100.00	62.03	100.00	84.00	<0.0001,S
CT SCAN	91.49	100.00	74.35	100.00	91.30	<0.0001,S

In present study 2 cases of Multinodular colloid goitre and 2 cases of Pleomorphic adenoma were wrongly diagnosed on Ultrasonography, which on further evaluation on CT scan showed malignant characteristics and on histopathology were proved malignant. Another four cases, two of metastatic lymphadenopathy and two of follicular carcinoma of thyroid were wrongly diagnosed on CT scan as benign lymphadenopathy and follicular adenoma and further on histopathological evaluation proved to be malignant lesions.

DISCUSSION

This study was conducted in department of Radiodiagnosis, JNMC, Sawangi (M) Wardha. In this two year prospective study 100 cases of neck masses were evaluated by Ultrasonography and CT scan and there pathological follow-up was kept. In the present study the importance of Ultrasonography and CT scan in characterising and diagnosing the neck masses has been demonstrated.

There is significant role of diagnostic tests to classify and diagnose the neck masses. On the basis of clinical and physical examination further diagnostic investigations are advised. Like ultrasound and Doppler examination is primary modality of imaging for pulsating masses indicating its hypervascularity. Congenital cystic masses require ultrasonography for its differential diagnosis. Ultrasonography and sialography will be required in salivary gland lesions, and for determination of neoplastic formation and relationship of masses with surrounding structure will require CT scan. However pathologic evaluation of mass will remain gold standard (15, 16).

The most common neck lesions in this study were of thyroid origin (35%) predominantly among female patients out of which 17 were of malignant aetiology, 12 were of benign aetiology and 6 were of inflammatory aetiology. Thyroid malignancies were most common among the malignant lesions in this study followed by metastatic lymphadenopathy. The most common space involved in this study was visceral space (38%) which could be attributed to thyroid lesions in this space followed by Submandibular space (16%) which could be attributed predominantly to both benign and malignant lymphadenopathy and Submandibular gland carcinoma.

In present study 8 cases of follicular adenoma were diagnosed on USG and CT scan. Out of which 2 cases turned out to be of follicular carcinoma on further histopathological evaluation. Those 2 discordant cases on ultrasound evaluation had non-specific finding and hence were subjected to CT scan and diagnosis of follicular adenoma was kept. However later histopathology was suggestive of follicular carcinoma. In the study done by Dong Hyun Kim in 2016 on "computed tomography features of follicular thyroid adenoma and carcinoma" conclusion was kept that CT scan may be unhelpful in distinguishing follicular thyroid adenoma from follicular carcinoma (17). The other 4 cases on ultrasound showed well defined, solid cystic, round to oval, homogenously Hypoechoic lesions with peripheral thin rim of halo with no calcification and Vascularity within. Similar characteristic USG findings were reported by Zhang J, Hu B in their study of "Sonographic Features of Thyroid Follicular Carcinoma in Comparison With Thyroid Follicular Adenoma" (18).

In present study 8 cases of Pleomorphic adenoma was diagnosed on USG. Out of which 2 cases showed malignant characteristics on CT scan and later on histopathology were proved malignant. Seifert G et al in the study of "histopathology of malignant salivary gland tumours" described the increased risk of developing malignancy in long standing cases of Pleomorphic adenoma by 1.5% if the duration is less than 5 years and 9.5% if the duration is more than 15years (30). The characteristic finding on USG was well defined, solid, lobulated, homogenously Hypoechoic mass with posterior acoustic enhancement and absence of necrosis and few calcific foci within. The findings were similar as found in study by Chandak et al. (19), Rajesh et al. (20), and Gritzman et al. (21). In case of CT scan imaging finding depends upon the size of lesion. Small lesions were more homogenous, well defined with intense post contrast enhancement, whereas larger lesions were more lobulated and heterogeneous with few necrotic areas within. The findings were similar to study done by Thoeny HC on "imaging of salivary gland tumour" (22).

In present study 3 cases of Thyroglossal cyst were diagnosed on both USG and CT scan which were later correlated with histopathological finding giving 100% accuracy of radiological diagnosis. Sonographically characteristic findings were midline anechoic well circumscribed cystic lesions with increased through-transmission and no internal vascularity. The findings were similar to study done by R Kraus et al on "Sonography of neck masses in children" (23). On CT scan the lesions were unilocular, well circumscribed of low density showing well defined walls with peripheral rim enhancement on post contrast images. The findings were similar to study done by Reede D et al on "CT of Thyroglossal duct cyst" (24).

In present study 3 cases of Ranula were diagnosed on both USG and CT scan which later were confirmed on histopathology giving 100% accuracy of radiological diagnosis. Out of three cases two were of plunging ranula and one was of simple ranula. On USG ranula was seen as anechoic well encapsulated cystic lesion. However in case of simple ranula which was confined to sublingual space showed thick walls with internal echoes which was consistent with infective changes. The plunging ranula was seen extending to submandibular space around the posterior edge of mylohyoid muscle. On CT scan well circumscribed, oval, low attenuation mass was seen confined to sublingual space in case of simple ranula and extending to either of submandibular space in case of plunging ranula with 'Tail sign'. Enhancement of lesion with adjacent fat stranding is seen with infective changes. The findings were similar to report published by Charnoof S et al and Kalra V et al on plunging ranula (25, 26).

In present study 1 case of type II Branchial cleft cyst was found which showed characteristic USG features of cystic swelling anterior to Sternocliedomastoid muscle with medial extension in between external and internal carotid arteries giving 'Beak sign'. The swelling was round to oval, anechoic with well circumscribed margins showing posterior acoustic enhancement. On CT scan similar lesion was seen as well circumscribed, round, homogenous, low density lesion with imperceptible walls (26). Later on at histopathology it was confirmed.

In present study 7 cases of benign lymphadenopathy were diagnosed on USG and CT scan. Out of which 2 cases on histopathological evaluation were diagnosed as metastatic lymphadenopathy. On USG the lymph nodes were mainly well defined, oval, Hypoechoic, heterogeneous in echo texture showing predominantly hilar vascularity and no necrosis. However on CT scan similar findings were confirmed. Van den Brekel M in his study of "lymph node metastasis: CT and MRI" confirmed that neither the CT nor MRI can accurately diagnose the metastatic lymphadenopathy (27).

In present study 8 cases of Multinodular colloid goitre were diagnosed on USG. Out of which 2 cases showed malignant characteristics on CT scan and later on histopathology were proved malignant. Hanumanthappa. M.B et al. in their study concluded that incidence of malignancy in Multinodular colloid goitre is quite significant (29). On USG characteristic features of Multinodular colloid goitre were diffusely enlarged thyroid gland, multiple iso to hyperechoic nodules with heterogeneous echo texture and few areas of cystic degeneration. Few nodules had peripheral or coarse calcification. On colour Doppler peripheral vascularity was noted around the nodules and occasionally intranodal vascularity was found. The characteristics were similar to as described by Chaudhary V et al (28). On CT scan a similar findings were confirmed and is useful for characterising the extent of goitre.

In current study out of all benign lesions found on USG features suggesting benignity were (98%) had well defined margins, (56%) lesions were oval in shape, (26%) lesions were anechoic and (22%) lesions were iso-echoic, (60%) lesions showed homogeneous echo texture with absence of necrosis in almost all cases. (48%) lesions showed through transmission with posterior acoustic enhancement. Maximum lesions were solid (43%) followed by cystic (36%) and Avascular on Doppler in 48% patients and slow flow in 30% patients. USG features of inflammatory lesions that were found are most of the lesions were oval in shape (55%) with relatively clear well defined margins (91%). Almost all (100%) the inflammatory lesions were Hypoechoic and heterogeneous in echo texture. 73% of the inflammatory lesions showed enhanced posterior acoustic enhancement and mixed tissue characteristic (91%) with maximum lesions showing medium to high flow (73%) vascularity on Doppler mode. USG features of malignant lesions that were found are polygonal shape (64%), ill defined margins (77%), Hypoechoic (97%), heterogeneous echo texture (100%), unchanged posterior echoes (56%), solid (70%) to mix (21%) tissue characteristic, necrosis (72%) and medium to high flow (95%) on vascularity. These ultrasonographic findings were nearly similar to findings described in the study done by Shah JS et al. in "Clinical applications of ultrasonography in diagnosing head and neck swellings" (31).

In present study lesions with well defined margins and maintained fat plane on CT scan suggested benignity of lesion differentiating it from malignant. The inflammatory lesions on CT scan showed low density with mild to moderate fat plane obliteration and thick peripheral rim of enhancement. However the differentiating features of benign, malignant and inflammatory lesions were similar to those described by David Y and Kathleen M (32).

The difference between the present study and other studies may be observed because malignant masses and abscess are more common in India owing to poor life style pattern, poor oral hygiene and lack of awareness. Late presentation of the patients for investigations and patient referral for diagnosing the extent of tumoral spread could be another factor for high incidence of malignant lesions. Selection bias and sample size may be partly responsible for discordance between our studies.

CONCLUSION

In this study the CT scan has sensitivity of 91.49% and specificity of 100% in diagnosis of malignant and benign lesions whereas ultrasound has sensitivity of 82.98% and specificity of 100% in correlation with histopathological diagnosis. And by using Chi square Test statistically significant association was found between CT scan and Histopathological findings.(X^2=74.35, P-value=<0.0001, significant), hence proving CT scan as better modality in diagnosing, characterisation and demonstrating extent of lesion. However ultrasound in conjunction with CT scan is useful in diagnosing and planning the management of the lesions better than imaging with either of the modality alone. However ultrasound will always be the primary modality of imaging in all sorts of lesions. In few benign lesions in paediatric age group where diagnostic accuracy of USG is 100% like in cases of cystic hygroma, Thyroglossal cyst and type two Branchial cleft cyst CT scan could be avoided to prevent un-necessary radiation exposure. However in case of large benign lesions CT scan becomes important to determine the extent of lesion for better surgical planning.

Advantages of ultrasound are that it is simple and fast procedure with good diagnostic accuracy and helps in USG guided FNAC for histopathological sampling. However in cases of patients with follow up, USG can be readily done in comparison to CT scan. The only disadvantage of USG can be that it is operator dependent and it is less sensitive in characterising the extent of lesion.

On other hand CT scan is non operator dependent and helps in accurate characterisation of tissue attenuation coefficient. Spiral CT provides improved examination quality, reduction in sedation time and reduction in radiation dose

CASES:

CASE I: 55yrs female presented with goitre and hypothyroidism (FNAC: Hashimoto's Thyroiditis)

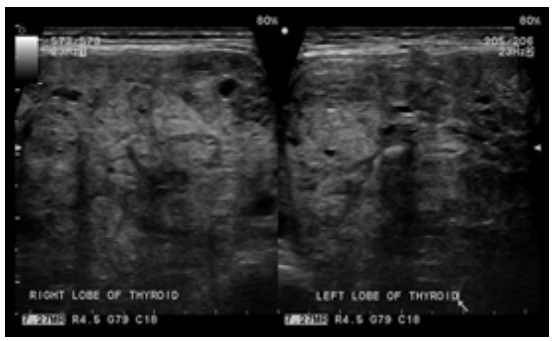

1 A:USG shows diffusely enlarged gland with heterogeneous ecotexture with multiple small hypoechoic nodules

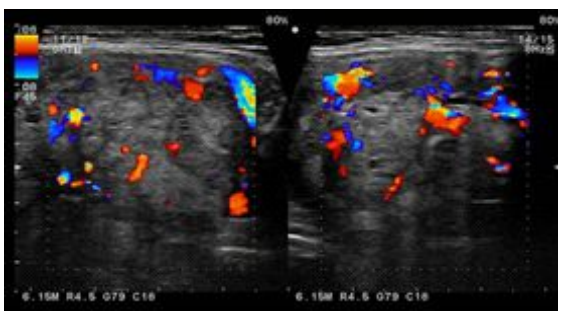

3 B: On Doppler moderate internal vascularity was noted.

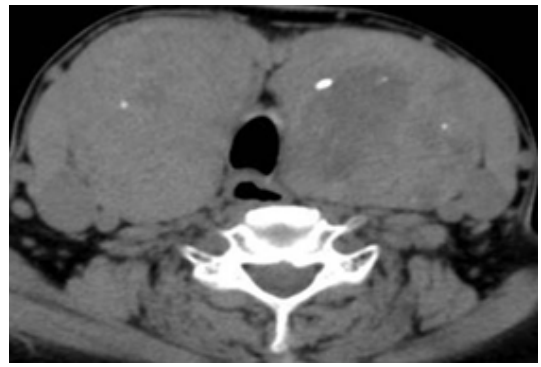

3 C: Bilateral enlarged thyroid lobes and calcific specks within on non contrast scan.

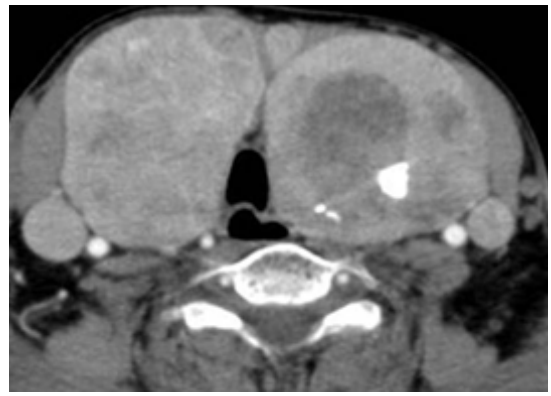

4 D: CECT shows heterogeneous post contrast enhancement with multiple hypodense areas

CASE II: 16 yr male presented with left paramidline neck swelling (Thyroglossal cyst)

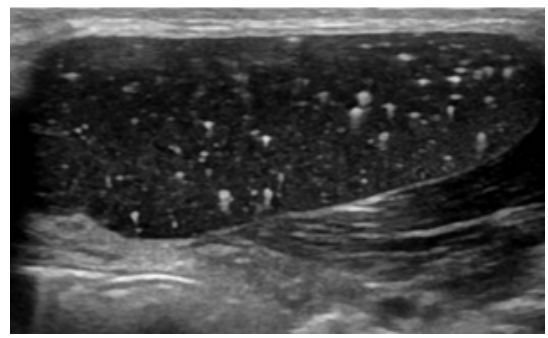

2 A: On USG painless fluctuant midline cystic lesion with thin wall is visualised

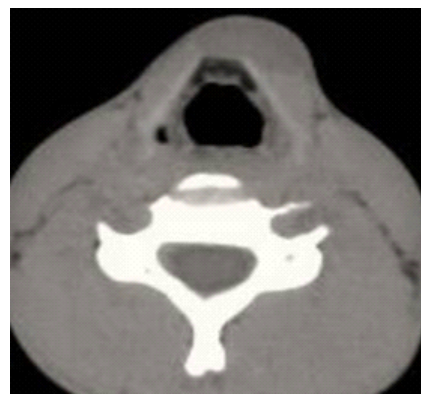

2 B: CT scan shows thin walled, smooth, well defined homogeneously fluid attenuating lesions in left Para-midline location causing splaying of thyroid lamina.

CASE III: 42yrs male presented with swelling over right parotid region. (FNAC: Pleomorphic adenoma)

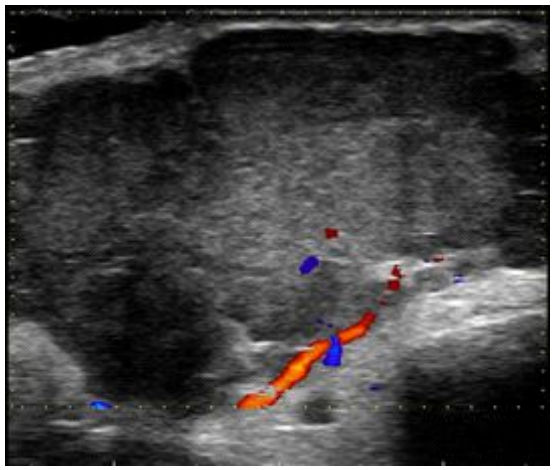

3A: USG shows hypoechoic lobulated mass with posterior acoustic enhancement in right parotid gland with minimal peripheral vascularity.

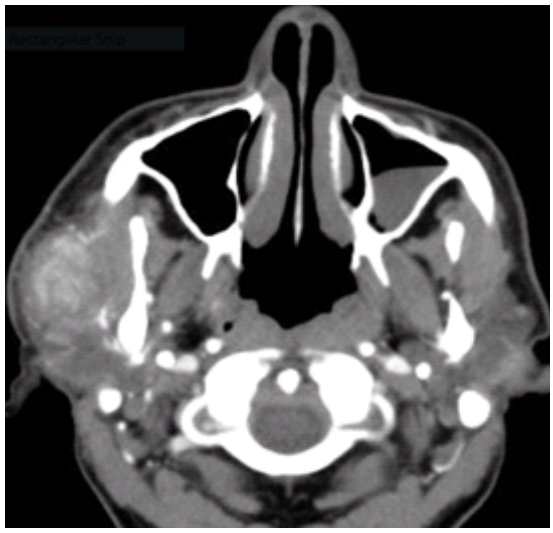

3B: CT scan shows smoothly marginated heterogeneously enhancing soft tissue mass in right parotid

CASE IV: 6yrs female presented with swelling in left parotid region (FNAC: Lymphangioma)

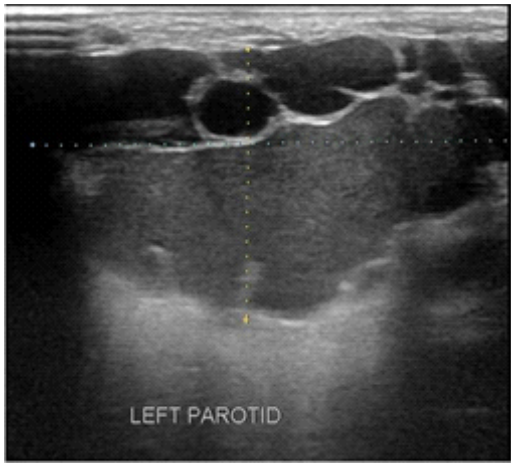

4A: USG shows multiloculated complex cystic lesion seen overlying the left parotid with dense internal echoes within and fluid fluid level, not seen separately from left parotid.

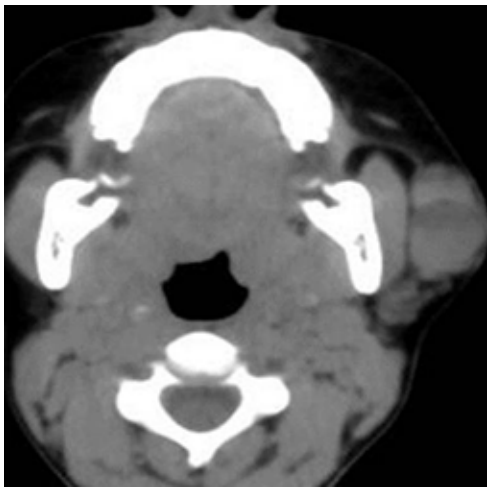

4A: CT scan shows well defined multilobulated iso to hypodense lesion seen overlying the left parotid gland in subcutaneous plane with fluid fluid level and maintained fat plane.

REFRENCES

[1] MOHAMMED AHMED THANDAR, N E JONAS: AN APPROACH TO THE NECK MASS CME MAY 2004, VOL.22, NO.5

[2] ERIC SCHWETSCHENAU,DANIEL J. KELLEY, AMERICAN ACADEMY OF FAMILY PHYSICIANS 2002, ANNUAL CLINICAL FOCUS ON CANCER SEPTEMBER 2002 VOL.66, NO.5

[3] FLOR N, SARDANELLI F, SOLDI S, ET AL. UNKNOWN INTERNAL CAROTID ARTERY ATHEROSCLEROTIC STENOSES DETECTED WITH BIPHASIC MULTIDETECTOR COMPUTED TOMOGRAPHY FOR HEAD AND NECK CANCER. EUR RADIOL. 2006; 16(4):866-871.

[4] BARTZ BH, CASE IC, SRINIVASAN A, MUKHERJI SK. DELAYED MDCT IMAGING RESULTS IN INCREASED ENHANCEMENT IN PATIENTS WITH HEAD AND NECK NEOPLASMS. J COMPUT ASSIST TOMOGR. 2006; 30(6):972-974.

[5] TSENG YC, HSU HL, LEE TH, CHEN CJ. VENOUS REFLUX ON CAROTID COMPUTED TOMOGRAPHY ANGIOGRAPHY: RELATIONSHIP WITH LEFT-ARM INJECTION. J COMPUT ASSIST TOMOGR. 2007; 31(3):360-364.

[6] YOON DY, YOU SY, CHOI CS, ET AL. MULTI-DETECTOR ROW CT OF THE HEAD AND NECK: COMPARISON OF DIFFERENT VOLUMES OF CONTRAST MATERIAL WITH AND WITHOUT A SALINE CHASER. NEURORADIOLOGY. 2006; 48(12):935-942.

[7] FRUSH DP, DONNELLY LF. HELICAL CT IN CHILDREN: TECHNICAL CONSIDERATIONS AND BODY APPLICATIONS. RADIOLOGY 1998; 209:37 48.

[8] AHUJA AT, RICHARDS P, WONG KT, YUEN EH, KING AD. ACCURACY OF HIGH-RESOLUTION SONOGRAPHY COMPARED WITH MAGNETIC RESONANCE IMAGING IN THE DIAGNOSIS OF HEAD AND NECK VENOUS VASCULAR MALFORMATIONS. CLIN RADIOL. 2003; 58(11):869-875.

[9] WONG KT, LEE YY, KING AD, AHUJA AT. IMAGING OF CYSTIC OR CYST-LIKE NECK MASSES. CLIN RADIOL. 2008; 63(6):613-622.

[10] YANG WT, AHUJA A, METREWELI C. SONOGRAPHIC FEATURES OF HEAD AND NECK HEMANGIOMAS AND VASCULAR MALFORMATIONS: REVIEW OF 23 PATIENTS. J ULTRASOUND MED. 1997; 16(1):39-44.

[11] HOHLWEG-MAJERT B, METZGER MC, VOSS PJ, HOLZLE F, WOLFF KD, SCHULZE D. PREOPERATIVE CERVICAL LYMPH NODE SIZE EVALUATION IN PATIENTS WITH MALIGNANT HEAD/NECK TUMORS: COMPARISON BETWEEN ULTRASOUND AND COMPUTER TOMOGRAPHY. J CANCER RES CLIN ONCOL. 2009; 135(6):753-759.

[12] AHUJA A, YING M. SONOGRAPHY OF NECK LYMPH NODES. PART II: ABNORMAL LYMPH NODES. CLIN RADIOL. 2003; 58(5):359-366.

[13] AHUJA AT, YING M, HO SY, ET AL. ULTRASOUND OF MALIGNANT CERVICAL LYMPH NODES. CANCER IMAGING. 2008; 8:48-56.

[14] YING M, AHUJA A, BROOK F. ACCURACY OF SONOGRAPHIC VASCULAR FEATURES IN DIFFERENTIATING DIFFERENT CAUSES OF CERVICAL LYMPHADENOPATHY. ULTRASOUND MED BIOL. 2004; 30(4):441-447.

[15] KOCER N: RADYOLOJIK BIR BULGU OLARAK BOYUN KITLESI: BOYUN KITLESI OLAN BIR HASTANIN RADYOLOJIK INCELEMESINDE DIKKAT EDILECEK NOKTALAR: HANGI GÖRÜNTÜLEME, NE ZAMAN, NASIL? TÜRKIYE KLINIKLERI J SURG MED SCI 2006, 2:10-13

[16] SARAYDAROĞLU O: BOYUN KITLELERINDE PATOLOJIK/SITOLOJIK TANI YÖNTEMLERI: HANGI INCELEME, NE ZAMAN, NASIL? TÜRKIYE KLINIKLERI J SURG MED SCI 2006, 2:20-22

[17] KIM D, WOOK KIM D, BAEK J, LEE Y. COMPUTED TOMOGRAPHY FEATURES OF FOLLICULAR THYROID ADENOMA AND CARCINOMA. JOURNAL OF THYROID DISORDERS & THERAPY. 2016;05:1.

[18] ZHANG J, HU B. SONOGRAPHIC FEATURES OF THYROID FOLLICULAR CARCINOMA IN COMPARISON WITH THYROID FOLLICULAR ADENOMA. JOURNAL OF ULTRASOUND IN MEDICINE. 2014;33(2):221-227.

[19] CHANDAK R, DEGWEKAR S, BHOWTE RR, MOTWANI M, BANODE P, CHANDAK M, ET AL. AN EVALUATION OF EFFICACY OF ULTRASONOGRAPHY IN THE DIAGNOSIS OF HEAD AND NECK SWELLINGS. DENTOMAXILLOFAC RADIOL 2011;40:213-21.

[20] KAMBLE RC, JOSHI AN, MESTRY PJ. ULTRASOUND CHARACTERIZATION OF SALIVARY LESIONS. INT J OTORHINOLARYNGOL CLIN 2013;5:77-90.

[21] GRITZMANN N, SUSANNE N, EVANS N, ABERTAWE M: SONOGRAPHY OF THE SALIVARY GLANDS AND SOFT TISSUE LESIONS OF THE NECK. IN: CHRISTOPH F. DIETRICH, EDITOR. EUROPEAN COURSE BOOK, 1ST ED. STUTTGART: THIEME; 2013. P. 4-22.

[22] THOENY H. IMAGING OF SALIVARY GLAND TUMOURS. CANCER IMAGING. 2007;7(1):52-62.
[23] KRAUS R, HAN B, BABCOCK D, OESTREICH A. SONOGRAPHY OF NECK MASSES IN CHILDREN. AMERICAN JOURNAL OF ROENTGENOLOGY. 1986;146(3):609-613.
[24] REEDE D, BERGERON R, SOM P. CT OF THYROGLOSSAL DUCT CYSTS. RADIOLOGY. 1985;157(1):121-125.
[25] CHARNOFF S, CARTER B. PLUNGING RANULA: CT DIAGNOSIS. RADIOLOGY. 1986;158(2):467-468.
[26] KALRA V, MIRZA K, MALHOTRA A. PLUNGING RANULA. JOURNAL OF RADIOLOGY CASE REPORTS. 2011;5(6).
[27] VAN DEN BREKEL M. LYMPH NODE METASTASES: CT AND MRI. EUROPEAN JOURNAL OF RADIOLOGY. 2000;33(3):230-238.
[28] CHAUDHARY V, BANO S. THYROID ULTRASOUND. INDIAN JOURNAL OF ENDOCRINOLOGY AND METABOLISM. 2013;17(2):219.
[29] HANUMANTHAPPA.M.B., GOPINATHAN S., RITHIN SUVARNA, GURUPRASAD RAI D., GAUTHAM SHETTY, ASHITHSHETTY, BHARGAV SHETTY, NAREN SHETTY. INCIDENCE OF MALIGNANCY IN MULTI-NODULAR GOITRE: A PROSPECTIVE STUDY AT A TERTIARY ACADEMIC CENTRE. JOURNAL OF CLINICAL AND DIAGNOSTIC RESEARCH. 2012; 6(2): 267-270.
[30] SEIFERT G. HISTOPATHOLOGY OF MALIGNANT SALIVARY GLAND TUMOURS. EUR J CANCER B ORAL ONCOL 1992;28:49 –56
[31] ASRANI V, SHAH J. CLINICAL APPLICATIONS OF ULTRASONOGRAPHY IN DIAGNOSING HEAD AND NECK SWELLINGS. JOURNAL OF ORAL AND MAXILLOFACIAL RADIOLOGY. 2017;5(1):7.
[32] DAVID MY, KATHLEEN M. HEAD AND NECK LESIONS. RADIOLOGICPATHOLOGIC CORRELATIONS. RADIOLOGIC CLINICS OF NORTH AMERICA 1998;36 (5): 983-1014.