ORIGINAL RESEARCH PAPER
VOLUME-6 | ISSUE-7 | JULY-2017 | ISSN No 2277 - 8179 | IF : 4.176 | IC Value : 78.46
INTERNATIONAL JOURNAL OF SCIENTIFIC RESEARCH

CYSTIC LESIONS OF THYROID- " A DIAGNOSTIC DILEMMA BETWEEN PAPILLARY CARCINOMA AND BENIGN LESIONS"

Pathology

Reetika Sharma MD Pathology, Resident, Department of Pathology, Indira Gandhi Medical college Shimla, HP. - Corresponding author

Neelam Sharma MD Pathology, Associate Professor, Department of Pathology, Indira Gandhi Medical college Shimla, Shimla, HP.

Vijay Kaushal MD Pathology, Professor & Head, Department of Pathology, Indira Gandhi Medical college Shimla, Shimla HP.

ABSTRACT

Aims: The study cytomorphologic features that distinguish cystic papillary thyroid carcinoma from other cystic thyroid lesions.
Materials and Methods: This study was carried out in the department of pathology in a tertiary care health centre in north India over the period of one year.
Results: Total 70 lesions showed cystic degeneration were included in the study. Out of 70 cases 18 were malignant and 52 were benign. All cystic neoplasm showed histiocytes, multinucleated giant cells and calcification/ crystals. All cystic papillary carcinoma showed papillae, intranuclear cytoplasmic inclusions, nuclear grooves and histiocytoid cells. In addition psammoma bodies (6 cases), mesothelial like cells with windows (5 cases) and clusters with cartwheel pattern (3 cases) and isolated plasmacytoid cells (7 cases) were also observed.
Conclusion: Cystic change is common finding in both benign and malignant lesions of thyroid. However by keen observation and collaborating all cytological, clinical and radiological features we can reach to the diagnosis.

KEYWORDS:

FNAC, cystic lesions, papillary carcinoma, benign lesions

INTRODUCTION

A thyroid nodule is a discrete lesion within the thyroid gland that is palpably and/or sonographically distinct from the surrounding thyroid parenchyma. Thyroid nodules constitute a diagnostic challenge mainly because malignant lesions need surgery and benign lesions are managed conservatively.[1] Thyroid nodules can be detected by palpation in 5% of cases and detection with high-resolution ultrasound (US) ranged between 19 and 67% [2] The annual incidence of thyroid carcinoma is 1-2 per 100,000 population which accounts for 90% of malignanies of the entire endocrine system, 1% of total human malignancies and 0.5% of total deaths from malignancies[3]. Cystic change is seen in both benign and malignant lesions of thyroid and it is a constant diagnostic dilemma in cytology particularly to distinguish papillary carcinoma of thyroid from other benign cystic lesions. The main purpose of this study was to describe the cytological features of cystic papillary carcinoma of thyroid and compare the findings with other thyroid lesions with cystic change.

MATERIALS AND METHODS

This study was carried out in the department of pathology in a tertiary care health centre in north India over the period of one year. A 23-gauze needle was attached to Franzen's handle with 20ml disposable syringe. The slides were stained with May Grunwald Giemsa (MGG).

OBSERVATION

The age of the patients ranged from 17 - 78 years with mean age being 43 years. There was female preponderance, with male to female ratio being 1:6. On cytology total 70 lesions showed cystic degeneration. Out of 70 cases 18 were malignant and 52 were benign. Largest swelling measured 5x4 cm and smallest was 1x1cm. Local examination revealed diffuse thyroid swelling in 30% and nodular swelling in 70% cases. Associated cervical lymphadenopathy was present in 5 cases. All cystic lesions showed histiocytes, multinucleated giant cells and calcification/ crystals. All cystic papillary carcinoma showed papillae, intranuclear cytoplasmic inclusions, nuclear grooves and histiocytoid cells. In addition psammoma bodies (6 cases), mesothelial like cells with windows (5 cases) and clusters with cartwheel pattern (3 cases) and isolated plasmacytoid cells (7 cases) were also observed. (Fig. 1 and Fig. 2)

DISCUSSION

Fine Needle Aspiration (FNA) for cytologic evaluation of thyroid cancer was originally used by Martin and Ellis at New York Memorial Hospital in 1930.[4] The routine use of fine needle aspiration cytology (FNAC) in the assessment of thyroid nodules has reduced the number of patients subjected to thyroidectomy for benign diseases of the thyroid. As a result, the incidence of malignancy in thyroidectomy specimens has increased from 5-10% to 30-50% in the recent years.[5] Cystic change has been identified in many thyroid lesions including papillary thyroid carcinoma (PTC) but this change is far more common in nonneoplastic thyroid nodules than thyroid neoplasms.[6] Adenomatoid (nodular) colloid goiter is the most common cause of a nonneoplastic cystic lesion of the thyroid gland. Among all thyroid cystic lesion approximately 23% are malignant[7]

The cytologic features of papillary carcinoma of the thyroid, both classic and variant types, have been well described. The majority of tumors show classic cytologic features and, in particular, nuclear features.[8] The FNA diagnosis of cystic lesions is quite difficult and at the same time challenging also because of low cellularity, nuclear debris and many pigment laden macrophages. In FNA smears, the presence of histiocyte/macrophages is a surrogate marker for cystic degeneration but these cells may show nuclear atypia and prominent nucleoli mimicking thyroid malignancy, particularly PTC. If squamous metaplastic cells come from benign cyst they can be confused with malignancy.[9]

In this study the features which were common in all cystic neoplasm were presence of histiocytes, multinucleated giant cells (MGC) and calcification/ crystals. It is observerd that MGC in benign nodular goiter tended to be smaller, ovoid, and have foamy cytoplasm and few nuclei. In contrast MGC in PTC cases are more diverse in terms of size, shape, cytoplasm, and number of nuclei. They are larger, ovoid/irregular, and have many nuclei with dense cytoplasm.[10]

In our study all cases of papillary carcinoma showed presence of papillae, intranuclear cytoplasmic inclusions, nuclear grooves and histiocytoid cells. In addition psammoma bodies (6 cases), mesothelial like cells with windows (5 cases) and clusters with cartwheel pattern (3 cases) and isolated plasmacytoid cells (7 cases) were also observed. In the study done by Mokhtari M et al, the most important findings specific to cystic papillary carcinoma were small clusters with scalloped margins, cellular swirls, clusters with a cartwheel pattern and mesothelial like cells forming windows and isolated plasmacytoid cells with dense cytoplasm[9]

One case was misdiagnosed as colloid goitre because of presence of abundant thin colloid but on hisopathological examination it was of micropapillary carcinoma in nodular goitre. This can be explained on the basis that needle might not hit that area which a well known pitfall of FNAC.

CONCLUSION:

In conclusion cytological differentiation between benign lesions and malignant lesion particulary papillary carcinoma is difficult. Papillae with true vascular cores, nuclear inclusions, nuclear grooves are important features of papillary carcinoma but other features like psammoma bodies, plasmacytoid cells with dense cytoplasm, mesothelial like cells with windows, atypical histocytoid cells and large multinucleated cells with dense cytoplasm can add to diagnosis. A cautious approach should be made while seeing any cystic lesion of thyroid and a small suspicion should be mentioned in report for better management of the patient.

Figure Legends :

Figure 1: Cystic papillary carcinoma: 1a; papillary fragments (MGG, 40x): 1b; Multinucleated giant cell adjacent to tumor cells (MGG, 100x) : 1c; multinucleated giant cell with numerous nuclei and deep basophilic cytoplasm (MGG, 400x): 1d; Tumor cells showing cellular swirls(MGG, 400x).

Figure 2 Cystic Papillary carcinoma – 2a; psammoma bodies(MGG, 400x): 2b; Thick colloid with mesothelial like cells/ plasmacytoid cells (MGG,400x). 2c; Clusters of histocytoid like cells with intranuclear inclusion along with pigment laden macrophages (MGG,400x). 2d; clusters of histiocytes in benign cyst (MGG, 400x).

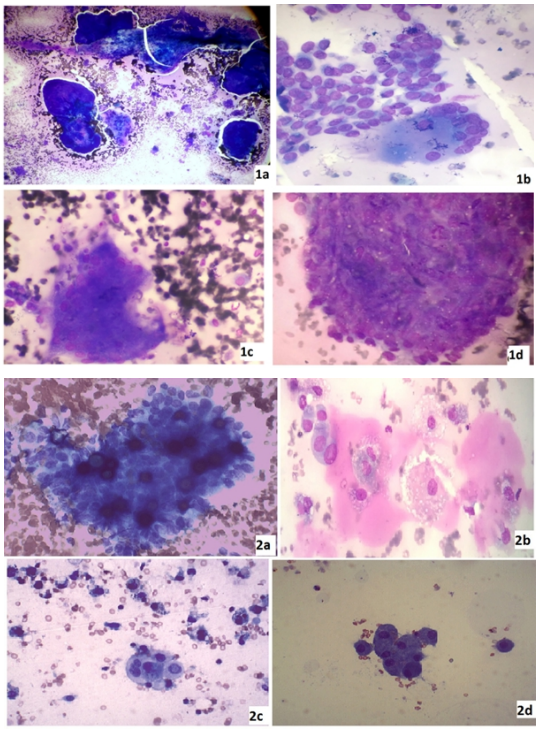

References:

1. Stergios A, Polyzos, Kita M eal. Thyroid nodules. Stepwise diagnosis & management. Hormones 2007;6:101-19.
2. Muratli A, Erdogan N, Sevim S etal. Diagnostic efficacy and importance of fine-needle aspiration cytology of thyroid nodules. J Cytol 2014;31:73-8.
3. Wong CK, Wheeler MH. Thyroid nodules: rational management. World J Surg 2000;24: 934-941.
4. Martin HE, Ellis EB. Biopsy by needle puncture and aspiration. Ann Surg 1930;92:169-81.
5. Handa U, Garg S, Mohan H etal. Role of fine needle aspiration cytology in diagnosis and management of thyroid lesions: A study on 434 patients. J Cytol 2008;25:13
6. Faquin WC, Cibas ES, Renshaw AA. "Atypical" cells in fine-needle aspiration biopsy specimens of benign thyroid cysts. Cancer. 2005;105:71–9.
7. Chandanwale SS, Kumar H, Buch AC etal. Papillary thyroid carcinoma, a diagnostic approach in fine needle aspiration: Review of literature. Clin Cancer Investig J. 2013;2:339–4
8. Renshaw AA. "Histiocytoid" cells in fine-needle aspirates of papillary carcinoma of thyroid: Frequency and significance of an under-diagnosed cytologic pattern. Cancer. 2002;96:240–3
9. Tsou PL, Hsiao YL, Chang TC. Multinucleated giant cells in fine needle aspirates. Can they help differentiate papillary thyroid cancer from benign nodular goiter? Acta Cytol 2002;46:823-7.
10. Mokhtari M, Kumar PV, and Hayati K . Fine-needle aspiration study of cystic papillary thyroid carcinoma: Rare cytological findings. J Cytol. 2016 ;33:120–124.