Research Paper

Volume : 3 | Issue : 7 | July 2014 • ISSN No 2277 - 8179

Cytological Diagnosis of Rhinoscleroma

Medical Science

KEYWORDS : Rhinoscleroma, Mikulicz cells, Klebsiella rhinoscleromatis

Dr. Sushma R. Gulhane	Specialist-cum Assistant professor, Department of Pathology, ESI-PGIMSR & Model hospital, Andheri (E), Mumbai-93
Dr. Madhuri S. Kate	Professor & Head of Department of Pathology, ESI-PGIMSR & Model hospital, Andheri (E), Mumbai-93
Dr. Smita Sonawane	Senior Resident, Department of Pathology, ESI-PGIMSR & Model hospital, Andheri (E), Mumbai-93

ABSTRACT

Rhinoscleroma is a granulomatous infection caused by Klebsiella rhinoscleromatis affecting nose and, other structures of respiratory tract. In general, the diagnosis is based on histological features and microbiological identification of causative agent. The diagnosis is facilitated by cytology of lesion which is easy to perform and minimally invasive procedure. The characteristic Mikulicz cells are observed in smear. This paper presents a case of 45-year old female with a rhinosclerotic granuloma protruding through right nasal vestibule. The diagnosis was done on cytology and confirmed on histology. This patient was treated with the course of ciprofloxacin following excision of mass. She has remained asymptomatic after treatment. There are only two reports up till now describing cytology of this entity. Although diagnosis of this disease is made by tissue biopsy and bacteriology of lesion, the present report indicates that cytology has definite role in its diagnosis

INTRODUCTION

Rhinoscleroma is a chronic granulomatous infection of the upper respiratory tract caused by Klebsiella pneumoniae subsp. rhinoscleromatis.[1] Scleroma may affect any portion of respiratory tract from nose to the trachea-bronchial tree. The disease progresses through three overlapping stages: catarrhal, proliferative and cicatricial. The diagnosis is confirmed on biopsy and by evidencing Klebsiella pneumoniae subsp. rhinoscleromatis in nasal secretions or sometimes in the biopsy specimens.[2]

The disease is endemic in some countries e.g. Central America, Indonesia, some parts of India, Poland, Hungary, Russia and some African countries.[3] There have been many reports in literature but only two of them have described the cytological features of this entity.[4,5] We present a case which was being evaluated for nasal mass and confused with malignancy. It was diagnosed as rhinoscleroma on cytology and confirmed on histology.

CASE REPORT

A female patient aged 45-years, presented with progressive nasal obstruction, yellowish nasal discharge and a mass protruding through the right nasal vestibule since last 1 year. The swelling increased slowly in size and was associated with crustation and bleeding on trivial injury. No other respiratory symptoms or past history of nasal symptoms were present. General examination was within normal limits. On local examination, there was diffuse fullness in right cheek with crustating mass in the right nostril, firm in consistency, with an ill defined border and disfiguring the shape of nose. There was no cervical lymphadenopathy. The otorhino-laryngological examination revealed a violet-colored mass arising from lateral wall of nasal cavity with small ulcers and irregular borders, which extruded from the right nare. The left nasal fossa was obstructed by a deviation of the nasal septum. Hematological and biochemical investigations were in normal range.

Computed tomography of paranasal sinuses revealed a lesion with soft tissue attenuation in the right nasal fossa, maxillary sinus, anterior ethmoid cells and some posterior ethmoid cells. The sphenoid sinus and rhinopharynx were unaltered and no bone destruction was observed.

Patient was referred for fine needle aspiration cytology procedure to rule out nature of the swelling. FNAC was done using 23Gz needle and 10ml syringe. Wet fixed and air-dried slides were made and remaining material was transferred to microbiology laboratory for culture and sensitivity test. Cytology slides were stained with PAP and Giemsa stain. Smears showed aggregates of foamy macrophages in the background of lymphocytes and plasma cells. These macrophages were large in size with central to eccentric vesicular nuclei and indistinct nucleoli.

Fig.1 FNAC smear shows typical mixed inflammatory cell infiltrate of rhinoscleroma consisting of neutrophils, plasma cells and Mikulicz cells (MGG, × 100)

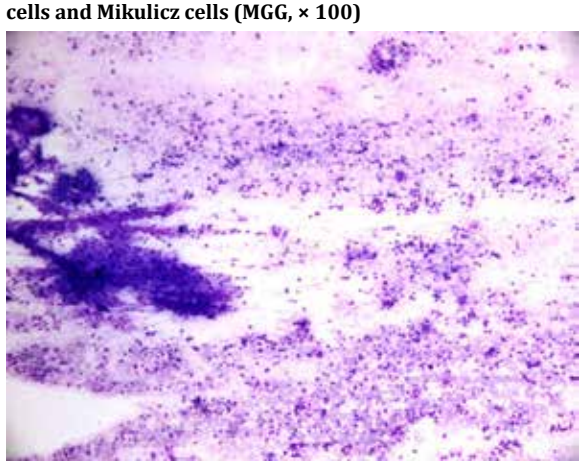

Fig.2 FNAC smear shows Mikulicz cells with foamy cytoplasm in the background of plasma cells, lymphocytes and few neutrophils (MGG, × 400)

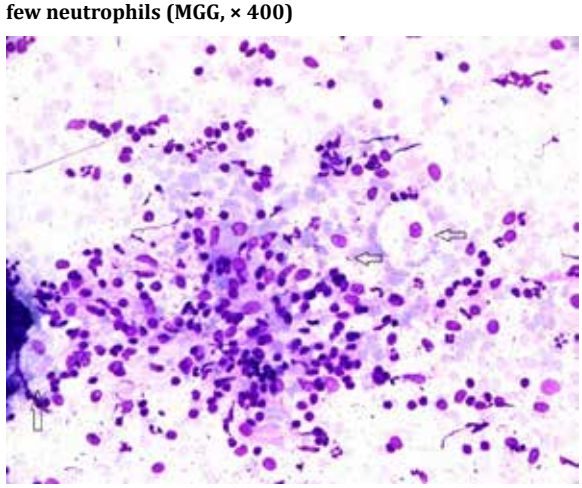

Stains for acid fast bacilli (AFB) & Grocott's silver methenamine were negative. Gram's stain showed an occasional gram negative bacillus within the macrophage. The histiocytes were periodic acid Sciff (PAS) positive. No evidence of emperipolesis was noted. Hence, the report was given as chronic inflammatory polypoidal lesion, most likely to be rhinoscleroma, with suggestion for excision and histological examination for confirmation.

Treatment included surgery followed by antibiotics. Surgical removal of the mass from the nasal fossae was a sinusectomy through the transmaxillary approach with a degloving access route. The specimen referred to pathology for examination was in the form of multiple firm to friable, whitish-pink tissue bits. Histopathology disclosed hypertrophic nasal mucosa with pseudoepitheliomatous hyperplasia at places. Subepithelial zone contained diffuse lymphoplasmacytic inflammatory infiltrate with aggregates of large vacuolated macrophages with central to eccentric vesicular nuclei and indistinct nucleoli, typical of Mikulicz cells. Many plasma cells were seen containing Russel bodies.

Fig.3 Biopsy showing cell infiltrate containing Mikulicz cells, lymphocytes and plasmocytes and Russel bodies

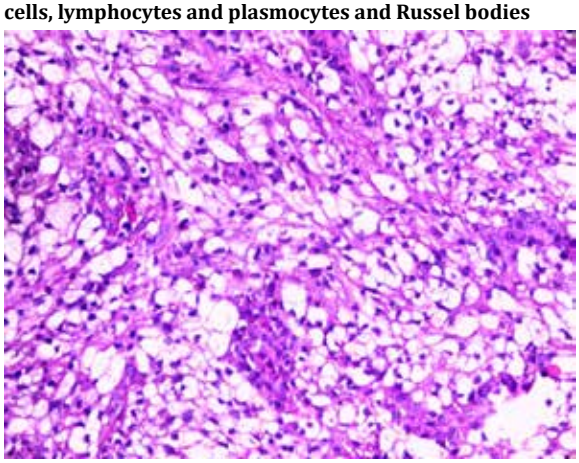

Special stain (PAS) was helpful in aiding the diagnosis. Microbioloical culture established the exact causative micro-organism i.e. Klebsiella rhinoscleromatis.

The patient was treated with the course of ciprofloxacin following excision. She has remained asymptomatic up to the last visit ten months following treatment without any recurrence.

DISCUSSION

Rhinoscleroma is a chronic progressive inflammatory disease of the upper respiratory tract, affecting mainly nasal passages. Infection by the bacterium *Klebsiella rhinoscleromatis* is said to be the cause.[1] The term rhinoscleroma was first used in 1870 by Von Hebra and Kaposi while describing a lesion in the nose which they labeled as sarcoma. The Polish surgeon Johann von Mikulicz in 1877 described the histological features of this disease in detail and established its non-neoplastic inflammatory nature. Von Frisch identified the causative agent of this lesion in 1882 as a Gram-negative coccobacillus, now known as Klebsiella rhinoscleromatis.[2] In 1932, Belinov proposed use of term scleroma respiratorium because the pathological process in rhinosclerosis may involve not only upper but also lower airways. In 1961, Steffen and Smith demonstrated that *K rhinoscleromatis* conformed to Koch's postulates and that it was an aetiologic factor in the inflammatory changes typical of scleroma.[6]

Rhinoscleroma is widely but unevenly distributed throughout the world, often occurring in specific geographical areas.[2] The occurrence of familial disease suggests that genetic control of the host response to *K rhinoscleromatis* may be an important factor in endemic areas. The regions of endemicity are tropical Africa, India, Southeast Asia, Central and South America, and Central Europe.[3] It usually affects people with lower socio- economic status, and is associated with lack of hygiene and prolonged contact with infected patients.[6]

Rhinoscleroma usually affects the nasal cavity, but lesions in larynx, nasopharynx, oral cavity, paranasal sinuses, or soft tissues of lips, nose, trachea, and bronchi are also seen. Ninety-five percent of scleromas are located in the nasal fossae. The disease initially involves the nasal mucosa but may progress to any part of the airway. Extension to the adjacent skin has also been reported.[2, 6] The most common complaint is nasal obstruction, followed by rhinorrhea, epistaxis, dysphagia, stridor, and dysphonia. The major deleterious effect of rhinoscleroma is the airway obstruction, which requires endoscopic treatment.[7]

Rhinoscleroma is more frequent in second or third decades of life and in people living in crowded rural areas, with poor hygienic and nutritional conditions such as iron deficiency anemia.[7] A definite female preponderance is observed. The presence of *K. rhinoscleromatis* is not enough for the development of the disease, as contact of the patient with healthy individuals for many years may not necessarily bring about infection in the latter. This has led to the suggestion that susceptibility of the host is important in development of the disease. Cellular immunity is impaired in patients with rhinoscleroma; however, their humoral immunity is preserved.[6]

Rhinoscleroma is usually divided clinically and pathologically into three stages, namely: catarrhal (inflammatory), proliferative (granulomatous), and fibrotic (sclerotic). The histological findings are more characteristic and diagnostic in the proliferative stage. The catarrhal stage has no specific features that a pathologist can recognize. If clinically suspected, a nasal swab for culture to isolate the microorganisms would confirm the diagnosis. Clinically, the differential diagnoses include all ulcerative and destructive lesions of the upper respiratory tract and oral cavity.[2,6]

The patient in our case had a swelling that extruded from right nare. It was typically a proliferative stage lesion. The first diagnosis, however, was of a neoplasm, although granulomatous diseases had not been excluded. Hence, FNAC was done rather than a preoperative biopsy. Frequently in these cases biopsies may not provide a final diagnosis, due to secondary contamination and insufficient material. Smears showed presence of many foamy macrophages i.e. Mikulicz cells in the background of lymphocytes and plasma cells. Histological examination of the operated tissue confirmed the diagnosis of rhinoscleroma.

Much previous literature is not available about cytology of rhinoscleroma. Only two reports have described cytological features of this disease.[4,5] On histology a cell infiltrate containing lymphocytes and plasmocytes including Mikulicz cells and Russel bodies is highly suggestive of rhinoscleroma. The cytological differential diagnoses of proliferative stage rhinoscleroma include lepromatous leprosy, malakoplakia, granular cell tumour and metastatic renal cell carcinoma.[2] The polymorphonuclear microabscesses and vascular proliferation are not features of leprosy. Furthermore, Mycobacterium leprae can easily be demonstrated by the Ziel-Neelsen stain. The Mikulicz cell is a histiocyte, as demonstrated by light microscopy, electron microscopy and enzyme histochemistry. It probably starts as a histiocyte with eosinophilic cytoplasm and later becomes vacuolated. If the cells with eosinophilic cytoplasm predominate, malakoplakia and granular cell tumour enter into differential diagnoses. When Mikulicz cells are arranged in small groups, they might superficially resemble renal cell carcinoma.

Mikulicz cells are vacuolated histiocytes with clear cytoplasm containing the bacillus. Klebsiella rhinoscleromatis can be demonstrated in haematoxylin and eosin-stained sections. Some authors found Warthin-Starry the most helpful type of stain as it stained the organisms black, leading to easier detection.[8] The chronicity of rhinoscleroma may be explained on the fact that, in this condition T-cell subtypes are diffusely distributed, freely admixed and not segregated. As a consequence, there is ineffective epithelioid cell transformation and impaired granuloma formation, leading to inadequate elimination of the causative organism.[9]

Antibiotic treatment is used as a single treatment to eradicate the infection in the catarrhal stage, or as an ancillary treatment to surgery in other stages of the disease to avoid complications. Untreated rhinoscleroma tends to progress slowly over many years, characterized by periods of remissions and relapses.[9]

CONCLUSIONS

Rhinoscleroma is a rare condition in our country and frequently is difficult to diagnose on cytological examination. A cell infiltrate containing lymphocytes and plasmocytes including Mikulicz cells and Russel bodies is highly suggestive of scleroma. The differential diagnosis should be made with granulomatous diseases, leprosy and tuberculosis, all of which may be identified with specific histopathological techniques.

There are very few cytological references of this disease. The cytological features described as above would arose a suspicion and alert the pathologist to rule out this entity. However, the final diagnosis is given based on histopathological findings and the clinical history. Early diagnosis based on cytology will significantly reduce the morbidity caused by this disease.

AKNOWLEGMENT

We acknowledge Dr. M. Mathur, Dean ESI-PGIMSR for her kind support and guidance.

REFERENCE

1. Rhinoscleroma: a retrospective study of pathologic and clinical features. Zhong Q, Guo W, Chen X, Ni X, Fang J, Huang Z, Zhang S. J Otolaryngol Head Neck Surg. 2011;40(2):167-74. | 2. Rhinoscleroma: a clinicopathological study from the Gulf region. Abalkhail A, Satti M B, Uthman M A E, Al Hilli F, Darwish A, Satir A. Singapore Med J 2007;48(2):148-151. | 3. Rhinoscleroma: Case Report. SimonsI ME, GranatoII L, Claudio R, OliveiraII B, et al. Rev. Bras. Otorhinolaringol. 2006; 72(4). | 4. Cytohistological features of rhinoscleroma. Sood N, Sood S, Arora S, Deepika. Indian J Pathol Microbiol 2011;54:806-8. | 5. Cytologic diagnosis of rhinoscleroma. Zaharopoulos P, Wong JY. Acta Cytol 1984;28(2):139-42. | 6. Septal rhinoscleroma. Mohamed A. Shoeib. Indian J Plast Surg. 2010;43(2):219–221. | 7. Laryngeal Scleroma associated with Klebsiella pneumoniae subsp.ozaenae. Champs CD, Vellin JF, Diancourt L, Brisse S, Kemeny JL, Gilain L, and Mom T. J Clin. Microbial. 2005;43(11):5811-5813. | 8. Rhinoscleroma. Hart CA, Rao SK. J Med. Microbiol. 2000;49:395-396. | 9. Rhinoscleroma: an updated experience through the last 10 years. Gaafar HA, Gaafar AH, Nour YA. Acta Otolaryngol. 2011;131(4):440-6. | |