VOLUME-6 | ISSUE-2 | FEBRUARY-2017 • ISSN No 2277 - 8179 | IF : 3.508 | IC Value : 78.46

Desvenlafaxine induced histological changes in placenta of swiss albino mice.

Anatomy

KEYWORDS: serotonin, noradrenaline, syncytial knot

Amrita kumari	Senior Resident, Department of Anatomy, Indira Gandhi institute of medical sciences, Patna
Mandavi singh	Professor and Head, Department of Anatomy, HIMS, Varanasi.
Anand Mishra	Professor, Department of Anatomy, IMS, BHU, Varanasi

ABSTRACT

Introduction: Desvenlafaxine is an antipsychotic drug categorised as dual reuptake inhibitor of serotonin & nor-adrenaline. It inhibits these neurotransmitters in the pre-synaptic cleft & popularly known as SNRI.**Methods:** During our experiment, Desvenlafaxine was given to adult swiss albino mice in the dose of 80mg per kg body wt, for first 6days of gestation (group 2) and from gestation days 1-18 in group 3, after detection of vaginal plug which was designated as day 0 of pregnancy. Controls (group 1) were given equal amount of tap water for the entire period of gestation. **Result:** Placenta of group 2, showed mild parenchymal degeneration and significantly increased number of syncytial knots. Group 3 placenta showed marked thickening and hyalinization of the basal zone. **Conclusion:**Above pathological changes and their consequent interference with fetal blood supply are suggestive of probable role of desvenlafaxine in fetal growth retardation

INTRODUCTION

Desvenlafaxine is categorised as novel antidepressant drug acting via inhibition of uptake of serotonin and norepinephrine in the nerve terminals. It is considered to be the drug of choice for the major depressive, panic and generalised anxiety disorders[1.] Incidence of these disorders found to increase during pregnancy and post-partum period. There is surge of these depressive episodes in the last trimester of pregnancy followed by dramatic increase in new psychiatric episodes post-delivery. As the drug is classified as category C, there is lack of studies suggesting its safety in pregnancy.[2] Placenta is the main connection between fetus and mother so its involvement is very much evident if the drug has deleterious effect. Besides connection it also acts as a barrier to provide partial protection. Many times the treatment is required during pregnancy and lactation period when it becomes essential but desvenlafaxine have various side effects which could affect the mother and thus fetus if given during pregnancy. Looking at the few and inconclusive reports about the teratogenicity and histopathological changes induced by desvenlafaxine in placenta the present study has been undertaken

MATERIAL AND METHORDS.

This study was conducted in the Department of Anatomy, Institute of Medical Sciences, Banaras Hindu University, Varanasi. Adult female swiss albino mice were used in the present study after approval of institutional ethical committee. The animals were kept in polypropylene cages in a room maintained at a temperature of 25±2oc and relative humidity of 50-60%.The mice were fed with pelleted diet and tap water ad libitum. The male mice were kept for mating in evening with female in the ratio of 2:1. Next morning the vaginal plug positive female mice were selected and were given desvenlafaxine in the dose of 80mg/kg body wt via oral route from gestation day 1-6 (Group 2) and gestation day 1 to 18 (Group 3).Group 1 mice received tap water for the entire period of gestation via oral route. All the three group animals were reared and were sacrificed on gestation day 21 after giving deep ether anaesthesia. All placenta were collected, blotted dry and weighed by using digital weighing machine. After careful inspection for any gross abnormalities they were fixed in the neutral formalin.

Later on they were sectioned and stained with haematoxylin and eosin to observe for the micromorphological architecture.

RESULTS

Although no gross malformation was observed in the treated placenta except for significant weight reduction and some haemorrhagic spots. (Table 1)

In histological study placenta of group 1 showed normal 3 zones: chorionic plate, labyrinthine plate and basal plate.(Fig 1)

In histological study placenta of group 2 showed mild parenchymal degeneration and significantly increase in number of syncytial knots. Intervillous spaces were enlarged due to infiltration and pooling of stagnant blood which in turn causes compression of villi. Cellular debris also can be seen.(Fig 2)

Group 3 placenta showed marked thickening and hyalinization of the decidua basalis. Extensive haemorrhage and fibrinoid necrosis were seen as homogenous eosinophilic mass. Parenchymal necrosis and degeneration with increase in the number of vacuolated large giant cell containing hyalinised deposit were also seen. Extensive cytolysis of glycogen cells were observed as darkly pink stained coagulated deposits. Labyrinthine zone showed complete disruption of architecture of the labyrinthine septa indicated by thickened homogenous fibrinoid deposition.(Fig 3)

DISCUSSION

Depression is a common phenomenon seen in the pregnancy which needs active treatment. New concept suggests that nearly all the drug administered during pregnancy will enter the circulation via diffusion. Antidepressants including desvenlafaxine are documented to have extensive trans placental transfer as antidepressantsand its metabolites were detected in umblical vein in 87% of cases[6.](paper on itja)[3,4]The principle metabolite like unchanged desvenlafaxine,des-venlafaxine-o-glucuronide conjugate and unconjugated N-desmethyl metabolite via o-glucuronidation pathway has been postulated as the culprit for the oxidative damage like haemorrhage, fibrinoid necrosis of the placenta.[5,6] Also the Monoamine uptake inhibitors alter the extracellular monoamine concentration. Extracellular serotonin causes the chorionic vein and umbilical artery vasoconstriction in vitro and uterine artery vasoconstriction and fetal hypoxemia in mammals when SNRI is given prenatally.[7,8] Also study has shown that norepinephrine released extracellularly causes extensive vasoconstriction in uterine vascular beds thus enhancing fetal hypoxemia during SNRI use.[9] This hypothesis is substantiated by our study where we observed thickened and hyalinised basal zone and cytolysis of glycogen cells and disruption of trichorial membrane in labyrinthine zone in a dose dependent manner on use of desvenlafaxine. The present result demonstrated definite effect of desvenlafaxine on mice placenta.

Group	Mean ± SD	p- value
Group 1	0.14±0.02	0.012
Group 2	0.11±0.01	
Group 3	0.08±0.00	

Table 1: Weight of placenta (mg)

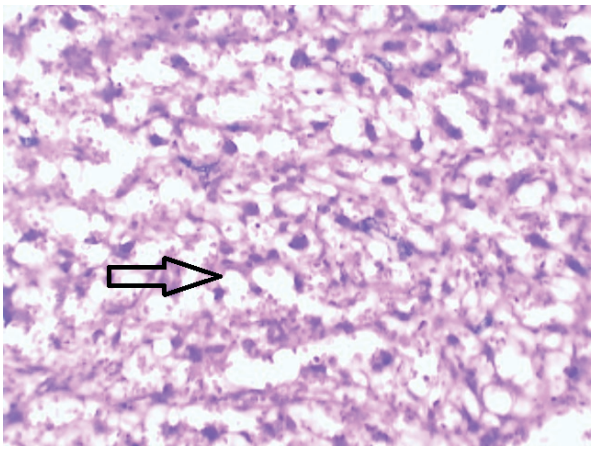

Fig 1: Photomicrograph of Group 1 (control) mice placenta showing normal trichorial membrane (→) and maternal sinusoids in labyrinthine zone (H&Ex400X)

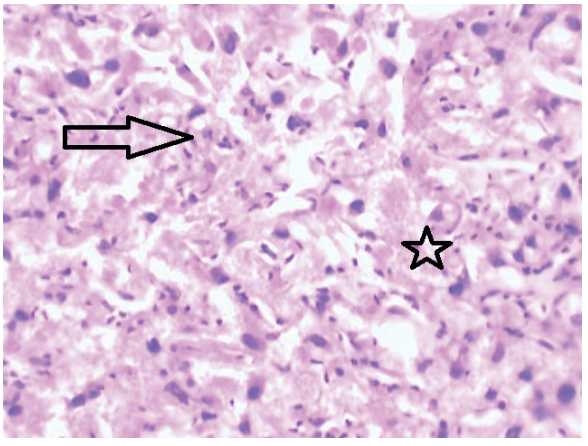

Fig 2: Photomicrograph of Group 2 treated mice placenta showing enhanced syncytial knots and pooling of maternal sinusoids(*) and thickened trichorial membrane(→) (H&Ex400X)

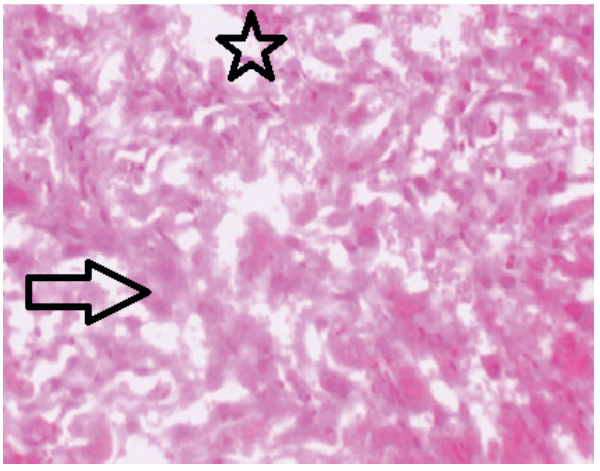

Fig 3: Photomicrograph of Group 3 treated mice placenta showing fibrinoid deposition (→) in and complete disruption of architecture of labyrinthine septa (*) (H&Ex400X)

References

1. Blier P, De Montigny C. Current advances and treatment in depression. Trends Pharmacol Sci 1994;15: 220-226
2. Da Silva VA, Moraes- Santos AR, Carvalho MS, martins MLP. Prenatal and post natal depression in low income Brazilian women. Braz Jour Med Biol Res 1998;31:799-804
3. Deecher DC, Beyer CE, Johnston G. Desvenlafaxine succinate: a new serotonin and nor-epinephrine reuptake inhibitor. J Pharmacol Exp Ther 2006; 318:657-665
4. Palmesten K, Setoguchi S, Margulis AV, Parick AR. Elevated risk of pre-eclampsia in pregnant women with depression: Depression or Anti-depressants. Am J Epidemiol 2012;175:988-995
5. Cooper WO, Willy ME, Pont SJ. Increasing use of Anti-depressants medication during pregnancy. Am J Obstet Gynecol 2007;196:541-545
6. Toh S, Michelle AA, Louik C. Selective serotonin reuptake inhibitor use and risk of gestational hypertension, Am J Psychiatry 2009;166:320-328
7. Cunningham FG, Lenovo KJ, Bloom SL. William's obstetrics 23rd ed. McGraw Hill Companies Inc 2010
8. Ferriera E, Carceller AM, Agogue C. Effect of selective serotonin reuptake inhibitors and venlafaxine during pregnancy in term and pre-term neonates. Pediatrics 2007;119:52-59
9. Gonzalea C, Cruz MA, Sepulveda WH. Effect of serotonin on vascular tone of isolated human placental chorionic veins. Gyecol obstet invest 1990;29:88-91