VOLUME-6 | ISSUE-2 | FEBRUARY-2017 • ISSN No 2277 - 8179 | IF : 3.508 | IC Value : 78.46

Diagnostic accuracy of fine needle aspiration cytology in the diagnosis of Thyroid Lesions

Pathology

KEYWORDS: Fine needle aspiration cytology, Thyroid lesions, Histopathology

Dr Manjula Praveen Biradar — Associate professor, Shridevi Medical college and research institute, Tumkur.

Dr Praveen B Biradar — Consultant pathologist Bhagwan MahaveerJain Hospital Bangalore.

ABSTRACT

Background : Fine needle aspiration cytology(FNAC) is a simple, safe, rapid, minimally invasive, cost-effective diagnostic method for pre-operative investigation of thyroid nodules. The study was carried out to find the diagnostic accuracy of FNAC in thyroid swellings and its correlation with histopathological diagnosis. **Materials and Methods :** A retrospective study of 140 cases was done at MIMS, Mandya from January 2011 to December 2012. The cases for which both cytological and histopathological diagnosis were available was selected. Fine needle aspiration cytology results were compared with histopathological diagnosis following thyroid surgeries. **Results :** Fine needle aspiration cytology diagnosis showed non-neoplastic lesions in 124(88.6%)cases and neoplastic lesions in 16(11.4%) cases. The commonest lesion in the thyroid gland was colloid goiter. Papillary carcinoma was the commnest malignant lesion. Out of 140 cases, histopathological diagnosis was available in 45 cases. Statistical data showed sensitivity, specificity and diagnostic accuracy as 90%,100 and 95.5% respectively to diagnose malignant lesions. **Conclusion :** FNAC of the thyroid is simple, safe, cost-effective and accurate preoperative diagnostic test. Due to its high sensitivity, specificity and diagnostic accuracy early and accurate differentiation between benign and malignant thyroid nodules can be made which significantly reduces mortality as well as morbidity of patients.

Introduction:

Fine needle aspiration cytology(FNAC) is a simple, safe, rapid, minimally invasive, cost-effective diagnostic method for pre-operative investigation of thyroid nodules[1]. As this useful technique is used to differentiate between benign and malignant thyroid nodules, it also reduces the unnecessary surgeries on benign nodules. However, surgical excision and its histopathological examination is the only confirmation for the thyroid lesions. The aim of this study was to find the diagnostic accuracy of FNAC in thyroid swellings and its correlation with histopathological diagnosis.

Materials and Methods:

This was a retrospective study carried out at Mandya institute of medical sciences and research institute and hospital, Mandya, Department of Pathology from Jan 2011 to Dec 2012. 140 patients of all age groups and both sexes who underwent FNAC for thyroid swellings were evaluated. 45 cases for which both cytological and histopathological diagnosis available were taken. Recurrent malignant cases were excluded. After taking consent of patient, FNAC procedure was performed using aseptic precautions with the help of 23-24 guage needle and 10ml syringe. Multiple passes were made through the centre and the periphery of the swellings. Both air-dried and alcohol fixed smears were made, stained with May-Grunwald Giemsa(MGG) and Papanicolaou(PAP) stains respectively. Histopathology slides stained with Haematoxylin and Eosin(H&E) were reviewed. FNAC and histopathology results were classified as neoplastic and non-neoplastic. Pre-operative FNAC results were compared with final histological diagnosis in 45 cases. The sensitivity, specificity, positive predictive value, negative predictive value, diagnostic accuracy of FNAC for detection of malignant lesions was calculated.

Results:

Out of 140 cases, 115(82.14%) were females and 25(17.86%) were males with F:M ratio 4.6:1. Age of the patients ranged from 15-65yrs. Majority of cases were between 32- 50yrs. FNAC showed 124 (88.6%)cases as non-neoplastic and 16(11.4%) cases as neoplastic (Table-1). The most common lesion in the thyroid gland was goiter. Papillary carcinoma was the commonest among malignant lesions(Fig-1). Histopathological diagnosis was available in 45 out of 140 cases. Cytological and Histopathological correlation of diagnosis was done and shown in Table-2. The sensitivity, specificity,positive predictive value, negative predictive value and diagnostic accuracy of FNAC for detection of malignant lesions was calculated and found to be 90%, 100%, 100%, 93.1% and 95.5% respectively.

Table-1: FNAC diagnosis of Thyroid lesions

FNAC diagnosis	Number of patients (%)
Non-neoplastic	**n=124**
Simple colloid goiter	55
Nodular colloid goiter	28
Colloid goiter with cystic degeneration	16
Colloid goiter with adenomatous hyperplasia	13
Hashimoto's Thyroiditis	08
Hyperthyroidism(Hyperplasia)	13
Neoplastic	16
Benign	
Follicular Neoplasm	03
Malignant	
Papillary carcinoma	09
Medullary carcinoma	02
Follicular carcinoma	01
Anaplastic Carcinoma	01
Total	**140**

Table -2: Results of 45 patients of FNAC with histopathological correlation

FNAC Results	Histopathological Findings		Total
	Neoplastic	Non- neoplastic	
Neoplastic	18	00	18
Non-neoplastic	02	25	27
Total	20	2	**45**

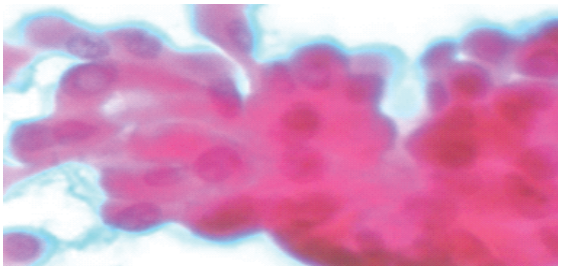

Fig-1: Papillary carcinoma showing nuclear grooving and intranuclear inclusions

Discussion :

FNAC is regarded as the gold standard initial investigation in the diagnosis of thyroid swellings[2]. Other investigations such as high resolution ultrasound(USG), radioisotope scanning and FNA biopsy have been used for evaluation of thyroid swellings before proceeding to surgery. Studies have demonstrated that among all these diagnostic modalities, FNAC is the most accurate and cost effective and screening test for rapid diagnosis of thyroid swellings[3-5]. The sensitivity of thyroid FNAC ranges from 52-93.5%, specificity from 74-99%, and accuracy from 79-94.5%[6-11]. In the present study sensitivity, specificity and accuracy were 90, 100 and 95.5% respectively.

False negative cytology results was seen in 2 cases of our patients. On FNAC it was diagnosed as colloid goiter with cystic change but on histopathology it was diagnosed as Papillary carcinoma. Poor cellularity of the aspirated samples in cystic lesions and suboptimal preparations has been often misinterpreted as benign lesions. These sampling errors may be responsible for under diagnosis of papillary carcinoma as seen in our study also. Occurence of cystic change in thyroid lesions is a common diagnostic pitfall in cytology. In such cases, aspiration from multiple sites, solid areas and USG guidance results in better sample with high overall accuracy.

False negative are of great concern because it indicates potential to miss malignant lesion[12] which may cause delay in treatment and adversely affects the out come in patient with thyroid cancer[13]. There was no false positive cases in our study and is consistent with the other reports that cited rate ranging from 0-9%[14].

Conclusion :

FNAC of the thyroid is simple, safe, cost-effective and accurate preoperative diagnostic test. Due to its high sensitivity, specificity and diagnostic accuracy early and accurate differentiation between benign and malignant thyroid nodules can be made which significantly reduces mortality as well as morbidity of patients. A benign FNAC diagnosis should be viewed with caution, as false negative results do occur and these patients should be followed up and any clinical suspicion of malignancy even in the presence of benign FNAC requires surgery.

References :

1. Tabaqchali MA, Hanson JM, Johnson SJ, Wadehra V, Lennard W, proud G. Thyroid aspiration cytology in New castle: a six year cytology/ histology correlation study. Ann R coll surg Engl 2000; 82:149-55.
2. Cap J, Ryska A, Rehorkova P, Hovorkova E, Kerekes Z, Pohnetalova D. Sensitivity and specificity of the fine needle aspiration biopsy of the thyroid:clinical point of view. Clin Endocrinol 1999;51:509-15.
3. Campbell JP, Pillsbury HC. Management of thyroid nodule. Head Neck 1989;11:414-25.
4. Reeve D, Debridge L, Slaon D, Crummer P. The impact of fine needle biopsy on surgery for single thyroid nodule. Med J Aust 1986;145:308-11.
5. Caruso P, Muzzaferri EL. Fine needle aspiration biopsy in the management of thyroid nodules. Endocrinology 1991;1:194-202.
6. Bouvet M, Feldman JI, Gill GN. Surgical management of the thyroid nodule: Patient selection based on the results of fine needle aspiration cytology. Laryngoscope 1992;102-1353-6.
7. Afroze NI, Kayani N, Hasan SH. Role of fine needle aspiration cytology in the diagnosis of palpable thyroid lesions. Indian J Pathol Microbiol.2002 Jul;45(3):241-6.
8. Ko HM, Jhu IK, Yang SH, Lee JH, Nam JH, Juhng SW, Choi C. Clinicopathologic analysis of fine needle aspiration cytology of the thyroid. A review of 1613 cases and correlation with histopathologic diagnosis. Acta Cytol.2004;47(5):727-32.
9. Kessler A, Gavriel H, Zahav S. Accuracy and consistency of fine needle aspiration biopsy in the diagnosis and management of solitary thyroid nodules. Israel Medical Association Journal 2005;7:371-3.
10. Mundasal B, Mcalliester I, Causon J, Pyper PC. Accuracy of fine needle aspiration cytology in diagnosis of thyroid swelling. The internet Journal of Endocrinology 2006;2:1-4.
11. Gupta M, Gupta S, Gupta VB. Correlation of fine needle aspiration cytology with histopathology in the diagnosis of solitary thyroid nodule. Journal of thyroid research 2010. Article ID 379051, 5pg2010. Doi: 10.4061/2010/379051.
12. Hall TL, Layfield LJ, Philipps A, Rosenthal DL. Sources of diagnostic error in fine needle aspiration of the thyroid. Cancer 1989;63:718-25.
13. Yeh MW, Demircan O, Ituarte P, Clark OH. False-negative fine needle aspiration cytology results delay treatment and adversely affect outcome in patients with thyroid carcinoma. Thyroid 2004;14:207-15.
14. Goldstein RE, Netterville JL, Burkey B, Johnson JE. Implications of Follicular Neoplasms, Atypia and Lesions Suspicious for Malignancy Diagnosed by Fine Needle Aspiration of Thyroid Nodules. Ann Surg 2002;235:656-64.