ORIGINAL RESEARCH PAPER

Volume-8 | Issue-3 | March-2019 | PRINT ISSN No 2277 - 8179

INTERNATIONAL JOURNAL OF SCIENTIFIC RESEARCH

DIAGNOSTIC EFFICACY OF HIGH RESOLUTION MRI SEQUENCE OVER STANDARD PROTOCOL IN EVALUATION OF PATIENT WITH SEIZURES.

Radiodiagnosis

Surg Cdr. Satyendra Narayan Singh Professor & Classified Specialist, Dept of Radiodiagnosis, Base Hospital Delhi Cantt, New Delhi 110010

Col. Sumeet Arora* Associate Professor & Senior Advisor (Radiodiagnosis), Base Hospital Delhi Cantt, New Delhi 110010. *Corresponding Author

Major K Leelakanth Senior Resident, (Radiodiagnosis), Base Hospital Delhi Cantt, New Delhi 110010.

Col. Peeyush Dhagat Professor & Senior Advisor (Radiodiagnosis), Base Hospital Delhi Cantt, New Delhi 110010

ABSTRACT

Introduction : Epilepsy is a chronic condition characterized by recurrent seizures unprovoked by an acute systemic or neurologic insult [1]. Approximately 50 million people worldwide have epilepsy, making it one of the most common neurological diseases globally. With increased awareness of the disease processes, etiopathogenesis, the improved treatment options, availability of the advanced imaging facilities and extensive research from evidence based practice of the medicine, requirement of neuroimaging has been witnessing it unsurpassed past. People with epilepsy respond to treatment approximately 70% of the time. [2].

Aims and Objectives : The aim of the study is to assess diagnostic efficacy of a standard MRI of the brain in patients with seizures and identify whether there is an increase in the diagnostic yield with the addition of high-resolution sequences with a dedicated seizure protocol.

Material and Method : After approval from the Hospital ethics committee, prospective observational study was conducted in the Department of Radiodiagnosis at a tertiary care hospital in New Delhi. The study was conducted to study the MRI patterns of central nervous system pathologies causing seizures with a sample size of 110 patients who presented with seizures. After evaluation with the standard MRI protocol, subjects with normal MRI scan were subjected with high resolution protocol.

Results: A total of 110 patients with history of seizure were enrolled in this prospective study conducted from Jul 2015 to Apr 2017 at a tertiary care hospital in New Delhi with an objective of evaluating the diagnostic efficacy of standard MRI in seizures and increase in the diagnostic yield, if any, with the addition of high-resolution sequences with a dedicated seizure protocol. The diagnostic efficacy with the standard MRI protocol in our study was 42 % and with addition of the "High resolution sequences" to the standard MRI procol sequences, the diagnostic efficacy increased to 53 %.

KEYWORDS

Antiepileptic drug (AED); Arterio-venous malformation (AVM); Diffusion weighted imaging (DWI); Dysembryoplastic neuroepithelial tumour(DNET);Fast Repetition Fast Spin Echo(FRFSE); Fast Spin Echo(FSE);Field of view (FOV);Fluid-attenuated inversion recovery(FLAIR);Focal cortical dysplasia(FCD); Generalised tonic clonic seizures (GTCS); Gradient Echo(GRE);Gradient-recalled echoes (T2*GRE); Juvenile myoclonic epilepsy (JME);Magnetic resonance imaging(MRI); Susceptibility weighted imaging (SWI); T1 weighted image (T2WI); T2 weighted image (T2WI);

INTRODUCTION :

Seizure (from the Latin sacire , 'to take possession of') is a paroxysmal event due to abnormal, excessive, hypersynchronous discharges from an aggregate of central nervous system neurons, due to loss of normal regulation of neuronal excitation and inhibition [1]. Epilepsy is a chronic condition characterized by recurrent seizures unprovoked by an acute systemic or neurologic insult [1,2]. Approximately 50 million people worldwide have epilepsy, making it one of the most common neurological diseases globally. People with epilepsy respond to treatment approximately 70% of the time. [3]. The estimated proportion of the general population with active epilepsy (i.e. continuing seizures or with the need for treatment) at a given time is between 4 and 10 per 1000 people, with incidence nearly doubling in low and middle-income countries due to the increased risk of endemic conditions such as malaria or neurocystecercosis (4,5); the higher incidence of road traffic injuries; birth-related injuries; and variations in medical infrastructure, availability of preventative health programmes and accessible care. Close to 80% of people with epilepsy live in low and middle-income countries[2,4,5]. 60%-70% percent of patients with newly diagnosed epilepsy enters into long-term remission with AEDs and, in most, on a single medication [3,6,7]. The 30%–40% of patients with difficult to-control epilepsy are more likely to have an underlying structural lesion.[4,8,9] Many medically refractory patients can be effectively treated with surgical resections. [10,11].With increased awareness of the disease processes, etiopathogenesis, the improved treatment options, availability of the advanced imaging facilities and extensive research from evidence based practice of the medicine, requirement of neuroimaging has been witnessing it unsurpassed past(12,13). Magnetic resonance imaging (MRI) is currently the structural imaging modality of choice to assess for the presence of structural abnormalities that may be a cause of the epilepsy(9,14,15).

Aims and Objectives :

The aim of the study is to assess diagnostic efficacy of a standard MRI of the brain in patients with seizures and identify whether there is an increase in the diagnostic yield with the addition of high-resolution sequences with a dedicated seizure protocol.

MATERIALS AND METHOD:

The present study was carried out among patients at a tertiary care centre at Delhi. After approval from the hospital ethical committee and patient's consensus, an observational study was conducted with a sample size of 110 patients, estimated using Master software version 2.0. **The Statistical analysis was performed, m**eans were calculated for continuous variables and proportions were calculated for categorical variables. Difference in proportions was tested by chi square test. A p value <0.05 was considered statistically significant. Convenient sampling technique was used to select the study participants.The study was carried out during the period from May 2015 to Jun 2017.The inclusion criteria were patients of either sex and patients of any age who were referred to MRI for evaluation of seizure and were willing to participate in the study.The e**xclusion criteria** were patients of febrile seizure and post traumatic seizures and patients with routine contraindications to MR imaging: such as metallic fragments within the body (shrapnel's, etc), incompatible metallic implants,cardiac pacemakers, claustrophobia etc.

Patients attending radiology department were initially interviewed regarding their medical history, to identify eligible participant for the study based on the predefined inclusion and exclusion criteria. Patients were explained about the procedure and implication of the study in their own language and written informed consent was obtained before detailed interview and examination. These cases were then subjected initially to detailed history followed by clinical examination which included presenting complaints, history of present illness, relevant past history, occupational history, any medical/ surgical co

morbidities, general physical examination including CNS examination. Cases which were then subjected to MRI using a hospital based standard MRI protocol of the brain. The subjects with normal MRI brain study were subjected to the High resolution MRI protocol. The imaging findings were grouped under the common pathologies of brain. The data was then tabulated on Microsoft Excel spreadsheet in a Master chart and studied for statistical analysis.

Statistical analysis of the data was conducted with the statistical package for the IBM social science system version SPSS 24.0. Continuous variables are presented as mean SD, and categorical variables are presented as absolute numbers and percentage. Nominal categorical data between the groups were compared using Chi-squared test or as appropriate. For all statistical tests, a p value of less than 0.05 was taken to indicate a significant difference. Study was conducted on GE HDX 1.5 Tesla MRI machine and Image analysis was done using the image processor AW MR Advantage Windows 4.4 volume share, which has multiplanar reconstruction capability.

MRI protocol:-

Standard MRI Protocol

Sequences for the study at our centre included following sequences :

- Localizer sequences in axial, oblique sagittal and oblique coronal planes.
- Coronal Oblique : T2FRFSE
- Sagittal Oblique: T2FRFSE,
- Axial: T1FSE, T2FRFSE , T2 GRE, DWI, T2FLAIR

High resolution protocol

Sequences in addition to the standard pulse sequences:
Oblique coronal T2 thin (slice thickness 3 mm) for hippocampus.
T1 3D Bravo thin coronal (slice thickness 1.2 mm),
3D FSPGR sagittal (slice thickness 1.2 mm).
Post contrast 3D FSPGR sagittal

The 3D MRI sequences were subjected to appropriate 3D post processing reconstruction including multi planar reconstruction (MPR), maximum intensity projections .

Results: In our study total of110 participants who underwent MRI, 63 (57 %) MRI scans were normal & rest 43 % showed positive MRI findings All the 63 subjects with normal MRI findings on standard MRI protocol were subjected to the high resolution protocol. On inclusion of high resolution protocol to the standard protocol, there were 12 additional subjects who were initially negative, showed positive epileptic foci. There was increase in diagnostic yield of MRI from 42.7 % with standard MRI to 53.64% with High resolution MRI.

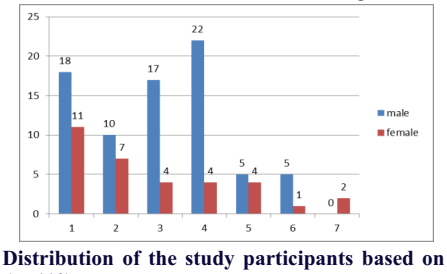

Fig 1: Distribution of the study participants based on age and gender (n=110)

Age and Gender distribution - Majority of the study participants 26 % were in the age group of less than 10 years, with 70 % males and 30 % are females.

Tab/Fig 2: Distribution of study participants based of clinical diagnosis clinical diagnosis.		
Clinical diagnosis	No. of patients	Percentage
GTCS	90	82
Myoclonic seizures	9	9
Absence seizures	1	1
Simple partial seizures	5	4
Complex partial seizures	3	2
Temporal lobe seizures	1	1
Atypical febrile seizures	1	1
Total	110	100
* Most common clinical diagnosis among the participants was generalised tonic-clonic seizure (n=82 %)		

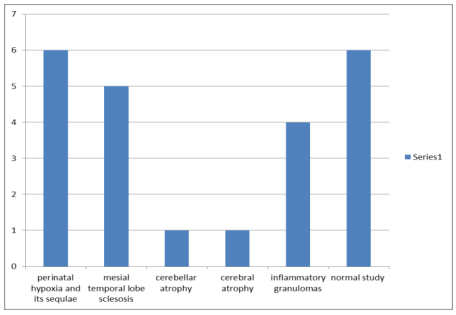

Tab/Fig 3: Etiology - Recurrent seizures among study participants

Tab/Fig 4: Spectrum of MRI findings in the subjects.		
MRI findings	Frequency (n)	Percentage (%)
Vascular events and gliosis	8	18
Neurocysticercosis	13	30
Cerebral atrophy	2	5
Cavernoma	1	2
Heterotopias	2	5
Polymicrogyria	1	2
PRES	1	2
Meningioencephalitis	4	9
Demyelination	2	5
Carbon monoxide poisoning	1	2
Asymmetric ventricles	2	5
Hydrocephalus	2	5
Neoplasm	1	2
Arachnoid cyst	1	2
Absent septum pellucidum	1	2
Gyral swelling	1	2
White matter changes	1	2
* Neurocysticercosis (30%) is the most common MRI finding seen in the participants followed by vascular events and gliosis (18 %).		

Tab/Fig 5: Positivity of the MRI in the study participants & increase in diagnostic yield with addition of high resolution MRI.

	Standard MRI Protocol	High resolution MRI protocol
	n(%)	n(%)
Number of participants	110(100%)	110(100%)
Normal study	63 (57%)	51 (46%)
Positive MRI	47 (43%)	59 (54%)

Tab/Fig 6: Positivity of the MRI in the study participants & increase in diagnostic yield with addition of high resolution MRI.

Standard MRI		High resolution MRI	
Epileptogenic focus n=110		Epileptogenic focus n=63	
Present	Absent	Present	Absent
47 (42.7%)	63(57.3%)	12(19 %)	51(81%)
Total 110		Total 63	

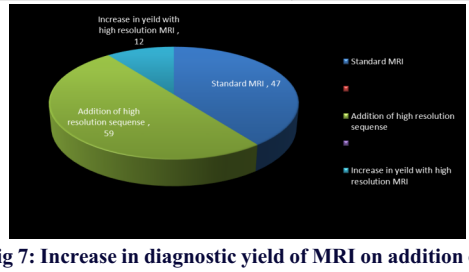

Tab/Fig 7: Increase in diagnostic yield of MRI on addition of high resolution sequences:-

Tab/Fig 8: Chi-Square Tests			
	Value	df	Asymptotic Significance (2-sided)
Pearson Chi-Square	110.000a	2	.000
Likelihood Ratio	150.157	2	.000
N of Valid Cases	110		
* a. 0 cells (0.0%) have expected count less than 5. The minimum expected count is 5.13.			



Fig 9 (a)



Fig 9 (b)

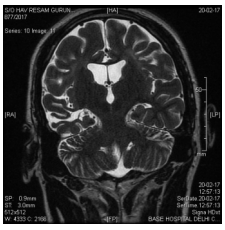

Fig 9 (a),9(b) & 9 (c). Oblique hippocampal 3 mm T2W1 and Sag 1.2 mm FSPGR in a 17 yr old male. There is generalized loss of deep white matter and the thinning of the cortex with prominent sulcul spaces predominantly in right temporal lobe.Atrophy of the body of the right hippocampus and corpus callosum.
Final Diagnosis: Hypoxic ischemic encephalopathy

Fig 9 (c)

Tab/Fig 10:



Fig 10 (a)

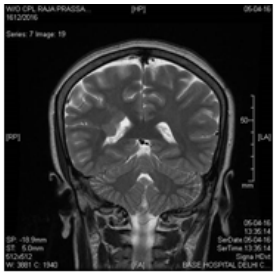

Fig 10 (b)

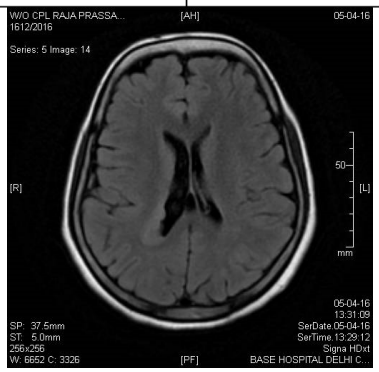

Fig 10 ©

Fig 10 (a) Post Contrast Sag (FSPGR), Fig 10 (b) -Cor T2W1 & Fig 10 (c) -Axial T2W1 FLAIR in a 28 Yrs old female with history of recurrent seizure shows subependymal gray matter nodular heterotopias in the right lateral ventricle.

Tab/Fig 11

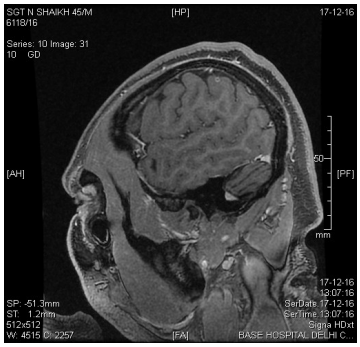

Fig 11. Post GD- FSPGR –Showing 4.2 mm ring enhancing lesion in post central gyrus on right side. This lesion was missed on standard MRI protocol.

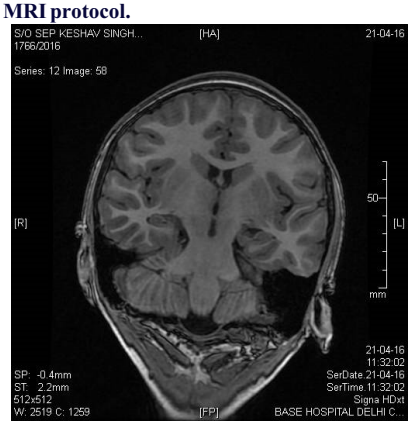

Tab/Fig 5. Cor 3D T1W1 image demonstrating superior image contrast and gray white matter differentiation in a normal brain.

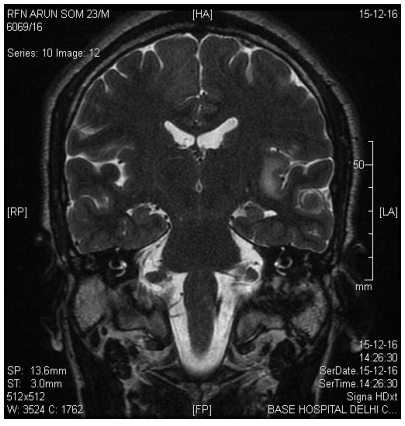

Tab/Fig 13: Cor T2W1 hyper intensity in the left insular cortex in a 23 Yrs old male patient with history of seizure. (No post contrast enhancement /restriction of diffusion /blooming seen images not provided) – low grade astrocytoma was considered as provisional diagnosis.

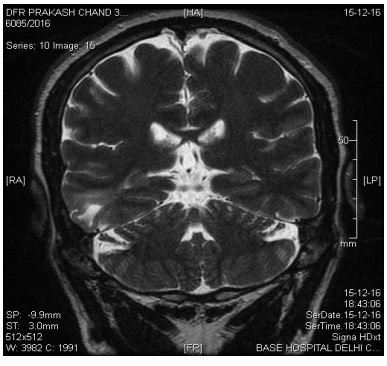

Tab/Fig 14: Oblique Cor T2W1 - in a 34 yr old male patient with history of seizures – hyper intensity SOL in the right temporal lobe rest of the imaging features are s/o –Low grade astrocytomas/ DNET/ ganglioma.

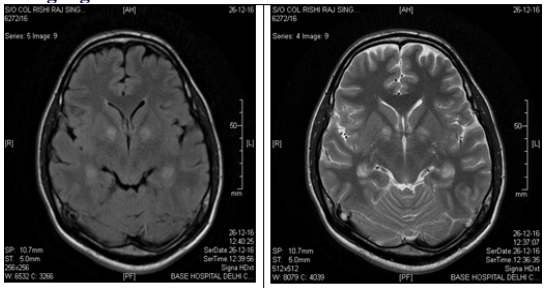

Fig 15 (a) & 15(b) Axial T2 FLAIR and T2WI shows symmetrical hyper intense signal intensities in Globus Pallidus, hippocampus and posterior temporal gyri bilaterally in a 17 Yrs old male with

history of seizure and loss of consciousness after sleeping in a closed space with heater on – CO poisoning was considered as provisional diagnosis.

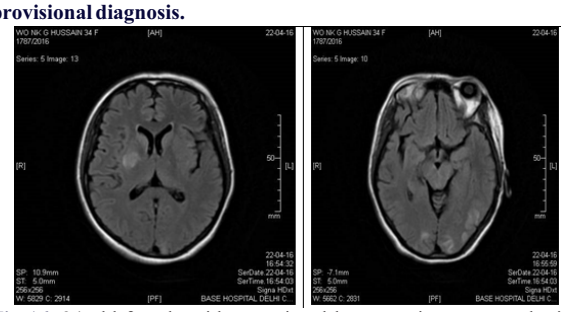

Fig 16. 34 old female with gestational hypertension presented with post-partum seizures with diminution of vision - Axial T2WI & FLAIR images showed hyper intensity in the right basal ganglia and asymmetrical hyper intensity in the bilateral parieto-occipital regions in a 34 yr old female in post-partum seizures. Patient was a known case of gestational hypertension –PRES was considered as provisional diagnosis

DISCUSSION :

- A total of 110 patients with history of seizure were enrolled in this prospective study conducted from Jul 2015 to Apr 2017 at a tertiary care hospital in New Delhi with an objective of evaluating the diagnostic efficacy of standard MRI in seizures and increase in the diagnostic yield, if any, with the addition of high-resolution sequences with a dedicated seizure protocol. The diagnostic efficacy with the standard MRI protocol in our study was 42 % and with addition of the "High resolution sequences" to the standard MRI procol sequences, the diagnostic efficacy increased to 53 %. The study population catered for both the sexes, however majority of them are males (70%). With 61% of patients in the present study were in age group of less than 30 years. Solitary seizure was the common presentation and was 79% among the participants were referred with clinical diagnosis of solitary seizure against 21 % with recurrent seizures.The study reveals that standard MRI is a useful non-invasive modality having moderately high sensitivity, specificity and accuracy in the diagnosis of seizure pathology because of the tissue contrast between the gray and white matter with high spatial resolution. Amongst these participants 58 % of males and 66 % of females in the age group of less than 30 yrs shows abnormal findings.
- In our study, the leading causes of seizure in the participants were inflammatory granulomas (30 %) and vascular events with resultant gliosis (18 %).
- Hypoxia and its sequalae were found to have high incidence in the age group of less than 10 yrs and inflammatory granulomas were higher in incidence in 20-30 yrs age group.
- Among the 110 participants 47 (42%) shows abnormal findings and 63 (58 %) shows normal scan with the standard protocol. On rescanning the 63 participants with high resolution protocol 12 participants shows abnormal findings.
- Among the study participants 23 (21%) who presented with recurrent seizures (at least 02 episodes) the most common findings were vascular events and gliosis (26 %) and inflammatory granulomas (21%), followed by the mesial temporal lobe sclerosis (17 %). No gender preponderance was found for any of the pathologies encountered in the studies.
- Encephalomalacia gliosis with loss of neuroparenchyma and ex-vacco dilatation of the corresponding ventricular system were most frequent findings among the participants in less than 10 years.
- Among inflammatory granulomas, neurocystecercosis was the most frequently seen etiological agent.
- The results of the study were comparable with the existing literature available on the subject.(16 -22)

Teaching Point :

MR imaging is a superior neuroimaging modality with no radiation exposure and should be the first investigation of choice with seizure. Its ability in identifying subtle lesions, location, extent of the lesions and amount of findings with tissue contrast adds sensitivity and specificity in evaluation of seizures.Addition of the high resolution protocol to the standard protocol increases the sensitivity of MRI in evaluation of the seizures to confirm or rule out any organic or developmental lesions.

Recommendations of the study

- MRI is recommended in people with new onset of seizures for the identification of underlying pathologies and to aid in the formulation of syndromic and etiological diagnoses.
- It is recommended to add high resolution 3D sequences and oblique hippocampal T2W1 to increase the diagnostic yield of the MRI.

Financial support and sponsorship: Nil
Conflicts of interest: There are no conflicts of interest

REFERENCES

1. Harrison's principles of internal medicine 16th edition volume II chapter seizures and epilepsy by Daniel H. Lowenstein page no 2357.
2. Kasasbeh A et al. Association of MRI Identification of Mesial Temporal Sclerosis with Pathologic Diagnosis and Surgical Outcomes in Children Following Epilepsy Surgery. J Neurosurg Pediatr. 2012 May; 9(5): 552-61.
3. The International League Against Epilepsy, Committee for Neuroimaging, Subcommittee for Pediatric. Guidelines for Imaging Infants and Children with Recent-Onset Epilepsy. Epilepsia 2009 Sep; 50(9): 2147-53.
4. Trishit Roy, Alak Pandit et al. Neuroimaging in epilepsy.Ann Indian Acad Neurol. 2011 Apr-Jun; 14(2): 78–80.
5. U C Wieshmann et al. Clinical application of neuroimaging in epilepsy. J Neurol Neurosurg Psychiatry. 2003;74:466–470.
6. Zhang YZ et al. Hippocampal volume in children with temporal lobe epilepsy compared to healthy children: a magnetic resonance imaging study. Neurol India. 2012 Jan-Feb;60(1):29-35.
7. Ravindernath, Vishal Singh ; Role of MRI in evaluation of seizures. IAIM, 2016; 3(12): 127-136.
8. Kushwah APS et al.Role of MRI in evaluation of seizures. Journal of Evolution of Medical and Dental Sciences. 2015; Vol. 4, Issue 105, December 31; Page: 16977-16983.
9. Sanjib Sinha et al, Neuroimaging observations in a cohort of elderly manifesting with new onset seizures: Experience from a university hospital. Ann Indian Acad Neurol. 2012 Oct-Dec; 15(4): 273–280.
10. S R Verma et al. Evaluation of non-febrile seizure disorder on MRI with correlation with seizure and EEG Records in a tertiary care teaching hospital. The Internet Journal of Third World Medicine. 2013 Volume 11 Number 1.
11. Shafi Jan MS et al. Spectrum of MRI abnormalities in neonatal seizures in a tertiary care hospital in India. Int J Contemp Pediatr. 2016 Nov;3(4):1150-1155.
12. Blümcke I, Thom M, Aronica E et-al. The clinicopathologic spectrum of focal cortical dysplasias: a consensus classification proposed by an ad hoc Task Force of the ILAE Diagnostic Methods Commission. Epilepsia. 2011;52 (1): 158-74)
13. Barkovich AJ, Kuzniecky RI, Jackson GD et-al. A developmental and genetic classification for malformations of cortical development. Neurology. 2005;65 (12): 1873-87.
14. Kabat J, KróL P. Focal cortical dysplasia - review. Pol J Radiol. 2012;77 (2): 35-43
15. Wu JY, Sutherling WW, Koh S, et al. Magnetic source imaging localizes epileptogenic zone in children with tuberous sclerosis complex. Neurology 2006;66:1270–1272.
16. Kerrigan JF et al.Hypothalamic hamartoma and infantile spasms. Epilepsia 2007;48:89–95.
17. Lee J et al.Maternal and infant characteristics associated with perinatal arterial stroke in the infant. JAMA 2005;293:723–729.
18. Kazemi H et al.Intractable epilepsy and craniocerebral trauma: analysis of 163 patients with blunt and penetrating head injuries sustained in war.Injury 2012; 43: 2132–5.
19. Beghi E et al. Incidence and predictors of acute symptomatic seizures after stroke. Neurology 2011; 77: 1785–93.
20. Lalit Kumar et al. Evaluation of The Role and Utility of Neuroimaging In New Onset Seizures Presenting To The Emergency Department. 2016:; 3(2);.312-315.
21. Pandey RP et al. A Study of Clinical Profile of Seizure Disorder in Geriatric Population Sch. J. App. Med. Sci. Jan 2017; 5(1D):237-243.