ORIGINAL RESEARCH PAPER
Volume-6 | Issue-9 | September-2017 | ISSN No 2277 - 8179 | IF : 4.176 | IC Value : 78.46
INTERNATIONAL JOURNAL OF SCIENTIFIC RESEARCH

DIFFERENTIAL DIAGNOSES OF SARCOIDOSIS AND PRIMARY SJOGREN SYNDROME: A CASE REPORT

Dental Science

Jijin Mekkadath Jayakrishnan — MDS Asst.Professor Department of oral medicine and Radiology, Malabar dental college and research centre, Edappal, Kerala. - Corresponding Author

Hombarvali Puttabuddi Jaishankar — MDS Professor Department of oral medicine and Radiology,JSS Dental college, Mysore, Karnataka.

Shashidara Raju — MDS Professor & HOD Department of Oral pathology and Microbiology ,Coorg institute of dental science, Virajpet, Karnataka.

Libina Isahak — MDS Asst.Professor Department of Pedodontic and preventive Dentistry, Government Dental College Alappuzha.Kerala.

Ramachandran Anjana — MBBS Assistant Surgeon, Primary Health Centre, Kanichar, Kolakkad, Kannur, Department of Health, Kerala.

ABSTRACT

Due to unavailability of diagnostic facilities and resemblance with other diseases such as tuberculosis, Sjogren syndrome, and xerostomia, sarcoidosis is underreported in developing countries, including India. We have reported a 47-year-old woman who presented with dryness of the mouth for past 5 months suggestive of Sjogren syndrome. However, biochemical analysis revealed high level (233 U/L) of angiotensin-converting enzyme, which confirmed the diagnosis of sarcoidosis. The diagnosis was further supported by the presence of noncaseating granuloma and lymphocytic infiltrate on salivary gland biopsy. Also, X-ray and computed tomography of the chest revealed bilateral submandibular lymphadenopathy, which is suggestive of sarcoidosis. Currently the patient is under medication and prognosis is good.

KEYWORDS

Sarcoidosis, Sjogren syndrome, angiotensin-converting enzyme, Computed tomography

Introduction

Sarcoidosis is an inflammatory disease of unknown etiology, which predominantly affects the lungs and lymphatic system leading to granulomas. It also damages the other systemic organs, including the heart, liver, skin, and eyes.[1-2] The clinical symptoms, disease history, and prognosis of sarcoidosis vary depending on the affected organ and the course is often unpredictable.[3] Sarcoidosis affects all racial and ethnic groups and occurs at all ages, and usually develops before the age of 50 years.

The prevalence of sarcoidosis is high in western countries. In northern European population, highest annual incidence (5–40 cases/100,000 population) of sarcoidosis was observed.[4] In American population, black Americans (35.5 cases per 100,000) are more affected than whites (10.9 cases per 100,000).[5] In contrast, very few epidemio logical reports on sarcoidosis from Indian population are available. According to Kolkata respiratory unit, [10–12] new cases/1000 population were registered annually. Another report from Vallabhbhai Patel Chest Institute (VPCI), Delhi estimated 61.2 cases per 100,000 population.6 However, sarcoidosis is underreported in developing countries, including India due to lack of diagnostic facility and its resemblance with tuberculosis (TB).[7]

In this case study, based on its clinical presentation the patient was initially diagnosed with primary Sjogren syndrome. Later, patient was differentially diagnosed with drug-induced xerostomia, hyperpa rathyroidism, and sarcoidosis. Finally, with the help of imaging and biochemical analysis, diagnosis was confirmed as Sarcoidosis. Currently, the patient is under ascorbic acid supplemen tation and prognosis was found to be good.

Case report

A 47-year-old woman visited the Department of Oral Medicine and Radiology, Coorg Institute of Dental Sciences, Virajpet, Karnataka, India with complaints of dryness of the mouth for 5 months (Fig. 1). In the due course, patient had a history of numbness of the lower lip, difficulty in chewing and swallowing solid food items, and dryness of the eyes. Patient also complained of food sticking to the oral mucosa during eating, burning sensation after consuming spicy food, and consumption of more water during night-time compared to earlier days. She also had a history of fatigue and loss of 4 kg of body weight in last 2 months. However, no history of blurred vision, light intolerance, changes in the voice, dryness of other mucosa (nasal, laryngeal, and/or genital) was observed. She also had a history of duodenal ulcer, which was treated successfully, and she was under ayurvedic medications for knee pain.

Physical examination of the patient at the time of admission revealed no pallor, no icterus, without cyanosis, clubbing, and edema. She was afebrile and had normal gait with moderate nourishment. Heart rate was 78 beats/min and blood pressure was 140/86 mmHg. No abnormality detected in facial asymmetry; however, bilateral submandibular lymphadenopathy was observed (1.5 × 2 cm), which was mobile firm in consistency, and tender in nature. The labial and buccal mucosa, hard palate, and floor of the mouth appeared dry; tongue was depapillated, and generalized prominent gingival recession was observed.

Investigations

Blood test revealed blood glucose level of 94 mg/dL, hemoglobin level of 11.5 gm%, and cholesterol level of 220 mg%. The levels of triiodothyronine (T3), thyroxine (T4), and thyroid-stimulating hormone (TSH) were found to be 88 ng/dL, 6.2 ng/dL, and 2.2 IU/mL, respectively. Urine analysis revealed the absence of protein and sugar. Tests for serum SSA/Ro antibody, serum SSB/La antibody, and antinuclear antibody (ANA) were negative. Serum angiotensin-converting enzyme (ACE) levels were found to be 233U/L (Table 1). Saliva flow was measured using sialometry. Whole unstimulated and stimulated saliva flow rate was 0 mL/5 min.

Microscopic observation of the salivary gland tissue biopsy revealed complete destruction of the acini and presence of numerous noncaseating granuloma with occasional giant cells surrounded by lymphocytic infiltrate replacing the acinar structure (Fig. 2). Computed tomography (CT) imaging of the chest showed multiple small nodules diffused in both of the lungs, predominantly in the upper and middle lobes in perilymphatic distribution. Also, mediastinal and hilar lymphadenopathy were observed (Fig. 3).

Discussion

At the time of admission, patient underwent physical and clinical examination. The results were suggestive of primary Sjogren syndrome which resembles with sarcoidosis. Biochemical analysis revealed normal random blood glucose, hemoglobin, and cholesterol levels. Urine analysis also showed normal values. Sialometry analysis for saliva production showed no saliva production after stimulation. Antibody analysis of SSB/La, SSA/Ro, and ANA was also negative; however, serum ACE level was found to be very high (233U/L), which led us to preliminary diagnosis of sarcoidosis. Further, microscopic analysis of minor salivary gland tissue biopsy revealed complete destruction of the acini and presence of noncaseating granuloma with lymphocytic infiltrate, which further confirmed the diagnosis of sarcoidosis. CT imaging revealed that the patient had bilateral submandibular lymphadenopathy, which is a unique feature of sarcoidosis.

Sarcoidosis affects multiple body organs in which the lungs (~90%) are predominantly affected [3]. Due to its heterogeneity of nature, interpretation of the severity of its condition is difficult. Nevertheless, up to one-third of patients have recurrent chances, which further associated with significant impairment in the quality of life.[8]

The burden of sarcoidosis is not well documented in Indian population due to its clinical resemblance with other diseases such as tuberculosis, xerostomia, and Sjogren syndrome.[7] Lack of diagnostic facility and awareness among physicians and pathologists also leads in misdiag nosis of sarcoidosis. This could be main reason for the unavailability of epidemiological information on this disease.[9]

Few reports have suggested that serum ACE levels can be used as a surrogate marker for the identification of Sarcoidosis.[10] Also, few Indian studies have observed that >70% of patients with sarcoidosis were having elevated ACE levels,[11] as found in this case study (233 U/L). Thus, patients with sarcoidosis should be subjected for labial minor salivary gland biopsy and CT examination to identify noncaseating granuloma and bilateral submanidibular lymphade nopathy to confirm disease condition. This could help to specifically identify the disease, which also help in treating the patient in systematic manner to avoid further disease burden.

Conclusions

In India, sarcoidosis burden is underreported due to lack of diagnostic facility and its resemblance with other disease such as Sjogren syndrome, tuberculosis, xerostomia. Biochemical estimation of ACE levels, histopathological, and radiological correlation may serve as a potential marker for accurate detection of disease, which could be helpful in preventing the disease burden in future



Figure 1: Dryness of the A) tongue and B) mouth

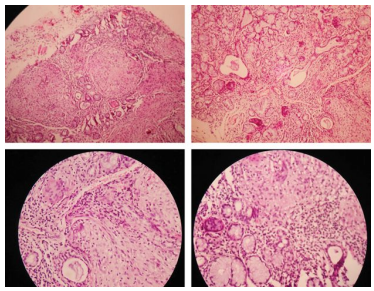

Figure 2: Microscopic observations of minor salivary gland biopsy (left lower labial mucosa) tissue (10x and 40x)

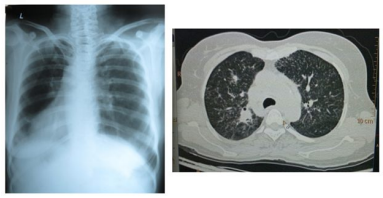

Figure 3: X-ray and CT of chest showing bilateral submandibular lymphadenopathy

Table 1: Demographic and biochemical information of the patient

Characteristics	Results
Age (years)	47
Sex	Female
RBS (mg/dL)	94
HB (gm%)	11.5
Cholesterol (mg%)	220
T3 (ng/dL)	88
T4 (ng/dL)	6.2
TSH (U/mL)	2.2
SSA/Ro antibody serum	Negative
SSB/La antibody serum	Negative
ANA	Negative
ACE (U/L)	233
SBP (mm HG)	140
DBP (mm HG)	86

RBS, random blood sugar; *HB,* hemoglobin; *TSH*, Thyroid stimulating hormone; *ANA,* antinuclear antibody; *ACE*, angiotensin-converting enzyme; *SBP*, systolic blood pressure; *DBP*, diastolic blood pressure

Figure legends

Figure 1: Dryness of the A) tongue and B) mouth
Figure 2: Microscopic observations of minor salivary gland biopsy (left lower labial mucosa) tissue (10x and 40x)
Figure 3: X-ray and CT of chest showing bilateral submandibular lymphadenopathy

References

1. Nunes H, Soler P, Valeyre D. Pulmonary sarcoidosis. Allergy. 2005;60:565-582.
2. Torpy JM, Burke AE, Golub RM. JAMA patient page. Sarcoidosis. JAMA. 2011;305:423.
3. Drent M, Strookappe B, Hoitsma E, De Vries J. Consequences of Sarcoidosis. Clin Chest Med. 2015;36:727-737.
4. Pietinalho A, Hiraga Y, Hosoda Y, Lofroos AB, Yamaguchi M, Selroos O. The frequency of sarcoidosis in Finland and Hokkaido, Japan. A comparative epidemiological study. Sarcoidosis. 1995;12:61-67.
5. Rybicki BA, Major M, Popovich J, Jr., Maliarik MJ, Iannuzzi MC. Racial differences in sarcoidosis incidence: a 5-year study in a health maintenance organization. Am J Epidemiol. 1997;145:234-241.
6. Gupta SK. Epidemiology of sarcoidosis. In: Proceedings of the symposium. Delhi: V.P. Chest Institute 2002:27-31.
7. Kumar R, Goel N, Gaur SN. Sarcoidosis in north Indian population: a retrospective study. Indian J Chest Dis Allied Sci. 2012;54:99-104.
8. De Vries J, Drent M. Quality of life and health status in sarcoidosis: a review of the literature. Clin Chest Med. 2008;29:525-532, ix.
9. Sharma S, Mohan A. Sarcoidosis in India: not so rare. J Indian Acad Clin Med. 2004;5:12-21.
10. Giotaki H, Constantopoulos SH, Papadimitriou CS, Moutsopoulos HM. Labial minor salivary gland biopsy: a highly discriminatory diagnostic method between sarcoidosis and Sjogren's syndrome. Respiration. 1986;50:102-107.
11. Sharma S, Rao D, Pande J, Guleria J. Serum angiotensin-converting enzyme activity in sarcoidosis. Indian journal of medical research. 1987;85:638-644.