Volume : 5 | Issue : 5 | May 2016 • ISSN No 2277 - 8179 | IF : 3.508 | IC Value : 69.48

Research Paper

Diffusion Weighted Magnetic Resonance Imaging Features of Intra And Extra-Axial Intracranial Pathologies

Medical Science

KEYWORDS : DIFFUSION WEIGHTED IMAGING, INTRACRANIAL, TUMOURS

*** Dr. KIRTI TANTIA** — RESIDENT, DEPARTMENT OF RADIO-DIAGNOSIS, S.P MEDICAL COLLEGE, BIKANER
* CORRESPOND AUTHOR

Dr. G.L.MEENA — SENIOR PROFESSOR AND HEAD OF DEPARTMENT OF RADIO-DIAGNOSIS, S.P MEDICAL COLLEGE, BIKANER

ABSTRACT

To discuss the diffusion weighted imaging features of intra and extra-axial intracranial pathologies and to compare them with T2 and T2 FLAIR imaging. Methodology: A descriptive MRI Study was done in 150 patients with intracranial pathologies. In all these patients DWI, ADC, T2 and FLAIR findings were noted. RESULTS: Majority (47%) of cases were infarcts, All acute infarcts, 50% sub-acute infarcts and none of chronic infarcts showed restriction on DWI. In 13% of acute infarcts, no signal change was evident on T2WI. All cases of HIE showed restricted diffusion, while on T2WI, no signal change was seen in 20% cases. 42.85% of tubercular granulomas, 100% of abscesses and 50% of meningoencephalitis showed diffusion restriction while no case of NCC showed restriction. Among intra-axial tumours, 80% medulloblastomas, 40% glioblastoma multiforme and 33.33% metastases showed restricted diffusion but none of the low grade gliomas or anaplastic astrocytomas showed diffusion restriction . Among extra-axial lesions, 14% meningiomas and all epidermoid cysts showed diffusion restriction while none of the schwannomas or arachnoid cysts showed restricted diffusion. No case of PRES and only 25% of demyelinaton cases showed restricted diffusion. CONCLUSION: DWI is an excellent modality for the detection and characterization of infarcts and HIE as compared to T2 & T2 FLAIR. Tumours having high cellularity such as glioblastoma multiforme, medulloblastoma and meningioma may show restricted diffusion. Presence of diffusion restriction is a useful method of differentiating epidermoid cyst from arachnoid cyst and abscesses from necrotic tumours .

INTRODUCTION:

Diffusion-weighted imaging of the brain represents an imaging technique that extends imaging from depiction of neuroanatomy to the level of function and physiology. Image contrast is related to differences in the diffusion rate of water molecules[(1)].

Regions with restricted mobility of water molecules yield a greater DW-MRI signal, appear bright on DWI and dark on ADC image. In ADC images, regions that contain high water mobility appear bright[(2)].

Although DWI is most often used to identify acute arterial ischemia, other processes that interfere with or restrict the movement of water can cause notable changes on DWI, including neoplastic lesion, encephalitis, pyogenic abscesses and occasional demyelinating diseases. Tissues with high cellularity cause increased volume of intracellular space, resulting in diminished mobility of water protons with restriction of diffusion.[3]. So, tumours having high cellularity shows diffusion restriction.

MATERIAL AND METHODS

The data for this hospital based observational descriptive study was collected from patients attending the Radio-Diagnosis department for MRI brain between June 2015 to January 2016.

Patients diagnosed to have any of the following intracranial pathologies on MRI brain: Infarction, Hypoxic ischemic encephalopathy (HIE), Infections, Tumors, Demyelination, metabolic and toxic encephalopathy, Degenerative disorders, were included. Patients who were detected to have intracranial bleed were excluded.

DWI were performed using a Philips 1.5T MRI scanner with Philips windows workstation. Patients underwent the MRI scan after contraindications were excluded and consent was taken.

MRI Protocol consisted of the following:

A head coil was used

Axial DWI, T1W, T2W and FLAIR of the brain

Saggital T2WI of the brain

Axial ADC images.

OBSERVATIONS

150 cases of intracranial pathologies were studied,of which66 (44%) were females and 84 (56%) were males. The age of the patients studied ranged from 5 days to 90 years .

Table 1: Spectrum of Intracranial lesions

Intracranial Lesions	No. of Patients		Total	Percentage
	Intra-axial	Extra-axial		
Infarcts	71		71	47.4%
Infections	21		21	14%
Tumours	23	20	43	28.7%
Demyelination	4		4	2.6%
HIE	5		5	3.3%
Others	6		6	4%

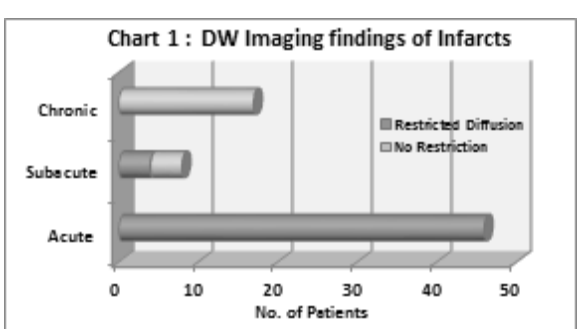

Of the total cases, infarcts were the majority which constituted 71 cases (47.3%). Of this 46 (64.7%) were acute, 17(23.9%) were chronic and 8 (11.2%) were subacute infarcts. All 46 cases (100%) of acute infarcts showed true diffusion restriction .Of these, 40 cases (86.95%)showed hyperintensity on T2W images. The remaining 6 cases (13%) showed no signal change on T2W

Volume : 5 | Issue : 5 | May 2016 • ISSN No 2277 - 8179 | IF : 3.508 | IC Value : 69.48

images. 50% of subacute infarcts showed diffusion restriction while rest 50% of subacute and any of chronic infarcts did not show restriction.

All 5 cases of HIE (3.3%) showed diffusion restriction . 1 case (20%) did not show any change on T2 FLAIR images. The extent of abnormality was noted to be more on DWI than on T2, FLAIR images.

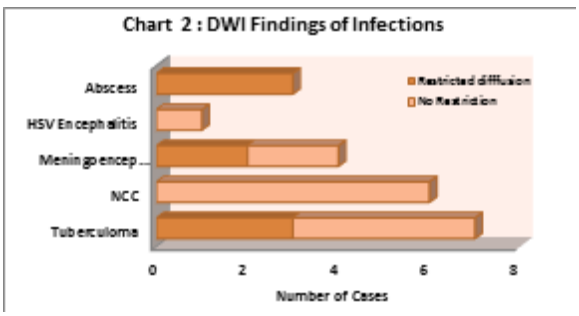

Of 21 infective conditions studied, 7 (33.33%) were tuberculomas, 6 (28.6%) were NCC granulomas, 3 (14.3%) were abscesses, 4 (19.1%) were meningoencephalitis and 1 case (4.7%) was HSV encephalitis. 42.85 % tuberculomas, 100% abscesses and 50% meningoencephalitis showed diffusion restriction.

Table 3: DWI Findings of Infra & Extra-axial Lesions

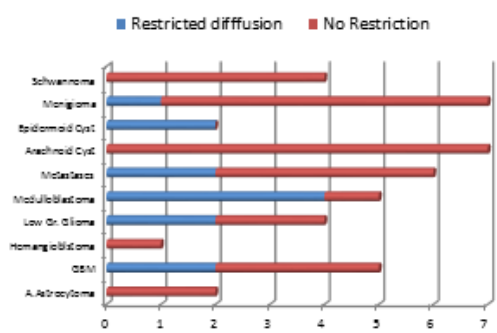

23 cases of intra axial tumors in this study comprised of two anaplastic astrocytomas, five glioblastoma multiforme (GBM), one hemangioblastoma, four low grade gliomas, five medulloblastomas, and six cases of metastases. Seven cases(30.4%) showed true diffusion restriction. Of these were two were GBM, four were medulloblastomas, and two were metastases.

Of 20 cases of extra axial lesions, there were 7 arachnoid cysts, 2 epidermoid cysts, 7 meningiomas and 4 schwannomas. Restricted diffusion was noted in 3 cases (15%). This included all (two) epidermoid cysts and one case of meningioma.

Among four cases of demyelination studied, two were multiple sclerosis and two were ADEM. Restricted diffusion was noted only in one case of ADEM.

1 case of leukodystrophy, 1 case of metabolic encephalopathy and 4 cases of posterior reversible encephalopathy syndrome (PRES) were also studied. All these lesions showed hyperintensity on T2 FLAIR images but restricted diffusion was noted in single case of metabolic encephalopathy.

DISCUSSION

150 patients with intracranial lesions detected on DWI of the brain were included. It was found that DWI provides adjunctive information for intracranial lesions including stroke, HIE, neoplasms, infections, and demyelinating lesions in conjunction with conventional MRI.

Results of this study are correlated with a study done by Gonzalez et al[4] who concluded that DWI is superior to conventional MRI in the diagnosis and characterization of acute infarct. In this study restricted diffusion was noted in 100% of acute infarcts. In 13% of acute infarcts, no change was noted on T2WI. Thus DWI was noted to be superior to T2WI in detection of acute infarcts.

In subacute infarcts and chronic infarcts, abnormal signal was noted on T2WI and on DWI in all patients. Thus there was no difference in their sensitivity for later stages of infarcts .

Schaefer et al[5] concluded that HIE lesions not seen on routine MRI are identified on DWI. When lesions are identified on conventional images, lesion conspicuity is increased and lesion extent is seen to be larger on DWI.

All cases of neonatal HIE included in this study showed true diffusion restriction. In 20% of cases there was no abnormality on T2 FLAIR images. The extent of abnormal signal was much more in the remaining 80% of cases on DWI, than that shown by T2W images.

Chang et al[6] have shown that abscess cavity shows high signal intensity on DWI and a low signal on ADC image. This is not seen in the necrotic component of brain tumors. In this study 100% of cases of abscess showed diffusion restriction. The cystic or necrotic component of none of the tumors included in this study showed restricted diffusion. Thus, DWI can differentiate between tumor and infection and can provide information about the cellularity of tumors thereby helping in characterization and grading of tumors.

Cruz CH et al [7] showed that highly cellular tumors such as high grade gliomas and some metastases can have low ADC values and show restricted diffusion. It was also shown that medulloblastomas may be differentiated from other pediatric brain tumors by presence of diffusion restriction. The findings of this study were similar. In this study, 40% of GBM, 80% of medulloblastomas and 33.33% of metastases showed true diffusion restriction.

Diffusion weighted MR plays a key role in differentiating arachnoid from epidermoid cysts. This was also demonstrated in a study by Cruz et al[7], in which epidermoid cysts had ADC values similar to brain parenchyma while arachnoid cysts had ADC values similar to CSF. In this study all 7 cases of arachnoid cysts had signal similar to CSF on DWI and ADC images. Two cases of epidermoid cyst noted in this study had restricted diffusion.

Tadeusz et al[8] concluded that most meningiomas are isointense on DWI. Only few may show restricted diffusion depending on their cellularity. In their study 23% of meningiomas showed restricted diffusion. This study had similar results with 14.3% of meningiomas showing true diffusion restriction. Schwannomas show high signal on ADC images with no restricted diffusion reflecting lack of high cellularity.

Studies done by Larsson H et al[9] have shown that most foci of demyelination do not show restricted diffusion. Out of four,three cases of demyelination seen in this study did not show restricted diffusion and had increased signal on T2 FLAIR images.

Schwartz et al[10] showed that the edema of hypertensive encephalopathy is of vasogenic type. The results of this study are similar. None of the cases of PRES seen in this study had features of restricted diffusion.

CONCLUSION:

DWI provides unique information about the physiologic state of brain tissue. DWI has been proven to be of excellent use in the characterization of infarcts and in the detection of acute infarcts and HIE. It is especially useful in the initial few hours of the ischemic insult when conventional MR sequences may be inconclusive and may not detect the ischemic injury

DWI can provide valuable information about tumor cellularity and help in the characterization of tumors and grading of tumors. The solid portion of high grade tumors may show restricted diffusion. True restriction was not observed in low grade gliomas. DWI also helps identify medulloblastomas by showing true restriction in these lesions.However, necrotic components of tumour do not show restriction while abscesses do. So, DWI also helps in differentiating between necrotic tumours and abscesses.

While conventional MRI may be inconclusive in the differentiation of epidermoid cyst from arachnoid cyst, DWI shows restricted diffusion in the former and helps distinguishing the two. Among extra axial tumors, restricted diffusion has been noted in meningiomas. There is no restriction of diffusion in schwannomas.

Thus DW MRI helps in differentiating and characterizing intrac-

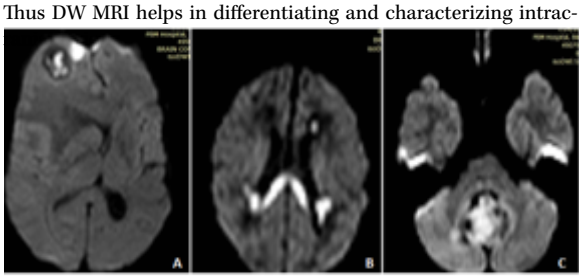

DWI of a case of cerebral abscess (A), HIE(B) and Medulloblastoma (C) showing restricted diffusion.

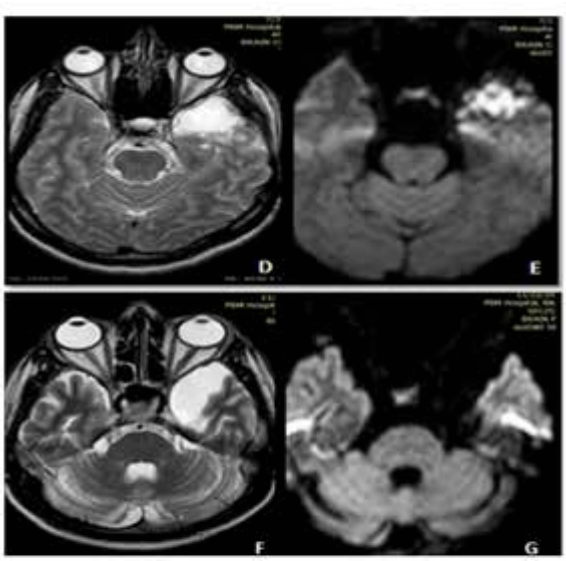

T2WI and DWI of Epidermoid cyst (D , E) and Arachnoid cyst (F, G). Restricted diffusion is seen in epidermoid cyst which helps to differentiate it from arachnoid cyst

REFERENCES :

1. Huisman TA.Diffusion-weighted imaging: basic concepts and application in cerebral stroke and head trauma. Epub 2003 ;13(10):2283-97.
2. Mukherji, Suresh K, Chenevert, Thomas L, Castillo, Mauricio. Diffusion weighted magnetic resonance imaging. Journal of neuro-ophthalmology 2002 ;22(2):118-122.
3. Lippincott Williams and Wilkins; Atlas SW, editors. Magnetic resonance imaging of the brain and spine. 4th ed.China: 2009. p. 472-474.
4. Gonzalez RG, Schaefer PW, Buonanno FS, et al. Diffusion-weighted MR imaging: diagnostic accuracy in patients imaged within 6 hours of stroke symptom onset. Radiology 1999;210:155-162.
5. Schaefer PW, Grant PE, Gonzalez RG. Diffusion weighted MR imaging of the brain. Radiology 2000 ;217:331-345.
6. Chang SC, Lai PH, Chen WL, Weng HH, Ho JT, Wang JS et al. Diffusion weighted MRI features of brain abscess and cystic or necrotic tumors – comparison with conventional MRI. Clinical imaging 2002 ;26(4):227-236.
7. Cruz CH, Gasparetto EL, Domnigues RC. Diffusion weighted MRI in brain tumor. Neuroimaging clinics 2011 ;21(1):27-49.
8. Tadeusz WS, Cristo C, Alex M, Wael MS, Katrijn VR, Robert L et al. Diffusion weighted MR images of intracerebral masses - comparison with conventional MR. AJNR 2001;22:969-976.
9. Larsson H, Thomsen C, Frederiksen J, Stubgaard M, Henriksen O. In vivo magnetic resonance diffusion measurement in the brain of patients with multiple sclerosis. Magn Reson Imaging 1992;10:7- 12.
10. Schwartz R, Mulkern R, Gudbjartsson H, Jolesz F. Diffusion-weighted MR imaging in hypertensive encephalopathy: clues to pathogenesis. Am J Neuroradiol 1998;19:859-862.