ORIGINAL RESEARCH PAPER

Volume-8 | Issue-1 | January-2019 | PRINT ISSN No 2277 - 8179

INTERNATIONAL JOURNAL OF SCIENTIFIC RESEARCH

DISEASE SPECTRUM IN BONE MARROW ASPIRATION CYTOLOGY: STUDY IN A TERTIARY CARE CENTRE IN NORTH INDIA

Pathology

Dr. Alpana Gupta Dept of Laboratory Sciences and Molecular Medicine, Army College of Medical Sciences & Base Hospital Delhi, Delhi-110010

Dr Syed Asif Hashmi* Dept of Laboratory Sciences and Molecular Medicine, Army College of Medical Sciences & Base Hospital Delhi, Delhi-110010 *Corresponding Author

Dr. K S Rajmohan Dept of Laboratory Sciences and Molecular Medicine, Army College of Medical Sciences & Base Hospital Delhi, Delhi-110010

Dr. Inam Danish Khan Dept of Laboratory Sciences and Molecular Medicine, Army College of Medical Sciences & Base Hospital Delhi, Delhi-110010

ABSTRACT

Background: Bone marrow examination is one of the most important studies for diagnosis of both hematological and non-hematological disorders.

Material and methods: The retrospective study was conducted in a tertiary care hospital in north India. 161 bone marrows were studied as per ICHS guidelines and results were tabulated and studied.

Result: Out of 161 marrow aspiration, 90 study subjects were males, 41 were females and 29 were children of age 5 to 12 yrs. The most common pathologies detected were Megaloblastic anemia, erythroid hyperplasia and reactive marrow.

Summary: BMA is a very useful investigation when performed by a qualified haematologist. It is often indicated after initial evaluation of the peripheral blood and other ancillary tests, in patients with blood or blood related diseases

KEYWORDS

Disease spectrum, bone marrow aspiration, Megaloblastic anemia.

Introduction

Bone marrow examination is one of the most important studies for diagnosis of both hematological and non-hematological disorders. The aspirates are generally studied in conjunction with peripheral blood smear and biopsy. Bone marrow when performed properly gives valuable information regarding the clinically suspected disease process or it may provide insight into unsuspected disease (1, 2). Trephine biopsy has great value in providing information about the structure of large piece of bone marrow along with cellularity and temporal association of cells with each other (3).The disease spectrum varies widely in different geographical location of the world. In India it also varies between different states being a very vast country and with different ethnic population. Bone marrow aspirate is also used for immunophenotyping, cytogenetic and molecular genetic analysis (4). It is also done some times to stage a malignant condition or storage disorder. Although it is an invasive procedure it can safely be done even in thrombocytopenic patients with little or no risk of bleeding (5). Generally bone marrow aspiration is done for diagnosing cytopenias, malignant conditions, infectious and granulomatous conditions where it provides definitive diagnostic information.

Material and Methods

The study was conducted in a tertiary care hospital of Delhi. The study was retrospective, with data collected from the period of 2014 to 2018. Written informed consent of all study subjects was obtained before undergoing the procedure.

Inclusion criteria- Only bone marrows aspirates which were adequate were taken into consideration as per ICSH guidelines (6).

Exclusion Criteria- All the other bone marrow aspirates with the absence of particles, megakaryocytes or other haemopoietic precursors were reported as a 'blood tap'. In the absence of particles, but in the presence of megakaryocytes or other precursor cells, the sample was reported as a hemodiluted sample. In the presence of particles with absent or much reduced cellularity, only a qualitative description was provided.

Method- Slides of Bone marrow aspirate were received from the wards along with the impression smears of the bone marrow biopsy, in cases where the trephine biopsy was conducted. Leishman stain was used for bone marrow aspiration slides, in cases of clinical suspicion Prussian blue was done for the Iron stores. For all the cases clinical history, peripheral smears, reticulocyte count and complete hemogram were reviewed in conjunction with the bone marrow aspirate smears.

All the smears and sections were reviewed for morphological details by two pathologists and the findings on BMA were opined on independently and then correlated.

Results

In the present study 161 patients had adequate bone marrow aspiration. Among them 90study subjects were males and 41 were females and 29 were children of age 5 to 12 yrs. Bone marrow examination findings are given in Table 1.

Table 1: Diagnosis in Bone Marrow Aspiration (BMA) Cytology

S No	Bone Marrow Aspirate Diagnosis	No of Cases	Percentage
1	Megaloblastic anemia	50	31%
2	Erythroid hyperplasia	22	14%
3	Reactive marrow	47	30%
4	Hematolymphoid malignancy	08	5%
5	MDS	02	1%
6	Leishmaniasis	02	1%
7	Histoplasmosis	02	1%
8	Hemophagocytic lymphohistiocytosis(HLH)	02	1%
9	Eosinophilia	02	1%
10	Plasma cell disorder	09	6%
11	Metastatic carcinoma	01	1%
12	Myeloid hyperplasia	02	1%
13	Lymphoid hyperplasia	02	1%
14	Normal study	10	6%
Total		161	100%

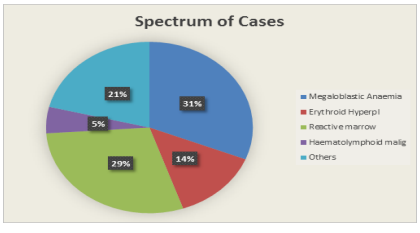

-Pie chart showing the distribution of cases

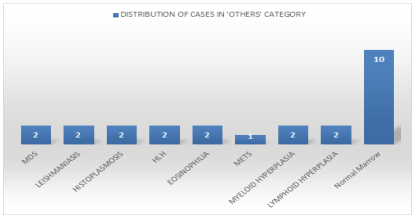

Bar chart showing the distribution of cases in 'Others' category

A total of 161 cases were diagnosed on BMA cytology with Megalo blastic anemia as the commonest diagnosis (N=50; 31%). Reactive marrow was the second commonest diagnosis (N=47; 30%), Erythroid hyperplasia constituted 14 % of cases while Hematoly mphoid malignancy excluding MDS cases were 5%.

Discussion:

Bone marrow aspiration is invasive but relatively safe procedure and can be performed on outpatient basis. The findings of bone marrow affect patient management with definitive diagnosis of neoplastic or non neoplastic diseases process.

Megaloblastic anemia:

It is one of the most common types of deficiency disorder resulting in anemia. It is also the type where a bone marrow aspiration is warranted if Vit B12 and Folic acid levels are not available easily or peripheral blood smear findings are not conclusive. Megaloblastic anemia presents with typical clinical features as fatigue, exercise intolerance, paleness etc. It is also cited as the common cause of pancytopenia in a study conducted by Tilak et al (7). In a similar study conducted by Gayathri et al Megaloblastic anemia was commonest cause of pancytopenia and commonest finding in bone marrow (8). In our study also the most common finding was Megaloblastic anemia. Megaloblastic anemia is more common among people resorting to vegetarian diet, in pregnant woman and in growing children. This is more common in northern India. It presents with features of anemia with pancytopenia and evidence of hemolysis in peripheral smear warranting a bone marrow aspirate to confirm the diagnosis.

Erythroid hyperplasia:

Erythroblastic hyperplasia was reported in 22 cases constituting 14% of total bone marrow aspirate diagnosis. Out of 22 erythroid hyperplasia cases 14 were micro erythroblastic proliferations which were later confirmed as iron deficiency anemia. Similar incidence (14%) was shown in a study by Khodke et al (9). A study done by Ahmad et al,8% cases were microcytic anemia and diagnosed as iron deficiency anemia (10). Another study performed by Parajuli S, and Tuladhar A in Nepal had similar incidence of micronormoblastic anemia at 10.66% in bone marrow aspiration studies (11).

Reactive cellular marrow:

Reactive cellular marrow is one which involves hyperplasia of one or more cell lines or in rare cases hypoplasia or aplasia. Reactive marrow is generally seen in inflammatory conditions or intrinsic marrow insult (12). In our study we have categorized reactive marrow as those cases where more than one cell line was proliferating. Maximum number of bone marrow aspirate in our study was conducted to diagnose pyrexia of unknown origin, to rule out malignancy, to diagnose fever in immuno surveillance patients and cases of unexplained significant weight loss.

Hematolymphoid malignancy:

In our study 8(excluding plasma cell disorder) out of 161(5%) cases were Hematolymphoid malignancy. Out of these eight cases five cases were of acute leukemia, two cases were of CLL and one case was of mature lymphoid cell proliferation. Two cases of MDS (1%) were also diagnosed in our study. Bone marrow aspirate is essential in the diagnosis of leukemia and MDS cases as morphology of individual cells are best studied in aspirate smears. Bone marrow aspirate is also required for immunophenotyping cellular and molecular genetics. Parajuli S and Tuladhar A in their study reported the incidence of Hematolymphoid malignancy as 12% which included acute leukemias, CLL, Multiple myeloma, Lymphoma and MDS.(11) In our study we have discussed Multiple Myeloma separately under Plasmacell disorders.

Plasma cell Disorders:

Plasma cell disorders constituted 6% of cases in our study. There were three cases of confirmed Multiple Myeloma cases while six cases showed frank plasmacytosis. Studies by Adewoyin et al in Nigeria reported around 7.9% cases of malignant plasmacytosis (13) while another study in Pakistan showed 2 % cases of Multiple Myeloma. The most important criteria for diagnosis of Multiple Myeloma is the presence of clonal proliferation of plasma cells>10% (14). Clonality should be established by κ/λ light chain restriction by flow cytometry, IHC and immunofluoresence. Introduction of immuno stain CD138 has made it possible for accurate diagnosis of plasma cells in aspirate and biopsy specimen. Plasmacytosis cases were particularly common in HIV positive individuals.

Infectious conditions:

The infective conditions that were diagnosed in our study of bone marrow aspirate were Leishmaniasis and Histoplasmosis. Both the conditions constituted two cases each (Approx 1% each). Bone marrow aspiration was done to reach a definitive diagnosis in fever cases. Leishmania generally presents clinically in three forms namely, visceral Leishmaniasis or Kala Azar, Cutaneous Leishmaniais and Mucocutaneous Leishmaniasis. Cutaneous Leishmaniasis is the most common form where as visceral Leishmaniasis is the most severe form. Patients mostly complain of prolong fever with irregular bouts, splenomegaly and abdominal pain. A study conducted in Delhi reported splenomegaly in 100% and anemia and fatigue in 72.22% of cases of visceral Leishmaniasis (15).Khodke et al in their study reported incidence of 14% cases of Leishmaniasis in cases of pancytopenia (9). Definitive diagnosis of Leishmania requires demonstration of amastigote form or LD bodies in the bone marrow or splenic aspirate. LD bodies are aflagellate, round and approximately 2-4 μ in size.

Disseminated Histoplasmosis is an AIDS defining illness caused by dimorphic fungi Histoplasma capsulatum. It generally presents with fever, malaise, anorexia, weight loss, lymphadenopathy and hepatosplenomegaly. Histoplasma in immunodeficient is seen in disseminated form. Histoplasmosis can involve all the organ or tissue of the body (16). But in HIV positive individuals it presents in disseminated form in 95 % of cases and in 90% it occurs when the CD4 count is less than 200/mm3 (17). The diagnosis requires demonstration of yeast form in bone marrow aspirate both intra and extra cellularly. Bone marrow aspirate has the positivity rate of 50-75% and is best diagnostic modality (18, 19). Grocotts methenamine silver staining provides good staining of the fungus. In our study both the cases of Histoplasmosis were seen in HIV positive immunodeficient individuals with prolong fever. The BMA showed large no of yeast forms both intra and extra cellularly.

Hemophagocyticlymphohistiocytosis (HLH)

is an aggressive and life-threatening syndrome of disproportionate immune activation and excessive inflammation which is caused by unopposed action of activated macrophages and lymphocytes. HLH can occur as a familial or sporadic disorder and it can be triggered by a variety of events that disrupt immune homeostasis (20).Most of the cases of haemophagocytosis are associated with viral infection mainly HSV, Parvovirus, CMV, EBV and HIV. However Infectious conditions such as Leishmania, Malaria, Brucella and Salmonella are also associated with Haemophagocytosis (21, 22). Prompt initiation of treatment is essential for the survival of affected patients. Often the greatest barrier to a successful outcome is a delay in diagnosis. All patients should have examination of a bone marrow aspirate and biopsy to evaluate the cause of cytopenias and/or to detect haemophagocytosis (22). The diagnostic criteria depends on the fever, splenomegaly, cytopenias, haemophagocytosis in bone marrow, hypertriglyceridemia, hypofibrinogenemia, NK cell activity, ferritin levels and soluble CD 25 levels. The study by Khan et al showed a

HLH percentage of 0.8 % (23) while our study showed similar incidence of 1%. However, haemophagocytosis in bone marrow is not essential for the diagnosis of HLH.

Hyper cellular marrow with increased eosinophilic precursors was seen in 1% of cases in our study. Hematologic evaluation with bone marrow examination (aspiration and biopsy) is appropriate for any individual with a primary hematologic cause of eosinophilia. In acutely ill patient with eosinophil count >100,000/microlitre or signs of organ involvement by eosinophils without an obvious cause identified from initial testing, bone marrow morphology should be evaluated for abnormalities of eosinophilic precursors.

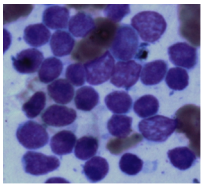

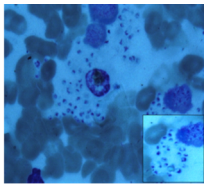

Fig 1: Blast in Acute leukemia
Fig 2: Histoplasma within and outsidemacrophages

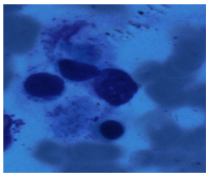

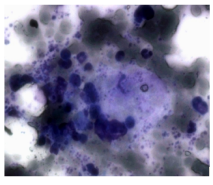

Fig 3&4: Hemophagocytic Lymphohistiocytosis: Ingested cells within macrophages

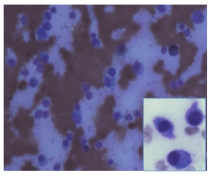

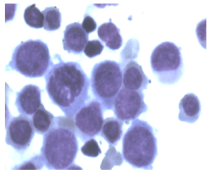

Fig 5: Plasma cells in myeloma
Fig 6: Erythroblast in Megaloblastic anemia.

The various causes can be infective, allergic or neoplastic such as chronic myeloid leukemia (CML), myeloproliferative hypereosinophilic syndrome (HES) etc. The bone marrow studies should be followed by cytogenetic and/or specific molecular testing for hematologic neoplasms associated with eosinophilia.

Other findings in our study were 1% cases of metastatic deposits from carcinoma which is much lesser than 7.9% cases of marrow carcinomatosis in a Nigerian study by Adewoyin et al (13). Another study by Qahtani et al. in Saudi Arabia showed 1% cases of metastatic disease (24). These differences may be related to clinical indications for bone marrow evaluation, other diagnostic modalities available and possible geographic difference in the patterns of marrow diseases. Our study showed 1% each of lymphoid hyperplasia and myeloid hyperplasia suggesting an infective etiology. However, no features of sepsis were found in these bone marrow aspirates.

Conclusion

BMA is a very useful investigation when performed by a qualified haematologist who is conversant with the procedure and its potential complications. The patient has to be properly informed and educated about the procedure to allay anxiety. Informed consent should be obtained and documented. Local anaesthesia should be used and allowed the minimum time to take effect before the procedure. BMA should not be a first line investigation. It is often indicated after initial evaluation of the peripheral blood and other ancillary tests, in patients with blood or blood related diseases.

REFERENCES

1. Chandra S, Chandra H, Saini S. Bone marrow metastasis by solid tumors – probable hematological indicators and comparison of bone marrow aspirate, touch imprint and trephine biopsy. Hematology 2010; 15:368-72.
2. Nanda A, Basu S, Marwaha N. Bone marrow trephine biopsy as an adjunct to bone marrow aspiration. J Assoc Physicians India 2002; 50:893-5. PMid: 12126342
3. Dacie and Lewis Practical Haematology 10th edition pg 115
4. Bain B J. Bone marrow aspiration Clin Pathol 2001; 54:657–663
5. Kibria S G, Islam MDU, Chaudhury ASMJ, Ali MY, Haque MR, Mustanzid S M, Ali S Y. Prevalence of hematological disorder: A bone marrow study of 177 cases in a private hospital at Faridpur. Faridpur Med. Coll. J. 2010; 5(1):11-13
6. Lee S-H, Erber W N, Porwit A, Tomonaga, Petersen L C. ICSH guidelines for standardization of bone marrow specimen and reports. Int. Jnl. Lab. Hem. 2008, 30, 349–364
7. Tilak N, Dash S. Reappraisal of underlying pathology in adult patients presenting with pancytopenia. Trop Geogr Med 1999; 44:322-7.
8. Gayathri BN, Rao KS. Pancytopenia: a clinic hematological study. J Lab Physicians 011; 3:15-20.
9. Knodke K, Marwah S, Buxi G, Yadav RB, Chaturvedi NK. Bone marrow examination in cases of Pancytopenia. J Academy Clin Med20012001; 2:55-9.
10. Ahmad SQ, Khan OU, Zafar N. Utility of Bone Marrow Examination in a secondary Care Hospital JRMC 2011;15:40-1.
11. Parajuli S, Tuladhar A. Correlation of bone marrow aspiration and biopsy findings in diagnosing hematological disorders – a study of 89 cases. Journal of Pathology of Nepal (2014) Vol. **4**, 534-538
12. Sherbiny S, El-Hawary AK, Eladl E and Zalata K (2018) Reactive Changes in Bone Marrow Biopsies: A Clinicopathological Study. BAOJ Cancer Res Ther 4: 054.
13. Adewoyin. et al. Bone Marrow Aspiration Cytology Studies In A Tertiary Hospital, Nigeria: A Series Of 88 Cases Annals of Pathology and Laboratory Medicine, Vol. 2(04), October - December 2015: 108-114
14. Landgren O, Rajkumar SV: New developments in diagnosis, prognosis, and assessment of response in multiple myeloma. Clin Cancer Res 22:5428-5433, 2016.
15. Dhingra K K, Gupta P, Saroha V, Setia N, Khurana N, Singh T. Morphological findings in bone marrow biopsy and aspirate smears of visceral kala azar: A review. Indian journal of Pathology and Microbiology 2010; 53(1): 96-100
16. Kauffman CA. Histoplasmosis: a clinical and laboratory update. Clin Microbiol Rev. 2007; 20(1):115–32.
17. Adenis A A, Aznar C, Couppie P. Histoplasmosis in HIV-Infected Patients: A Review of New Developments and Remaining Gaps. Curr Trop Med Rep (2014) 1:119–128
18. Couppie P, Aznar C, Carme B, Nacher M. American Histoplasmosis in developing countries with a special focus on patients with HIV: diagnosis, treatment, and prognosis. Curr Opin Infect Dis.2006; 19(5):443–9.
19. Wheat J. Endemic mycoses in AIDS: a clinical review. Clin Microbiol Rev. 1995;8(1):146–59.
20. Jordan MB et al How I treat hemophagocyticlymphohistiocytosis, Blood 2011; 118(15):40-41.
21. Shirono K, Tsuda H. Parvovirus B19-associated Hemophagocytic syndrome in healthy adults. British J. Haematol 1995; 89:923-6.
22. Diebold J, Molina T, Camilleri-Broet S, Tourneau A le, Audouin J. Bone marrow manifestations of infections and systemic diseases observed in bone marrow trephine biopsy. Histopathology 2000; 37:199-211.
23. Khan TA, Khan IA, Mahmood K. Diagnostic role of bone marrow aspiration and trephine biopsy in haematological practice. J Postgrad Med Inst 2014; 28(2):217-21.
24. Qahtani FSA, Syed NN. An audit- indications and diagnosis of bone marrow biopsies at a tertiary care hospital in Saudi Arabia. Hematol Transfus Int J. 2018;6(5):189–193. DOI: 10.15406/htij.2018.06.00181