ORIGINAL RESEARCH PAPER
Volume-8 | Issue-3 | March-2019 | PRINT ISSN No 2277 - 8179
INTERNATIONAL JOURNAL OF SCIENTIFIC RESEARCH

DROROSCOPE – AN INNOVATIVE ORAL CANCER SCREENING DEVICE

Clinical Research

Rama Raju Devaraju*	Honorary Professor, Department of Oral Medicine and Radiology, SVSIDS, Mahabubnagar, Telangana, India. *Corresponding Author
Srikar Muppirala	Consultant Maxillofacial Radiologist, Vijaya Diagnostic Centre, Hyderabad, Telangana, India.
Srikanth Goud Gotoor	Assistant Professor, Department of Oral Medicine and Radiology, SVSIDS, Mahabubnagar, Telangana, India.
Tejaswi Katne	Consultant Maxillofacial Radiologist, Max3G Imaging Centre, Hyderabad, Telangana, India.
Niharika Harsha	Consultant Maxillofacial Radiologist, Max3G Imaging Centre, Hyderabad, Telangana, India.
Ramlal Gantala	Professor & Head, Department of Oral Medicine and Radiology, SVSIDS, Mahabubnagar, Telangana, India.

ABSTRACT

In the terms of morbidity and mortality oral cancer is the 6th most common disease. Oral potentially malignant disorders (PMDs) being those with higher risk of malignant transformation, there is a necessity for early detection to decrease incidence of oral cancer. Though an experienced clinician can detect PMDs by clinical oral examination, evidence specifies that examination of the lesions with adjuvant aids is much better than conventional examination in mucosal lesions. This fact suggests need for diagnostic adjuncts. A glance into existing literature enlists number of optical diagnostic aids for detection of oral PMDs and oral cancer in early stages. Certain limitations and cost of most devices are hindering the use. This article introduces an optical screening aid for oral malignancy "Dr.OROSCOPE" (International patent publication no. WIPO/PCT WO2019/035024 A1). This device compiles additional features to the existing optical aids, answering the prevailing limitations with clinician friendly features and is economically efficient.

KEYWORDS

Oral cancer screening, autofluorescence, DrOroscope.

INTRODUCTION:

The recent past has visualized the emergence of various adjunctive devices for the detection of oral cancer. This is because oral cancer has been the leading cause of death in both the developing and developed countries.Oral cancer being a broader term includes various malignant disorders. The cancer & its therapies are associated with morbidities and they affect the quality of life. Oral cancer is the 6th most common cancers in Asia[1] and Ranks top 3 of all cancers in India & > 30% of all cancers in India.[2]

As evidenced from a RCT of screening for oral cancers in India, the mortality rate reduces with initial stages at diagnosis. Initial oral screening improves the survival by early diagnosis and provision of health care[1]. Various techniques have been introduced off late for screening like those using light and saliva.

The purpose of this paper is to introduce an economic fluorescent visualization device using blue light (400-460nm) to detect abnormal oral tissues that cannot be seen by white light. This technique has been previously used with the VELscope, and utilizes the autofluorescent properties of healthy and abnormal tissues. A number of different factors work together to make this process possible, such as the fluorophore FAD, the histo-morphological changes in abnormal tissue, and the varying levels of hemoglobin. All these changes make the use of blue light successful in precisely detecting abnormalities in the tissue (such as dysplasia/cancer). Further experiments confirming the validity of this process in aiding the detection of pre-malignant tissues will be presented. Although there is a standard screening process already in place, the aim of this fluorescent visualization device is to increase efficiency and avoid missing lesions that may not be visible to the eye.

Effect of Blue Light on Living Tissue

Tissue optics refers to the effect of light on living tissue. In the identification of oral cancers, blue light (wavelength 400-460nm)[3] has been used to identify abnormal tissues via fluorescence visualization loss (FVL). This technique is particularly useful in all oral cancers and PMDs. The thickness of the epithelium(40-50 cell thick) ranges from 100-200 µm at the floor of the mouth to a range of 500-800 µm in the buccal mucosa, so blue light of 400-460nm can easily reach these layers of mucosa.[4,5]

Effects Of Green-Amber Light on Living Tissue

It is a well-known fact that the cancerous tissues show richer vascu lature. The green light highlights the superficial microvasculature which aids in assessing the prognosis of the lesion.[6,7]

The present device adds an additional green-amber light to better visualize the increase in angiogenesis associated with carcinoma The following table is the standard screening process defined by the American Dental Association. The goal of this report is to prove that the FV Device can make the standard screening process more successful.

Oral Cancer Screening Techniques

Oral cancer screening refers to the detection of pre-cancerous tissue. The earlier a cancer is detected, the more likely it is that it can be treated

Process		Description	Advantages	Disadvantages
Meta-chromasia	Toluidine Blue (TB)[8]	TB stains acidic tissue components, such as nucleic acids. Can be used most efficiently to confirm suspicious tumors as neoplastic, but does not have 100% sensitivity, so can't be relied on to show lesions that are not visible to the eye	- sensitive - cheap -immediate results	- shades of blue are open to interpretation - experiments are not standardized, varying results - generally low specificity - inflammation and trauma can cause false-positives

	Lugol's iodine staining	Iodine reacts with the glycogen in the cytoplasm, which results in an observable color change. The enhanced glycolysis in cancer cells doesn't allow the iodine start reaction, so they show up as pale, while the normal tissue is brown.	- greater specificity than TB - low cost	- less sensitive than in identifying oral malignant dysplastic lesions (than TB)
	Methylene Blue[9]	This dye, similar to TB, targets tissue with large amounts of nucleic acids, which is found in abnormal tissue.	chair-side; rapid; low-cost	
	Rose Bengal (RB) [10]	RB stains dead or degenerated epithelial cells. Has been used with diagnosing ocular surface disorders.	- according to one study, it is capable of identifying lesions with oral squamous cell carcinoma (OSCC) based on the darkness of the staining	- insufficient evidence - interpretation of shading can limit efficiency and accuracy - inflammation and trauma can cause false-positives
Tissue Absorbance and Fluorescence	VELscope[11]	This device observes the autofluorescence of blue light-absorbing fluorophores to reveal abnormalities in the tissue. Dark areas indicate potential malignancy, while areas that show as green (the color emitted by fluorophore FAD) are shown as healthy.	- hand-held - easy to operate - simple to understand - takes advantage of the disparity of endogenous fluorophore distribution in healthy and cancerous tissue - can detect cancers that cannot be seen during a routine examination.	- high initial costs - moderate false positive rates - as of now is an adjunct aid, requires confirmation by histopathological analysis - the impact of hemoglobin on absorption and fluorescence is yet to be determined - undetermined impact of intensity of light on fluorescence - loss of autofluorescence also can occur due to inflammation and melanin pigmentation (not only epithelial abnormalities).
	ViziLite Plus[12]	After being exposed to 1% acetic acid, areas with abnormal cells are visible under bluish white LED light.	- improved the visualization of white lesions	- red lesions were harder to visualize - reflections produced by chemiluminescent light made visualization difficult - insufficient evidence for the reliability of ViziLite in early detection of oral malignancies
	Microlux/DL[13]	Similar to Vizilite, Microlux/DL examines the oral cavity with blue-white LED light.	- high sensitivity	- poor discriminant for inflammatory, traumatic, malignant diseases - low specificity
	Orascoptic DK[14]	Similar to Vizilite, uses an acetic acid rinse and blue-white LED light.	Same as vizilite	Same as vizilite
	Identafi 3000[15]	examines tissue reflectance which is based on the premise of detecting changes in angiogenesis with green-amber light (540- to 575-nm wavelength) illumination	small size and easy accessibility Uses 3 different wavelengths of light. Better accuracy	Expensive
	Photodynamic diagnosis[16]	Uses an acid called 5-ami-nolevulinic acid (ALA) that induces protoporphyrin IX (PPIX) to fluoresce in tissue. A 0.4% ALA rinse for 20 minutes is able to stimulate PPIX in dysplastic and cancerous tissue, which is then excited to fluoresce by blue light.	-	- false positive rate is high in patients with history of radiotherapy - also the production of PPIX can also be caused by reasons other than cancerous tissue, such as: - bacterial strains -low levels of glucose
Light Spectroscopy and Imaging	Raman spectroscopy[17]	A technique that distinguishes between normal and premalignant/malignant tissue by a vibrational spectroscopy that uses a laser in the visible, near-infrared, or near-ultra-violet range to cause inelastic scattering.	- has detected PMDs, cancer, and malignancy-associated changes in the oral cavity	- relatively weak inelastic scattering signals are difficult to capture - relatively slow speed of spectrum
	Elastic scattering spectroscopy[18]	It is an emerging technique for generating a wavelength spectrum that reflects structural and morphological changes within tissues	Real-time	
	Diffuse reflectance spectroscopy[19]	Utilizes white light, which after entering the tissue undergoes a combination of multiple elastic scattering and absorption.	Simple; low-cost; real-time	Difficult to image the lesions in posterior oral cavity & in limited mouth opening.

	Narrow-band imaging[20]	This optical imaging technique is based on the depth of light penetration and captures the reflected light	Real-time; easy to manage	Moderate false-positive rates
	Optical coherence tomography[21]	Interferometer based optical imaging technique is used near infrared light which penetrates and device captures the reflected light	Real-time; high sensitivity; high specificity	Need a histopathologist to interpret and assess; examines only a very small area at a time
	Confocal laser endomicroscopy[22]	It is an adaptation of white-light microscopy in which tissue and cellular structures are visualized by stimulating the emission of light using a low-power laser beam after the application of fluorescent contrast agents	Real-time; "optical biopsy	Need a histopathologist to interpret and assess; examines only a very small area at a time
	Confocal reflectance microscopy[23]	CRM is based on the mechanism of backscattering of light and is determined by natural differences in the refractive indices of organelles and other subcellular structures within the tissues	Real-time; "optical biopsy	Need a histopathologist to interpret and assess; examines only a very small area at a time
Analysis of Salivary biomarker	miRNA-184[24]	A greater amount of microRNA-184 is present in oral abnormalities such as OSCC and oral PMD.	- non-invasive - able to distinguish OSCC from oral PMD with dysplasia.	- not yet a reality - much research and development is required
	IL-6[25]	Inteerleukin-6 (IL-6) level increases with the severity of dysplasia.	- non-invasive	- periodontitis and tobacco use can also affect levels of IL-6
OralCDx Brush Test	OralCDx Brush Test[26]	Uses a specialized brush that collects samples of epithelial cells that are then scanned and analyzed microscopically to view abnormal morphology. This process is called cytopathology.	- reports the presence or absence of cellular abnormalities	- not a final diagnosis

Table 1: describes various existing techniques and devices for oral cancer detection.

successfully. Existing techniques and devices for oral cancer detection include the following [Table 1]:

This article introduces an optical screening aid for oral malignancy "Dr.OROSCOPE" (International patent publication no. WIPO/PCT WO2019/035024 A1).

DEVICE DESCRIPTION:

The present device [Figure 1] is a hand-held, portable, noninvasive and cost effective device used for inspection of various malignant and PMDs.



Figure 1: DrOroscope Device.

It is structured with 3 main parts:

Head

Body

Tail

Light source: it is the main part on the front side of the device. The device is equipped with six LED lights which emit lights of three different wavelengths. This light source is used to illuminate the suspected area. The emission of light produces an optical signal which illuminates the target area. The three different wavelengths of light are blue, red and green amber light.

Blue light is used to detect PMDs and oral cancers based on the auto-florescence and loss of florescence properties of the tissue.

Green amber light is used to detect vascularity as increased peripheral vascularity and central necrosis is a salient feature of malignancy. This light can also be used to detect the prognosis along with aforementioned blue light.

Red light is used to detect the infections that occur in various conditions.

Adjacent to the light emitting zone there is a CCD sensor placed which can capture the images of the lesion. The main advantages of the present device over the preexisting devices are the following:

A.It is an intraoral device which can be placed intra-orally to view the lesion

B.It can be used to screen larger samples without much equipment and setup, even in the open air.

A fiber optic probe which can be attached to the light source will be helpful in detecting clinically invisible interdental caries and depth of the periodontal pocket.

Filter: The device is embodied with a transparent filter which selectively blocks the blue light and reflected light from entering the sensor. This blocking of the optical inspection signal from the light source produces a different signal which is captured by the CCD sensors. This enhances the accuracy of capturing the margins of the lesion well. The filter is fixed to the front part of the device anterior to the CCD sensor. An image filter to enhance the clarity is incorporated in the software application which is user friendly and makes the device more convenient and economical Image sensor: there is a CCD sensor placed on the front part of the device. It is located between the LED lights. This sensor captures the optical signal and transfers it as an image when it is connected to laptop or an android device.

The body contains three switches one on the front and two other on the lateral side of the device. One of them is used to change the wavelength second switch to adjust the intensity of light and the other is used to activate the periodontal probe.

Tail part of the device has a connecting portal which can be used to connect to an android device or a computer to capture the images [Figures 2, 3]. This is connected to the body and head of the device through a cable which transfers the signal and also gives power supply to the device.

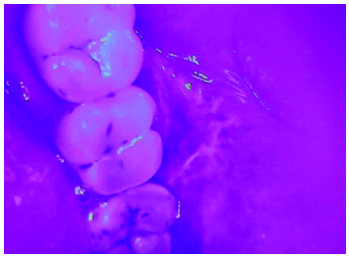

Figure 2: Blue light image of lichenplanus.

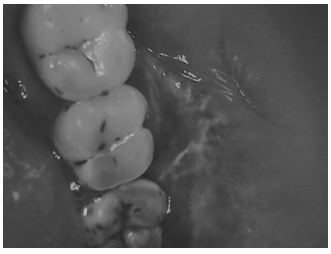

Figure 3: Same image after application of software filter.

DrOroscope software application:

The device is supported by DrOroscope software application, which can be installed in android phone or tablet or on computer. Which helps in image processing, application of filters in enhancing the clarity of lesion and also helps in the diagnosis with artificial intelligence incorporated in the application.

Advantages of this device over other screening devices:

Dr.Oroscope is an intraoral device with three different wavelengths of lights to identify the malignant and potentially malignant disorders of oral cavity. This works on the principle of auto florescence of tissues when exposed to light of a particular wavelength. The following are the advantages of the present device when compared to already existing devices. They are: Present device is very economical when compared to the existing ones Intra oral device which can be access any corner of the oral cavity.

Camera present within the device is helpful to capture the images without any external camera Does not require high intensity lights to view Has intensity adjustment Can screen in outdoor or indoor settings Have 3 lights to view for increased diagnostic accuracy Has a filter with camera or an app with a filter.

Useful for tele-dentistry as device can be connected to any android device or laptops to store and retrieve the images and transfer them to a specialist for confirmed diagnosis Can be used by any health care professional thus helping in screening larger populations.

REFERENCES:

1. Krishna Rao SV, Mejia G, Roberts-Thomson K, Logan R.Epidemiology of oral cancer in Asia in the past decade--an update (2000-2012). Asian Pac J Cancer Prev. 2013;14(10):5567-77.
2. Coelho KR. Challenges of the Oral Cancer Burden in India. Journal of Cancer Epidemiology. 2012;2012:701932
3. Sawan, D., & Mashlah, A. (2015). Evaluation of premalignant and malignant lesions by fluorescent light (VELscope). J Int Soc Prev Community Dent. 2015 May-Jun; 5(3): 248–254
4. Amir H Shojaei. Buccal Mucosa As A Route For Systemic Drug Delivery: A Review. J Pharm Pharmaceut Sci 1 (1):15-30,
5. David Harris, Joseph R Robinson. Drug delivery via the mucous membranes of oral cavity. J Pharm Pharmaceut Sci 81 (1):1-10.
6. Vu A, Farah CS.Narrow band imaging: clinical applications in oral and oropharyngeal cancer. Oral Diseases (2016) 22, 383–390
7. Huber MA. Adjunctive Diagnostic Techniques for Oral and Oropharyngeal Cancer Discovery. Dent Clin N Am 2018; 62(1); 59-75.
8. Lingen MW, Kalmar JR, Karrison T, Speight PM: Critical evaluation of diagnostic aids for the detection of oral cancer. Oral Oncol 2008, 44:10-22.
9. Chen YW, Lin JS, Fong JH, Wang IK, Chou SJ, Wu CH, et al. Use of methylene blue as a diagnostic aid in early detection of oral cancer and precancerous lesions. Br J Oral Maxillofac Surg 2007;45:590-1.
10. Zhang L, Bi L, Shi J, Zhang Z, Cao W, Lin J, Li C, Bi J & Yu Y (2013) A quantitative diagnostic method for oral mucous precancerosis by Rose Bengal fluorescence spectroscopy. Lasers Med. Sci., 28, 241-246.
11. Bhatia, N., Lalla, Y., Vu, A.N. & Farah, C.S. (2013) Advances in optical adjunctive AIDS for visualisation and detection of oral malignant and potentially malignant lesions. Int. J. Dent., 2013, 194029.
12. Sambandham, T., Masthan, K.M., Kumar, M.S. & Jha, A. (2013) The application of vizilite in oral cancer. J. Clin. Diagn. Res.,7, 185-186.
13. Ibrahim, S.S., Al-Attas, S.A., Darwish, Z.E., Amer, H.A. & Hassan, M.H. (2014) Effectiveness of the Microlux/DLTM chemiluminescence device in screening of potentially malignant and malignant oral lesions. Asian Pac. J. Cancer Prev., 15, 6081-6086.
14. Patton, L.L., Epstein, J.B. & Kerr, A.R. (2008) Adjunctive techniques for oral cancer examination and lesion diagnosis: a systematic review of the literature. J. Am. Dent. Assoc., 139, 896-905; quiz 993-894
15. Roblyer D, Kurachi C, Stepanek V et al. Objective detection and delineation of oral neoplasia using autofluorescence imaging. Cancer Prev Res 2009; 2(5): 423–431.
16. Sieron, A., Gibinski, P., Pustelny, T., Kwiatek, S., Opilski, Z.,Kawczyk-Krupka, A., Woznica, T., Maciak, E., Kubica, W., Urbanczyk, M. & Latos, W. (2008) Optical biopsy using spectral camera in BCC and oral leukoplakia. Photodiagnosis Photodyn. Ther., 5, 271-275.
17. Guze, K., Pawluk, H.C., Short, M., Zeng, H., Lorch, J., Norris, C. & Sonis, S. (2015) Pilot study: raman spectroscopy in differentiating premalignant and malignant oral lesions from normal mucosa and benign lesions in humans. Head Neck, 37, 511-517.
18. Green, B., Cobb, A.R., Brennan, P.A. & Hopper, C. (2014) Optical diagnostic techniques for use in lesions of the head and neck: review of the latest developments. Br. J. Oral Maxillofac. Surg., 52, 675-680.
19. Stephen, M.M., Jayanthi, J.L., Unni, N.G., Kolady, P.E., Beena, V.T., Jeemon, P. & Subhash, N. (2013) Diagnostic accuracy of diffuse reflectance imaging for early detection of pre-malignant and malignant changes in the oral cavity: a feasibility study. BMC Cancer, 13, 278.
20. Vu, A.N. & Farah, C.S. (2014) Efficacy of narrow band imaging for detection and surveillance of potentially malignant and malignant lesions in the oral cavity and oropharynx: a systematic review. Oral Oncol., 50, 413-420.
21. Katkar, R. A., Tadinada, S. A., Amaechi, B. T., & Fried, D. (2018). Optical Coherence Tomography. Dental Clinics of North America, 62(3), 421–434.
22. Nathan, C.A., Kaskas, N.M., Ma, X., Chaudhery, S., Lian, T., Moore-Medlin, T., Shi, R. & Mehta, V. (2014) Confocal laser endomicroscopy in the detection of head and neck precancerous lesions. Otolaryngol. Head Neck Surg., 151, 73-80.
23. Olivo, M., Bhuvaneswari, R. & Keogh, I. (2011) Advances in biooptical imaging for the diagnosis of early oral cancer. Pharmaceutics, 3, 354-378.
24. Zahran, F., Ghalwash, D., Shaker, O., Al-Johani, K. & Scully, C. (2015) Salivary microRNAs in oral cancer. Oral Dis., 21,739-747.
25. Sharma, M., Bairy, I., Pai, K., Satyamoorthy, K., Prasad, S., Berkovitz, B. & Radhakrishnan, R. (2011) Salivary IL-6 levels in oral leukoplakia with dysplasia and its clinical relevance to tobacco habits and periodontitis. Clin. Oral Investig., 15, 705-714.
26. Sharma G. Diagnostic aids in detection of oral cancer: An update. World J Stomatol 2015; 4(3): 115-120