Volume : 5 | Issue : 7 | July 2016 • ISSN No 2277 - 8179 | IF : 3.508 | IC Value : 69.48

Original Research Paper

Duplication of Both The Circumflex Arteries and Both The Interventricular Arteries in Human Heart

Medical Science

KEYWORDS : Coronary artery, Circumflex artery Interventricular artery, Heart.

Dr. Keshaw Kumar

Department of Anatomy, Government Allopathic Medical College, Banda (U.P.) INDIA.

ABSTRACT

The heart obtained from the cadavers (156) were dissected in order to study anomalies in human coronary arteries. Only in one heart duplication of both the circumflex arteries as well as both the interventricular arteries was found.

INTRODUCTION

Congenital anomalies of coronary arteries were discussed by Abbott (1927)1, Blake et al (1964)2, Hallman et al (1966)3 and Ogden (1970)4. The anomalous origin of left coronary artery from the pulmonary artery was observed by Askenazi and Nadas (1975)5, George and Knowlan (1959)6, Keith (1959)7 Wesselhoeft et al (1968)8 and Flamm et al (1968)9 while Ott et al (1978)10 found origin of circumflex artery from right pulmonary artery. Anomalous course and branches of human coronary arteries were described by Keshaw Kumar (1989)11. A single coronary artery was noticed by Smith (1950)12, Sharbaugh and White (1974)13. Duplication of branches in human coronary arteries was reported by Keshaw Kumar (1994)14. Anterior interventricular artery replacing left coronary artery with absence of arterial anastomosis in human heart was shown by Keshaw Kumar (2006)15. Comparative gross anatomy of coronary arteries in mammals was studied by Keshaw Kumar (1990)16. Yet the duplication of both the circumflex arteries as well as both the interventricular arteries has not been described till date by any author. The present study was conducted to observe duplication anomalies in human coronary arteries.

MATERIAL AND METHODS

The human hearts (156) procured from the dissection room cadavers were preserved in 10% formalin. Coronary arteries were dissected to find out the anomalies if any.

OBSERVATIONS

While dissecting the coronary arteries only in one out of 156 hearts, it was observed that about 0.5 cm distal to its commencement from left posterior aortic sinus the trunk of left coronary artery divided into superior and inferior circumflex arteries immediately after giving anterior interventricular artery (fig-2) superior circumflex branch of left coronary artery took an oblique course running inferior to the coronary sulcus while its inferior circumflex branch ran almost along the left border of heart but both of these arteries became intramuscular before reaching the diaphragmatic surface of heart and did not anastomose with circumflex branches of right coronary artery (fig-2).

Two centimeters distal to its commencement the anterior interventricular artery divided into medial and lateral anterior interventricular arteries running into anterior interventricular sulcus (fig-1). The lateral anterior interventricular artery was tortuous and became intramuscular after running 3 cm distance while the medial anterior interventricular artery ran in the anterior interventricular sulcus and crossed apical notch to anastomuse with the inferior posterior interventricular artery which was continuation of inferior circumflex branch of right coronary artery (fig-1,3).

The right coronary artery commenced from the anterior aortic sinus and running into coronary sulcus it divided into right superior circumflex artery and right inferior circumflex artery immediately after reaching the back of heart (fig-3). The right superior circumflex artery travelled into coronary sulcus and continued as nodal artery at the crux of heart after giving a slender superior posterior interventricular artery which sank into the musculature of heart after traversing 1.5 cm distance in the posterior interventricular sulcus (fig-3). The right inferior circumflex artery took an oblique course running inferior to coronary sulcus on the back of heart and reached the posterior interventricular sulcus midway between apex and the crux of heart to travel into it as inferior posterior interventricular artery to amastomose with the medial anterior interventricular artery near the apical notch (fig-3).

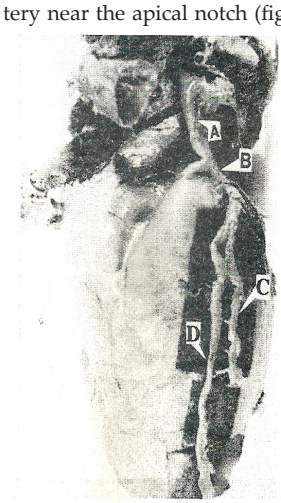

Fig. 1. Anterior view of human heart showing duplication of anterior interventricular branch of left coronary artery.

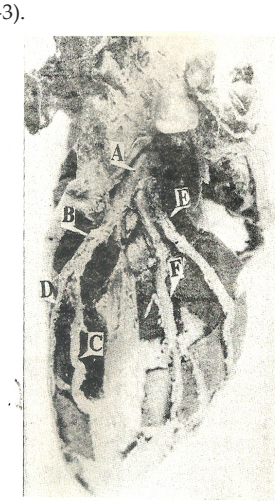

Fig. 2. Left lateral view of human heart showing duplication of circumflex branch of left coronary artery.

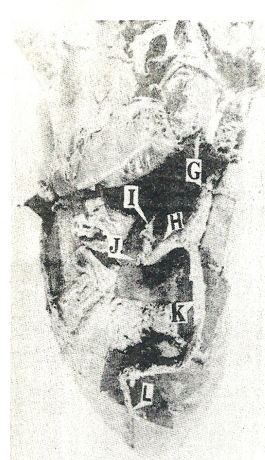

Fig. 3. Posterior view of human heart showing duplication of posterior interventricular and circumflex branches of right coronary artery.

ABBREVIATIONS USED

A- Left coronary artery, B- Anterior inter ventricular artery, C- Lateral branch of anterior inter ventricular artery, D- Medial branch of anterior inter verticular artery, E- Superior circumflex branch of left coronary artery, F- Inferior circumflex branch of left coronary artery, G- Right coronary artery, H- Superior circumflex branch of right coronary artery, I- Nodal artery, J- Superior posterior interventricular artery, K- Inferior circumflex branch of right coronary artery, L- Inferior posterior inter ventricular artery.

Volume : 5 | Issue : 7 | July 2016 • ISSN No 2277 - 8179 | IF : 3.508 | IC Value : 69.48

DISCUSSION

In the present study, the nodal artery was continuation of right superior circumflex artery and was thicker than the superior posterior interventricular artery indicating rich blood supply to atrioventricular node. Absence of the artery in the middle 1/3 of posterior interventricular sulcus showed that in this region entire interventricular septum was supplied by medial and lateral anterior interventricular arteries.

Presence of lateral anterior interventricular artery in the middle 1/3 of anterior interventricular sulcus was to compensate the absence of an artery in the middle 1/3 of posterior interventricular sulcus so that the blood supply of middle 1/3 of interventricular septum in its posterior part was ensured.

The slender superior posterior interventricular artery supplied very little posterior part of upper 1/3 of interventricular septum. Most of the interventricular septum in its upper 1/3 part was supplied by the thick arterior interventricular artery.

Anastomosis between circumflex arteries of right and left side was non existent because superior and inferior circumflex arteries arising from left coronary artery did not reach the back of heart. Anastomosis was present only between the medial anterior interventricular artery and the inferior posterior interventricular artery near the apical notch. Thus the inferior 1/3 of interventricular septum received the blood supply by medial anterior interventricular artery in its anterior 2/3 part and by inferior posterior interventricular artery in its posterior 1/3 part.

On the back of heart left portion of coronary sulcus was devoid of any circumflex artery running into it. Therefore this part of left atrium and left ventride derived their blood supply from the arteries supplying neighbouring portions of the heart.

Because the nodal artery and superior posterior interventricular artery arose from right superior circumflex artery therefore right coronary artery was dominating in this heart according to Keshaw Kumar (1990)16 who observed that dominant coronary artery not only gives posterior interventricular artery but also the nodal artery. Duplication of right and left circumflex arteries ensured profuse blood supply to the upper part of both the ventricles.

REFERENCES

1. Abbott, M.E. Congenital cardiac disease : Anomalies of the coronary arteries, Mod. Medicine, Lea and Febiger, Philadelphia (1927) Vol. 4 : 612.
2. Blake, H.A. Manion, W.C. Mattingly, T.W. and Baroldi, G. Coronary artery anomalies. Circulation (1964) Vol. 30 : 927.
3. Hallman, G.L. Cooley, D.A. and Singer, D.B. Congenital anomalies of the coronary arteries : anatomy, pathology and surgical treatment. Surgery (1966) Vol. 58 : 133.
4. Ogden, J.A. Congenital anomalies of the coronary arteries. Am. J. Cardiol (1970) Vol. 25 : 474.
5. Askenazi, J. and Nadas, A.S. Anomalous left coronary artery originating from the pulmonary artery. Report on 15 cases. Circulation. (1975) Vol. 51 : 976.
6. George, J.M. and Knowlan, D.M. Anomalous origin of left coronary artery from the pulmonary artery in the adult N. Engl. J. Med. (1959) Vol. 261 : 933.
7. Keith, J.D. Anomalous origin of left coronary artery from the pulmonary artery. Br. Heart. J. (1959) Vol. 21 : 149.
8. Wesselhoeft, H. Fawcett, J.S. and Johnson, A.L. Anomalous origin of left coronary artery from the pulmonary trunk. Its clinical spectrum, pathology, and pathophysiology based on a review of 140 cases with seven further cases. Circulation (1968) Vol. 38 : 403.
9. Flamm, E. Stinson, B. Hultgreen, H.N. Shumway, N.E. Hancock, E.W. Anomalous origin of left coronary artery from pulmonary artery. Circulation (1968) Vol. 38 : 113.
10. Ott, D.A. Cooley, D.A. Pinskey, W.W. Mullins, C.E. Anomalous origin of circumflex artery from right pulmonary artery. Report of a rare anomaly. J. Thorac. Cardiovas. Surg. (1978) Vol. 76 : 190-194.
11. Keshaw Kumar. Anomalous course and branches of human coronary arteries. Acta Anatomica (1989) Vol. 136 : 315-318.
12. Smith, J.C. Review of single coronary artery with report of two cases. Circulation (1950) Vol. 7 : 1168-1175.
13. Sharbaugh, A.H. and White, R.S. Single coronary artery. Analysis of anatomic variation. Clinical importance and report of five cases. J.A.M.A. (1974) Vol. 230 :243.
14. Keshaw Kumar. Duplication of branches in human coronary arteries. Journal of Anatomical Sciences. (1994) Vol. 13 : 9-12.
15. Keshaw Kumar. Anterior interventricular artery replacing left coronary artery with absence of arterial anastomosis in human heart. Journal of Anatomical society of India (2006) Vol. 55 (1) : 42-44.
16. Keshaw Kumar. Comparative anatomy of coronary arteries-A gross study in mammals. Journal of Anatomical Sciences. (1990) Vol. 12 : 45-51.