ORIGINAL RESEARCH PAPER

Volume-8 | Issue-7 | July - 2019 | PRINT ISSN No. 2277 - 8179

INTERNATIONAL JOURNAL OF SCIENTIFIC RESEARCH

DYKE-DAVIDOFF- MASSON SYNDROME

Radiodiagnosis

Gowthami M

Athira P M* *Corresponding Author

Kuku Mariam Suresh

Rachegowda. N

ABSTRACT

Dyke-Davidoff-Masson syndrome (DDMS) is a rare disorder characterized by recurrent seizures, facial asymmetry, contralateral hemiplegia, radiologic features of cerebral hemiatrophy, and ipsilateral compensatory hypertrophy of the skull bone and sinuses due to cerebral injury that may occur in early childhood or fetal life. We describe two cases of DDMS, who initially presented with refractory seizures to the departments of Pediatrics and Medicine at Sri Devaraj Urs Medical College and Hospital. First case is of a 12 year old male with right hemiparesis and seizures since 3 months, CT & MRI brain revealed diffuse mild atrophy with paucity of white matter in the left cerebral hemisphere involving ipsilateral thalamus and midbrain, left cerebral hemiatrophy and chronic left MCA infarct with adjacent gliotic changes. Another case is of 35-year-male referred for right hemiplegia and uncontrolled seizures for 5 years, CT brain revealed thickening of cranial vault, pneumatosis dilatans of bilateral frontal sinuses, left cerebral hemiatrophy, and right cerebellar infarct and pneumatoencephalographic changes. In each case, the clinical features were noted along with computed tomography or magnetic resonance imaging which helped in confirming the diagnosis of DDMS. Therefore DDMS should also be considered as a differential diagnosis of refractory seizures.

KEYWORDS

Dyke-Davidoff-Masson syndrome, DDMS, Cerebral hemi-atrophy, Refractory epilepsy.

INTRODUCTION

Dyke-Davidoff-Masson syndrome (DDMS) is characterized by the presence of hemiatrophy of one cerebral hemisphere, which is usually a consequence of an insult to the developing brain. This condition is clinically characterized by facial asymmetry, contralateral spastic hemiplegia or hemiparesis, mental retardation, and refractory seizure. A refractory seizure is usually the presenting feature of this condition and often poses a therapeutic challenge to the treating physician. The radiological features of DDMS are distinctive, and may include cerebral hemiatrophy with several parenchymal changes and ipsilateral compensatory hypertrophy of the skull bone and sinuses.[1,2]

We describe two cases of patients with DDMS found while investigating cases of refractory epilepsy and stroke, one in adult group and other in paediatric age group presenting with hemiparesis, their clinical features and CT and MRI brain revealed the features of Dyke-Davidoff-Masson syndrome. It is commonly diagnosed in childhood but is rarely diagnosed in teenagers and adults.

CASE REPORT

A 12 year old male, second-born child of healthy non-consanguineous parents. The mother reported no exposure to teratogens during pregnancy. No family history of birth defects and neurologic or cognitive impairment was reported. Patient was delivered by normal full term vaginal delivery. He had history of weakness involving right half of the body, non-progressive in nature and generalized tonic-clonic seizures since age of childhood. His mother revealed history of developmental delay involving gross motor milestones, now presented in emergency department with history of three episodes of convulsions involving right upper and lower limb lasting for three minutes, associated with up rolling of eye balls, four episodes of projectile vomiting and postictal confusion associated with headache. There was no history of similar illness in any other sibling or family member. On examination, patient was conscious, vitals were stable, there was no phakomatosis, and neurological examination revealed 4/5 power in right upper and lower limb with brisk reflexes. Right plantar was extensor. There was no neck rigidity, any sensory deficit, cranial nerve or bowel bladder involvement.

All routine hematological and biochemical investigations were within normal range.

CT brain plain-

- Left cerebral hemisphere shows hemi atrophy with small ipsilateral thalamus and mid brain segments along with mild ex vacuo dilatation of ipsilateral lateral ventricle.
- Ipsilateral calvarium shows relatively increased diploic space in comparison to opposite side.
- Mild elevation of left petrous ridge noted in comparison to right side.
- An ill-defined hypoattenuating CSF density lesion seen in the left MCA territory extending to ipsilateral ganglio-capsular and periventricular white matter showing adjacent gliotic changes suggestive of chronic MCA infarct.
- Mild prominence of sulcal, cisternal and ventricular spaces noted on the left side.
- Similar findings were confirmed on MRI brain,

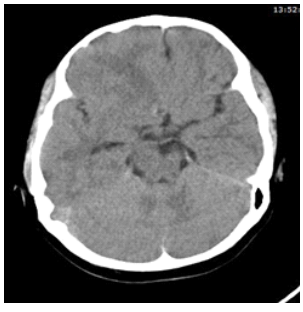

Fig 1,Axial CT reveals left cerebral hemiatrophy & left midbrain atrophy.



Fig 2, Axial CT reveals left cerebral atrophy with prominent sylvian fissure .



Fig 3 , Axial CT reveals glial changes in left sylvian fissure with small left thalamus.

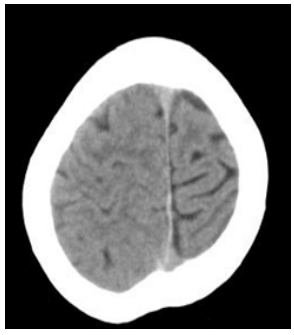

Fig 4, Axial CT reveals prominent sulci on left side and asymmetry of cerebral ispheres.

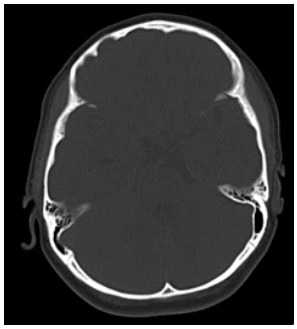

Fig 5, Axial CT bone window shows elevated left petrous ridge.

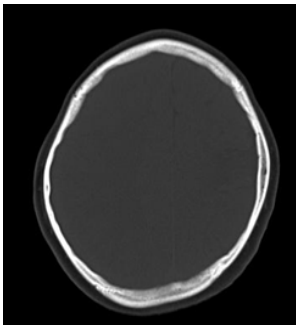

Fig 6, Axial CT bone window shows mild calvarial hypertrophy on left side.

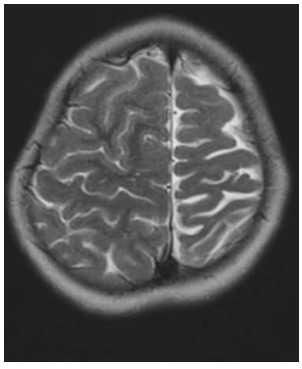

Fig 7, Axial MRI T2WI shows left cerebral hemiatrophy with prominent sulcal spaces.

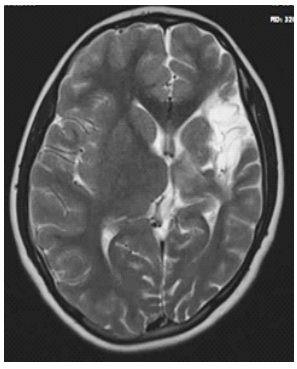

Fig 7, Axial MRI T2WI shows left cerebral hemiatrophy with atrophic changes in left sylvian fissure.

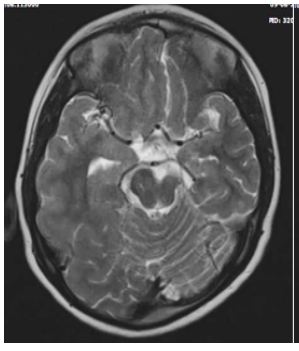

Fig 8, Axial MRI T2WI shows left cerebral hemiatrophy with atrophy of left cerebral peduncle.

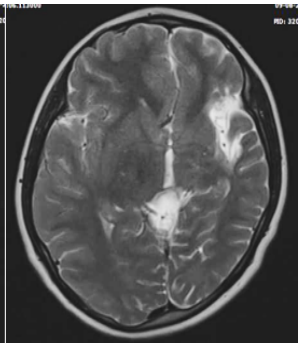

Fig 9, Axial MRI T2WI shows left cerebral hemiatrophy with small left thalamus.

CASE REPORT

A 35 years male presented with complaints of weakness of right upper and lower limbs since 5 yrs. There was history of generalized tonic clonic seizures from 5 years, on phenytoin and phenobarbitone, seizures recurred 4-5 episodes in a month inspite of medication. Other drugs he was on were aspirin, clopidogrel and atorvastatin. Also patient was withdrawn, not interacting with the family members and was on respiridone. Right hemiparesis improved over time and patient started to walk with support of stick. No history of head trauma, cardiac illness, diabetes, hypertension, disturbed bowel and bladder symptoms.

Birth history and milestones were uneventful. There was no history of cyanosis, jaundice, and encephalitis or head injury in the neonatal period. There was no history of patient's mother having had any febrile illness in early pregnancy. His scholastic performance was average.

On examination, the vitals were stable, there were no phakomatosis, patient had scanning speech, his Mini mental scale examination was 20/30, angle of mouth deviated to left, hypotonia, hyperreflexia and cerebellar signs were found on the right side. His lipid profile, carotid Doppler and cardiac workup was normal.

CT brain plain-

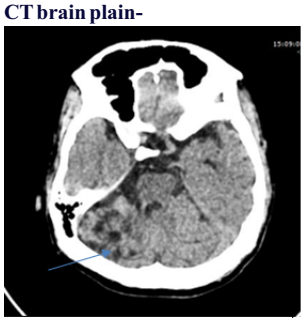

Fig 10, Axial CT brain image show multiple focal hypodense areas in the right cerebellar hemisphere.



Fig 11, Axial CT brain image demonstrates left sided cerebral hemiatrophy in the form of prominent sulcal and gyral spaces and ectatic ventricle ipsilaterally

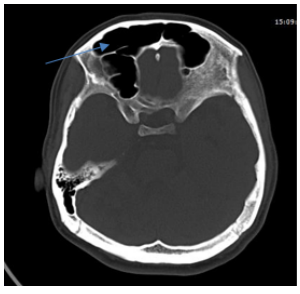

Fig 12, Axial CT brain bone window showing hyperpneumatisation of bilateral frontal sinuses.

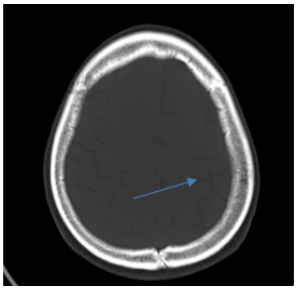

Fig 13, Axial CT brain bone window demonstrates left left sided calvarial cortical thickening and sclerosis.

DISCUSSION

An attempt in controlling refractory epilepsy is a challenge. Identifying the cause for epilepsy is essential in planning management. Neuroimaging is one of the main tools used in the investigation of epilepsy. There are many syndromes which are associated with refractory epilepsies.[1]

Dyke Davidoff Masson syndrome is one such rare syndrome which was described first in 1933 in which Dyke, Davidoff and Masson presented a series of nine patients, who were characterized by hemiparesis, facial-asymmetry, seizures and mental retardation clinically and described the plain skull radiographic and pneumatoencephalographic changes in them.[1]

DDMS or hemispheric infarction is a childhood unicerebral atrophy or hypoplasia with compensatory ipsilateral hypertrophy of the calvarium. [2]

Clinical features may be present in varying combinations or degree of severity. Both sexes are equally affected and any of the cerebral hemispheres, but more common in male gender and left cerebral hemisphere is being proposed in various studies which is also seen in our case studies. [3]

Subtotal or diffuse cerebral hemiatrophy is a classical imaging finding. Unilateral focal atrophy may occasionally be noted in the cerebral peduncles and the thalamic, pontine, crossed cerebellar, and parahippocampal regions. Brain imaging may additionally reveal prominent cortical sulci, dilated lateral ventricles and cisternal space, calvarial thickening, ipsilateral osseous hypertrophy with hyper pneumatization of the sinuses (mainly frontal and mastoid air cells), and an elevated temporal bone. [3]

Developing brain reaches half of its adult size during the first year and three-fourths of that size by the end of the third year. As it enlarges, the brain presses outward on the bony tables causing gradual enlargement and general shape of the adult head. When the brain fails to grow, the other structures tend to direct their growth inward; thus, leading to enlargement of the frontal sinus, increased width of the diploic space and the elevations of the greater wing of sphenoid and the petrous ridge on the affected side. These changes can occur only when brain damage is sustained before three years of age. [4]

DDMS can be classified as congenital or acquired. There is usually no apparent aetiological factor and the symptoms are generally present at birth in the congenital type. The cerebral insult in this type occurs likely during intrauterine life that may be due to intrauterine vascular occlusion. Whereas in the acquired type, the symptoms are related to disease central nervous system damage that occurs during the perinatal period or later. Among the aetiological factors are trauma, infection, vascular abnormality, ischemic and hemorrhagic conditions, coarctation of the midaortic arch and intraventricular haemorrhage of premature infants.[5,6,7]

The mechanism of cerebral atrophy and the related progressive neurodeficit is due to several ischemic episodes resulting from different causes, which reduce the production of brain-derived neurotrophic factors, which in turn leads to cerebral atrophy. [8]

Traditional radiologic evaluation of cerebral hemi atrophy initially included plain skull radiography and pneumoencephalography. The skull changes are unilateral and consist of calvarial thickening with loss of convolutional markings of the inner table of the skull, overdevelopment of the frontal, ethmoid sinuses and of the mastoid air cells with elevation of the petrous ridge may also be present. These changes reflect adaptation to unilateral decrease of brain substance.[1]

Analysis in series showed that a slight unilateral calvarial thickening may be difficult to assess on plain skull radiographs and can be easily missed, particularly if a proper clinical history is not available and also state that CT is superior to plain skull films in the evaluation of the cranial fossae.[6]

In a study, they showed that manifestations of DDMS may be so subtle to be overlooked on plain radiographs; however, CT/magnetic resonance imaging (MRI) is the diagnostic modality of choice.[2]

Shen et al, described three patterns of MRI showing cerebral hemiatrophy: MRI pattern I corresponds to diffuse cortical and subcortical atrophy; pattern II corresponds to diffuse cortical atrophy coupled with porencephalic cysts and pattern III corresponds to previous infarction with gliosis in middle cerebral artery territory. [9]

In a study, there was presence of microcephaly, hypospadias and pachygyria associated with DDMS.[10]

Malik et al [11], said that age of presentation depends on the time of neurologic insult, and characteristic changes may be seen only in adolescence. He continued that clinical findings may be of variable degrees of atrophy of one half of the body, sensory loss, speech and language disorder, mental retardation or learning disability and psychiatric manifestations like schizophrenia may also be present.

Kyung-Il Park et al [12], studied in siblings and reported that DDMS might have a familial predisposition and they also said that clinical courses and radiological findings of DDMS varied even within one family.

Zawar et al [13], presented a particular case with clinical significance of DDMS as an underlying cause of statue epilepticus.

Above three studies have shown a possible etiological relation between cerebral atrophy and seizures in patients with DDMS [14,15,16].

Krishnendu Roy et al [17], in a case showed hemicerebral atrophy in the context Takayasu arteritis with a clinical picture similar to DDMS.

Karuppiah et al [18], reported a case of an adult lady with DDMS as a complication of cerebral malaria.

Etori et al [19], described a child with diagnosis of prenatal ventriculomegaly as indirect finding of cerebral parenchymal involvement in which Contrast- Enhanced MRI angiography allowed the earliest diagnosis of congenital DDMS.

Initial treatment is based on control of the seizures with suitable anticonvulsants regimen. Along with drugs, physiotherapy, occupational therapy, and speech therapy also play a significant role in the long-term management.

Prognosis is better if the onset of hemiparesis is after 2 years of age and in the absence of prolonged or recurrent seizure.

Hemispherectomy is the treatment of choice for children with intractable seizures and hemiplegia with a success rate of 85% in selected cases.[20]

The differential diagnosis of this syndrome includes Sturge-Weber syndrome, Rasmussen encephalitis, Silver-Russell syndrome, basal ganglia germinoma, Fishman syndrome, and linear nevus syndrome. These conditions can be differentiated by performing a clinical examination and neuroimaging. [6]

Encephalotrigeminal angiomatosis commonly known as Sturge-Weber syndrome is characterized by port-wine stain, seizures, glaucoma, mental retardation, and recurrent stroke-like episodes. The underlying pathology includes intracranial vascular anomaly and leptomeningeal angiomatosis with stasis resulting in ischemia underlying the leptomeningeal angiomatosis which leads to intracranial tram track calcification with laminar cortical necrosis and atrophy. [21]

Rasmussen encephalitis is a condition seen in children between 6 and 8 years of age. It is a chronic progressive immune-mediated disorder seen with presenting complaints of intractable focal epilepsy, cognitive defects and hemispheric atrophy, calvarial changes are not seen in this condition. [22]

Silver-Russell syndrome is a condition with hemihypertrophy characterized by the classical facial phenotype (triangular face, small pointed chin, broad forehead, and thin wide mouth), poor growth with delayed bone age, clinodactyly, with normal head circumference, and normal intelligence. [23]

Basal ganglia germinoma, a rare tumor of the brain, there is progressive hemiparesis and imaging findings reveals cerebral hemiatrophy, cystic areas, focal hemorrhages. There is mild surrounding edema along with calvarial changes which helps in differentiating it from DDMS. [24]

Fishman syndrome or encephalocraniocutaneous lipomatosis is a rare neurocutaneous syndrome presenting with seizures and shows imaging features of calcified cortex and hemiatrophy. They are characterized by unilateral cranial lipoma with lipodermoid of the eye. [25]

Linear nevus syndrome is a condition characterized by unilateral ventricular dilatation resembling cerebral hemiatrophy, facial nevus, recurrent seizures and mental retardation.[26]

CONCLUSION

DDMS should be considered as a differential diagnosis of refractory seizures in children. Along with a detailed history and complete clinical examination, neuroimaging is imperative for correct diagnosis and proper management of such patients.

REFERENCES.

1. Dyke CG, Davidoff LM, Masson CB. Cerebral hemiatrophy and homolateral hypertrophy of the skull and sinuses. Surg Gynecol Obstet 1933;57:588–600.
2. Goyal, J., Shah, V., Rao, S., & Jindal, N. (2009). Dyke Davidoff Masson syndrome in Children. The Internet Journal of Pediatrics and Neonatology, 10(2)
3. Unal O, Tombul T, Cirak B, Anlar O, Incesu L, Kayan M: Left hemisphere and male sex dominance of cerebral hemiatrophy (DDMS). Clin Imaging 2004;28:163–165.
4. Parker CE, Harris N, Mavalwala J. DykeDavidoff-Masson syndrome. Five case studies and deductions from dermatoglyphics. Clin Pediatr (Phila) 1972; 11: 288-292.
5. Alpers BJ, Dear RB. Hemiatrophy of the brain. J Nerv Ment Dis 1939;89:653–71.
6. Zilkha A. CT of cerebral hemiatrophy. AJR Am J Roentgenol 1980;135:259–62.
7. Sener RN, Jinkins JR. MR of craniocerebral hemiatrophy. Clin Imaging 1992;16:93–7.
8. Ono K, Komai K, Ikeda T: Dyke-Davidoff-Masson syndrome manifested by seizure in late childhood: a case report. J Clin Neurosci 2003;10:367–371.
9. Shen WC, Chen CC, Lee SK, et al. Magnetic resonance imaging of cerebral hemiatrophy. J Formos Med Assoc 1993;92:995–1000.
10. Bhawna Sharma, Kadam Nagpal, Rahul Handa, Indu Bhana: Dyke-Davidoff-Masson syndrome:a clinicoradiological amalgam 2014(Sharma B, et al. BMJ Case Rep 2014. doi:10.1136/bcr-2014-204679).
11. Malik, Garg, Gulia, et alIranian J Psychiatry 9:1, March 2014 ijps.tums.ac.ir
12. Kyung-Il Park, Jae-Myun Chung, Ji-Young Kim. Dyke-Davidoff-Masson Syndrome: Cases of Two Brothers and Literature Review. Journal of Epilepsy ResearchJournal. 2014
13. Ifrah Zawar, MBBS, Ashfa A. Khan, FCPS,Tipu Sultan, FCPS, MSc, Ahsan W. Rathore, FCPS. Dyke-Davidoff-Masson Syndrome An unusual cause of status epilepticus. J Neurosciences 2015; Vol. 20)4.
14. Narain NP, Kumar R, Narain B. Dyke-DavidoffMasson syndrome. Indian Pediatr 2008; 45:927-928.
15. Sener RN, Jinkins JR. MR of craniocerebral hemiatrophy. Clin Imaging 1992; 16: 93-97.
16. Nair KP, Jayakumar PN, Taly AB, Arunodya GR, Swamy HS, Shanmugam V. CT in simple partial seizures in children: a clinical and computed tomography study. Acta Neurol Scand 1997; 95: 197-200.

17. Krishnendu Roy,Arunansu Talukdar,Dyke-Davidoff-Masson syndrome-like picture in a case of Takayasu arteritis: an enigma. BMJ Case Reports 2012
18. Karuppiah S, Rodgman C, Lombard J. Dyke-Davidoff-Masson syndrome in postcerebral malaria. J Child Neurol. 2009; 24: 487-90.
19. Ettore Piro, Maria Piccione, Gianluca Marrone, Mario Giuffrè and Giovanni Corsello, Dyke-Davidoff-Masson syndrome: case report of fetal unilateral ventriculomegaly and hypoplastic left middle cerebral artery. Italian Journal of Pediatrics 2013, 39:32.
20. Behera MR, Patnaik S, Mohanty AK. Dyke-Davidoff-Masson syndrome. J Neurosci Rural Pract 2012; 3(3): 411-3.
21. Thomas-Sohl KA, Vaslow DF, Maria BL: Sturge-Weber syndrome: a review. Pediatr Neurol 2004;30:303–310.
22. Sheybani L, Schaller K, Seeck M: Rasmussen encephalitis: an update. Schweiz Arch Neurol Psychiatr 2011;162:225–231.
23. Qiu BP, Shi CH: Silver-Russel syndrome: a case report. World J Pediatr 2007;3:68–70.
24. Moon WK, Chang KH, Kim IO, Han MH, Choi CG, Suh DC, Yoo SJ, Han MC: Germinomas of the basal ganglia and thalamus: MR findings and a comparison between MR and CT. AJR Am J Roentgenol 1994;162:1413–1417.
25. Amar DJ, Kornberg AJ, Smith LJ: Encephalocraniocutaneous lipomatosis (Fishman syndrome): a rare neurocutaneous syndrome. J Pediatr Child Health 2000;36:603–605.
26. Jacoby CG, Go RT, Hahn FJ: Computed tomography in cerebral hemiatrophy. AJR Am J Roentgenol 1977;129:5–7.