Volume : 3 | Issue : 1 | January 2014 • ISSN No 2277 - 8179

Research Paper

Ectopic Pancreatic Tissue As a Lead Point in Ileo Ileal Intussusception in a Young Adult – a Case Report

Medical Science

KEYWORDS : Ectopic pancreatic tissue, lead point ,ileo ileal Intussusception

Dr. Deepak Vora	Assistant Professor, Dept. Of General Surgery, Smt. N.H.L. Municipal Medical College, Sheth V.S. Hospital, Ellis Bridge, Ahmedabad – 6.
Dr. Mithil Gajjar	Resident Doctor, Dept. Of General Surgery, Smt. N.H.L. Municipal Medical College, Sheth V.S. Hospital, Ellis Bridge, Ahmedabad – 6.
Dr. Pankaj Pandor	Resident Doctor, Dept. Of General Surgery, Smt. N.H.L. Municipal Medical College, Sheth V.S. Hospital, Ellis Bridge, Ahmedabad – 6.
Dr. Mukesh Chaudhary	Resident Doctor, Dept. Of General Surgery, Smt. N.H.L. Municipal Medical College, Sheth V.S. Hospital, Ellis Bridge, Ahmedabad – 6.
Dr. Khyati Shah	Resident Doctor, Dept. Of General Surgery, Smt. N.H.L. Municipal Medical College, Sheth V.S. Hospital, Ellis Bridge, Ahmedabad – 6.

ABSTRACT

A patient underwent emergency exploratory laparotomy and resection and primary anastomosis for small bowel obstruction. Ectopic pancreatic tissue was identified in the histopathological examination of resected segment of ileum (ileal heterotopic pancreas) which is rare. Pre operative diagnosis of this condition is extremely difficult.

INTRODUCTION:

Intussusception is a condition characterized by the telescoping of a segment of intestine into the other, most commonly the proximal into the distal. It clinically presents as features of small bowel obstruction such as abdominal pain, constipation, vomiting and abdominal distention, in varying proportions. Intussusception is a type of closed loop obstruction, which can lead to gangrene.

Ectopic pancreatic tissue is a recognized but rare lead point in ileo ileal intussusceptions. Ectopic pancreas is not an extremely rare pathological condition. It is defined as the presence of pancreatic tissue lacking anatomical and vascular continuity with the pancreas. It occurs most commonly in the stomach, duodenum, and jejunum and has been reported in other locations, including the ileum, Meckel's diverticulum, majority of the cases have been found incidentally at laparotomy performed for other abdominal diseases.

Ectopic pancreas rarely occurs as intestinal invagination leading to ileus in adults. Here, we describe a rare case of small ileal ectopic pancreas that led to ileo ileal Intussusception and ileus.

CASE REPORT:

A 17 year old male patient admitted with history of severe abdominal pain, bilious vomiting for 3-4 days which not relieved by medications.Clinical signs and symptoms are suggestive of intestinal obstruction. The patient was resuscitated hemodynamically. Ultra Sonography abdomen and erect abdomen x-ray revealed findings suggestive of ileo ileal Intussusception. Emergency exploratory laparotomy was performed.

Per operative findings were ileo ileal Intussusception 20-25 cm



FIG 1: PER OPERATIVE SPECIMEN OF INTUSUSSCEPTION

proximal to ileo caecal junction. Gangrenous segment of around 5 cm of the ileum was resected and primary Anastomosis done. Resected segment was sent for histopathological examination. Histopathological examination was suggestive of ectopic pancreatic tisse. Patient was discharged on 7th postoperative day and was followed uneventfully.

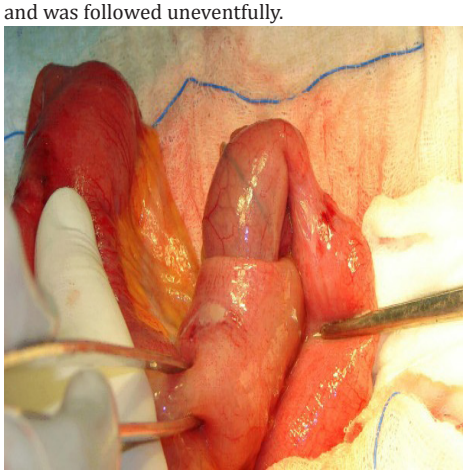

Volume : 3 | Issue : 1 | January 2014 • ISSN No 2277 - 8179

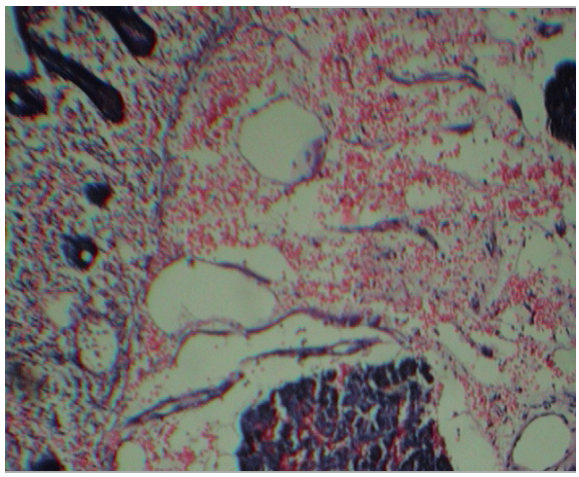

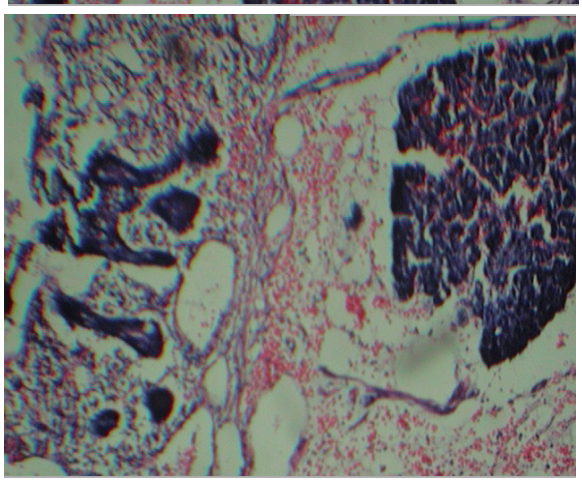

DISCUSSION:
As stated by Hunt and Bonesteel (5) the first case of heterotopic pancreas was reported by Schultz in 1729, and Klob provided its histological confirmation in 1859 (6). The reported incidence in autopsy studies is 0.5-13% (3). In adults it occurs preferentially in males between the fourth and sixth decades of life. It is found mainly in the stomach, duodenum and jejunum, in much smaller proportions in the ileum and Meckel's diverticulum, and it is rarely found in the esophagus, liver, gallbladder, omentum, lungs, mediastinum, fallopian tubes and umbilicus (2). In adults the incidence is higher in males, while in pediatric patients the female gender prevails. The aetiology is unknown. The proposed theory is that during rotation of foregut in a fetus and fusion of dorsal and ventral parts of pancreas, small islands of pancreas are carried away and continue to develop at its aberrant location (2).

The occasional symptoms are bleeding, vomiting or abdominal pain due to pancreatitis, intestinal obstruction or Intussusception is rare. Ectopic pancreas in the small intestine may rarely be fatal. Adult Intussusception represents 5% of all cases of Intussusception and accounts for only 1%-5% of intestinal obstructions in adults. In contrast with Intussusception in children, nearly all adult cases have primary causes such as a polyp, an SMT or a malignant tumor that needs to be resected. In the present case, the small SMT (ectopic pancreas) in the ileum caused ileus due to Intussusception.

The diagnosis of heterotopic pancreas still remains challenging. The preoperative imaging studies (ultrasonography, endoscopic ultrasonography and computerized tomography) are not very specific (3). Double-balloon enteroscopy or capsule endoscopy is the recent modalities of investigations. Hence, in the majority of cases, the diagnosis is made by histological evaluation following resection of a symptomatic or suspicious lesion (10). When symptomatic, the lesion should be resected. The management of asymptomatic, histologically verified heterotopic pancreas or those found incidentally during other surgery is under debate. Some authors recommend resection in these asymptomatic cases to prevent later complications.

CONCLUSION:
We have reported a very rare case of ileal ectopic pancreas that leads to ileo ileal Intussusception. This etiology should be suspected in a patient with chronic atypical abdominal pain.

REFERENCE

1. Ishikawa O, Ishiguro S, Ohhigashi H, Sasaki Y, Yasuda T, Imaoka S, Iwanaga T, Nakaizumi A, Fujita M, Wada A. Solid and papillary neoplasm arising from an ectopic pancreas in the mesocolon.Am J Gastroenterol. 1990;85:597–601. [PubMed] | 2. Bromberg SH, Neto CC, Borges AFA, Franco MIF, França LCM, Yamaguchi N. Pancreatic heterotopias: clinicopathological analysis of 18 patients Rev. Col. Bras. Cir. 2010; 37: 413–9. | 3. Gokhale UA, Nanda A, Pillai R, Al-Layla D. Heterotopic pancreas in the stomach: A case report and brief review of the Literature. J Pediatr 2010;11:255–7 | 4. Pang LC. Pancreatic heterotopia: a reappraisal and clinicopathologic analysis of 32 6. Jochimsen PR, Shirazi SS, Lewis JW. Symptomatic ectopic pancreas relieved by surgical excision.Surg Gynecol Obstet. 1981;153:49–52. [PubMed] | 5. Hunt VC, Bonesteel HTS. Meckel's diverticulum containing aberrant pancreas.Arch Surg 1934;28:425–39 | 6. Klob J. Pancreas accessorium. Zeitschrift der Kaiserl. Königl. Gesellschaft der Aerzte zu Wien 1859; 15:732 | 7. Chandra N, Campbell S, Gibson M, Reece-Smith H, Mee A. Intussusception caused by a heterotopic pancreas. Case report and literature review. JOP. 2004;5:476–479. [PubMed] | 8. Heinrich H. The histology of a contributory tissue. Accessory pancreas. Virchows Arch Pathol Anat 1909;198:392–401 | 9. Seneviratne SA, Ramanayaka IT, Samarasekara DN. Heterotopic pancreas in the body of stomach. Ceylon Med J 2009; 54:57–8 | 10. Liu YM, Shen HP, Li X, Gong JP. Heterotopic pancreas: a clinical analysis of nine patients and review of literature. Am Surg. 2012;78:E141–3 |