Volume : 4 | Issue : 11 | November 2015 • ISSN No 2277 - 8179

Research Paper

Zoology

KEYWORDS :

EFFECT OF DMPA ON PROSTATE GLAND OF INDIAN PALM SQUIRREL, *FUNAMBULUS PENNANTI*

M.S.Sastry Department of Zoology, RTM Nagpur University, Nagpur-440033

S.S. Gupta Department of Zoology, Amolakchand Mahavidyalaya, Yavatmal-445001

ABSTRACT

DMPA, Depot Medroxy Progesterone Acetate is a strong anti-progestin and anti- fertility drug. In the present study the effect of DMPA on the prostate gland of male squirrel was investigated and an attempt was made to assess whether testosterone could be used to protect prostate gland from DMPA toxicity. The changes in prostate gland consisted of reduction in the size of acinus and secretion, an increase in fibro-muscular tissue, reduction in folding of secretory epithelium with reduction in the height, reduction in the density and quantity of colloid or its total loss, vacuolation of epithelium, pyknosis, condensation and displacement of nuclei suggesting DMPA's role of an alteration in function of accessory glands, which are essentially indirect manifestations of hypo-androgenism.

Introduction

The prostate gland is an important accessory organ as its weight and morphological appearance serve as an end point to study the biological activity of antifertility drug. The prostate is an exocrine sexual or tubule-alveolar gland found in all mammals that produces important substances such as enzyme, amines, lipids, metal ions and citric acid for the potency of sperm to fertilize egg within the female reproductive tract (Costello and Franklin, 1994). The prostatic epithelial growth and morphogenesis were found to be dependent upon an epithelial mesenchymal interaction, which in turn is regulated by androgen (Steins and Helpap, 1981; Cunha et al. 1983; Lee et al. 1994; Cunha, 1985; Kiplesund et al. 1988; Robaire and Hermo, 1988; Nemeth et al. 1998). Normal prostatic growth, development and functional activity are clearly dependent upon interactions between stroma and epithelium, epithelial response to androgen is mediated indirectly through soluble factors produced by the stroma (Cunha et al. 1985). Stromal-epithelial interactions plays a critical role in the developmental regulation of the prostate (Blanchere et al. 2001).

Material and Methods

Adult male palm squirrels weighing between 100 to 150gms were trapped alive in and around Nagpur during the breeding period from January to July, 2001(Reddi and Prasad, 1968). After a week of acclimatization to Laboratory conditions DMPA (Upjohn USA) and DMPA with Sustanon (a combination of testosterone ester) dissolved in olive oil was administered intramuscularly. The control animals Table-I received same amount of olive oil instead. Animals were sacrificed using chloroforms 24hrs after the last injection of the experiment. Immediately, prostate gland was excised and fixed in Bouin's solution, dehydrated in ethanol and embedded in paraffin wax. The sections cut at 5µ stained with haemotoxylene and eosin was used to study histological changes in the prostate gland.

TABLE-I

Squirrels were divided into groups and treated as follows:-

Group I - served as controls and received the vehicle (1ml of olive oil) intra muscularly daily for 30 days.

Group II - served as experimental and received a daily dose of 1mg DMPA diluted in 1ml of olive oil intramuscularly daily for30 days.

Group III - served as maintenance group and received DMPA (1mg daily 30days) but also received a daily dose of 0.1mg Sustanon intramuscularly daily for 30 days.

TABLE-1 Experimental Design

Number of animals and sex	Treatment	Dose mg/Kg BW	Route	Duration
6 males (control)	Olive oil	E.V.	I.P.	30 days
6 males (Experimental)	DMPA	1mg daily	I.P.	30 days
6 males (Experimental)	DMPA + Sustanon	0.1mg DMPA+1mg Sustanon daily	I.P.	30 days

Abbreviations : E.V. = Equal volume, I.P. = Intraperitoneal, B.W. = Body weight

Histological assessment

The animals were sacrificed using chloroform 24 hours after the last day of each experiment. Immediately the, prostate glands were excised, weighed on an analytical balance and fixed in Bouin's fluid for 24hrs and preserved in 70% alcohol, dehydrated in ethanol and embedded-in paraffin wax. For the present study ventral lobe was utilized. The sections cut in 5µm were stained with haematoxylin and counter-stained with eosin. Measurements were taken with an ocular micrometer wherever essential.

Testosterone evaluation

For the determination of testosterone level in blood, Palm squirrels were anesthetized by ether and 2ml of blood was drawn by cardiac puncture with 2ml sterile syringe. The blood was allowed to clot at room temperature for half an hour. The clotted blood was sent to NRPL Pathology laboratory, Nagpur for further processing by enzyme linked-florescent assay (Delahunt and Hirsutism, 1993).

Statistical analysis

To indicate individual variations in each corresponding region, the mean values and standard deviation (mean ± SD) for measurements from three animals were calculated. The statistical significance of differences for these values in different regions was assessed using t-test (Delgaard et al. 2008). A significant level of P<0.05 was accepted.

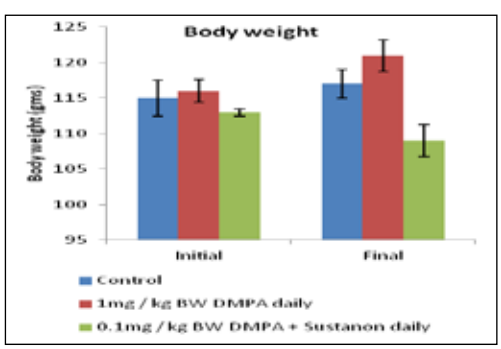

Volume : 4 | Issue : 11 | November 2015 • ISSN No 2277 - 8179

Graph 1. : Body weight changes over the course of 30 days treatment with DMPA and DMPA+Sustanon, expressed as weight on the last day of treatment divided by weight on the first day of treatment (Control n=6, DMPA n=6,DMPA+Sustanon n=6). DMPA+Sustanon treated squirrels did not gain as much weight as the control squirrels. *P<0.05

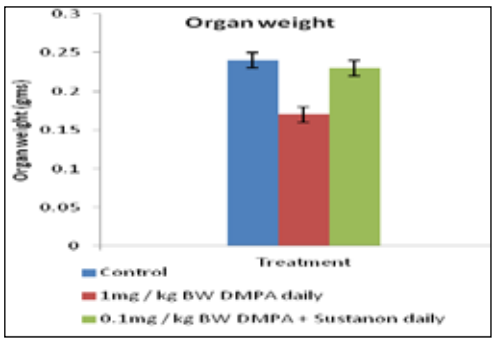

Graph 2. : Weight of prostate gland after 30 days treatment with vehicle or DMPA and DMPA+Sustanon (Control n = 6, DMPA n = 6, DMPA+Sustanon n=6). There was a significant decrease in the weight of prostate gland of the DMPA treated animals.* P < 0.001.

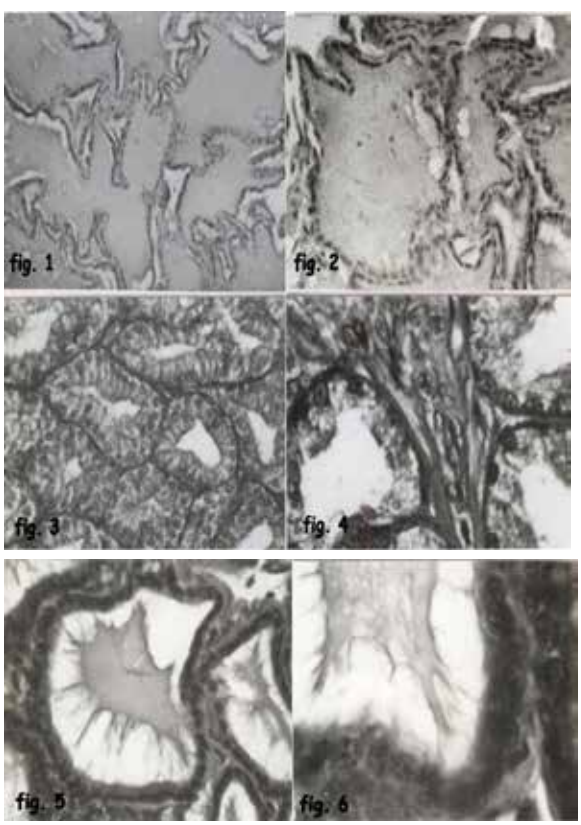

Fig. 1: Prostate gland vehicle-treated control squirrel. Transverse section through prostate gland illustrating large acini with infoldings and central lumen filled with copious amount of secretion X80.

Fig. 2: A single acini magnified from the prostate, Each acinus lined by flat squamous epithelium X 144.

Fig. 3: Prostate of 1mg DMPA injected daily for 30 days showing empty closely packed prostatic acini X 144.

Fig. 4: Few prostatic acini enlarged showing empty acinus encased in thick connective tissue capsule lined by highly regressed columnar epithelium with basal large nucleus. Also note hyper-plastic and myxoid nature of the inter-acinal stroma (arrow) X324.

Fig. 5: Prostate gland from recovery group. The epithelium is shorter and has squamous appearance with concentrated secretion in the centre X144.

Fig. 6: A part of epithelium magnified showing short epithelium with dried secretion in the centre X324.

Results

DMPA treatment led to abdominal bloating, excess of fat deposits and therefore resulting into significant increase in body mass, whereas combination treatment resulted into an insignificant increase in body mass.

Evaluation of testosterone

The DMPA treatment (1mg/KgBW/day) showed significant decrease ($P < 0.1$) but the DMPA+Sustanon treatment (0.1mg DMPA+1mg Sustanon daily) resulted into insignificant increase ($P < 0.001$) in serum testosterone concentration when compared to control values

Histopathological changes

a) Vehicle-treated controls

The Prostate gland of control squirrels composed of normal columnar epithelium which appeared to be reduced to cuboidal and squamous because of great distention of tubules and copious amount of darkly stained secretion in the lumen. These large acini were isolated by moderate amount of fibromuscular tissue consisting of few typical spindle-shaped mesenchymal cells with large hyperchromatic nuclei (figs.1 and 2).

B) Chronic DMPA treatment for 30 days (1mg/KgBW/day)

1mg DMPA daily for 30 days affected Prostate gland severely. The treatment revealed remarkable reduction in the size of epithelium, enormous thickening of lamina propria, numeric reduction in the acinal cells, significant reduction in the height of the epithelium, extensive vacuolation, pyknosis, condensation and displacement of nuclei, reduction in the density and quantity of colloid or its total loss, highly regressed epithelium of the acini (figs. 3 and 4).

c) Chronic DMPA+Sustanon treatment for 30 days(0.1mg DMPA+1mg Sustanon daily)

Administration of Sustanon has restored the cytoarchitecture of the prostate gland to some extent as evidenced by enlargement in the size of acini, loss of vacuolation from the cuboidal secretory epithelium, an increase in the number of the cells, presence of secretion in the lumen (figs.4 and 5).

Discussion

The Prostate gland is absolutely dependent on adequate supply of circulating androgen for normal growth and maintenance of differntiated function. In the adult prostate, the presence of androgen also serves to maintain a homeostatic balance between cell proliferation and cell death, resulting in no net changes in the prostate size (Brandes, 1974; Luke and Coffey, 1994; Sastry and Kashmiri, 2011). The secretory activity and growth of prostate gland depend on androgen through its metabolism to a more potent 5α- dihydrotestosterone and its preferential retention within the nucleus where it is bound to androgen receptor via the action of 5α-reductase or due to 17ß hydroxysteroid dehydrogenase activity causing an increased conversion of testosterone to androstenodione or dihydrotestosterone to 5-androstenedione thus lowering intercellular concentration of DHT derived from testosterone. It appears that these may act on the accessory reproductive organ by preventing the androgen synthesis or by altering the protein binding or peripheral metabo-

lim (Steins and Helpap 1981; Kiplesund et al. 1988; Sastry and Gupta, 2008). The reduction or shrinkage of the prostatic acini were in equivalence with the increase of epithelial vacuolation and fibromuscular tissue defining stromal epithelial interactions (Spring –Mills et al. 1982; Chang and Wang, 1992; Blanchere et al. 2001; Dunker and Kreiglstein, 2000). The above mentioned changes also points to androgen dependency of the gland but administration of exogenous testosterone tried to restore the original condition. It was interesting to note that in combination treated group prostate gland achieved their secretory capacities, weight and general architecture near to control value as described by Flickinger et al. 1977 since the male accessory glands are highly dependent on androgenic hormones for their normal structure and function and is also very sensitive to the level of circulatory androgen (Nishino et al. 2004).

REFERENCE

Blanchere M, Mestayer C, Saunier E, Broshuis M and Mowszowicz I (2001) Transforming growth factor- in the human prostate : its role in stromal – epithelial interactions in non-cancerous cell culture. Prostate. 46: 311-318. Brandes D (1974) Hormonal regulation of fine structure. In Male Accessory Sex organs; Structure and Function in Mammals. Pp 184-222. Edited by D.Brandes, Academic Press, New York USA Chang L and Wong YC (1992) Cytochemical localization and characterization of the proteoglycans (glycosaminoglycans) in the epithelial-stromal interface of seminal vesicle of guinea pig. J. Anat. 180(1): 41-56 Costello LC and Franklin RB (1994) Effect of prolactin on the prostate. Prostate 24(3): 162-166. Cunha UR (1985) Prostatic epithelium morphogenesis growth and secretory cytodifferentiation are elicited via trophic influences from mesenchyme. In : Progress in cancer research and therapy, Eds. F. Bresciani, RJB King, ME Lipman, M Namer and JP Raynaud, New York Raven Press, 121. Cunha UR, Fuji H, Neubauer BL, Shanon JM, Sawyer L, Reese BA (1983) Epithelial mesenchymal interaction in prostatic development. I. Morphological observation of prostatic induction by urinogenital sinus mesenchyme in epithelium of adult rodent urinary bladder, J. Cell. Biol. 96 : 1662. Delgaard P (2008) Introductory statistics with R, 2nd edition Springer Verlag. Delahunt J, Hirsutism W (1993) Practical therapeutic guideline. Drugs. 45(2):223-231. Dunker N, Kreiglstein K (2000) Targetted mutations of transforming growth factor-beta genes reveal important roles in mouse development and adult homeostasis. Eur. J. Biochem. 267: 6982-6988. Flickinger CJ (1977) The influence of projestin and androgen on the fine structure of the male reproductive tract of the rat. Epididymis and accessory glands. Anat. Rec. 187:431-439. Kiplesund Km, Halgunset J, Fjosne HE and Sunde A (1988) Light microscope morphometric analysis of castration effects in the different lobes of the rat prostate. Prostate. 13(3): 221-232. Lee C, Goolsby CL and Sensibar JA (1994) Cell cycle kinetics in rat prostatic epithelia: nuclear migration during G2 phase. J. Urol. 152: 2294-2299. Luke CM and Coffey DS (1994) The male accessory tissues: Structure, androgen action and physiology. In the Physiology of Reproduction. Pp 1435-87. Edited by E.Knobil and J.D.Neill. Raven Press, New york, USA Nemeth JA, Zelner DJ, Lang S and Lee C (1998) Keratinocyte growth factor in the rat ventral prostate: androgen-independent expression. J. Endocrinol. 156: 115-125. Nishino T, Wedel T., Schmitt O., Buhlmeyer K., Schonfelder M., Hirtreiter C., Thors (2004) Androgen dependent morphology of prostate and seminal vesicle in the Hershberger Assay: Evaluation of immunohistochemical and morphometric parameters. Annals of Anato. Anzeiger 189:247-253. Robaire B., Hermo L. (1988) Efferent ducts, epididymis and vas deferens : structure, functions and their regulation. In the Physiology of Reproduction. pp. 999-1080. Edited by E. Knobil and J.D. Neill. Raven Press Ltd., New York. Sastry MS and Gupta SS (2008) Depression of plasma testosterone with Depot Medroxy Progesterone Acetate (Depo Provera). The Bioscan 3(2): 193-200. Sastry MS and Kashmiri ZN (2011) Toxic study of an oncolytic Drug Cyclophosphamide on the Accessory Reproductive Glands of Male Squirrel Funambulus pennanti (Wroughton): Histological Approach. Asian. J.Exp.Biol. Sci. 2(1): 119-126. Spring-Mills E, Krall A and Apellaniz M (1982) Effect of Bromocriptine and Perphenazine on male accessory sex glands. 11. Ultra structure of the seminal vesicle. Arch. Androl. 9:203-213. Stiens R, Helpap B (1981) Regressive changes in the rat prostate after castration. A study using histology, morphometrics and autoradiography with special reference to apoptosis. Pathol. Res. Pract. 172(1-2): 73-87. Reddi AH and Prasad MRN (1968) The reproductive cycle of the main Indian palm squirrel, Funambulus pennanti (Wroughton). J. Reprod. Fertil. 17(2): 235-237.