Research Paper

Volume : 3 | Issue : 8 | Aug 2014 • ISSN No 2277 - 8179

Effect of Heat Stress on Internal Organs of Four Chicken Varieties

Veterinary Science

KEYWORDS : Heat stress, Histology, broiler, crossbred, aseel

***R. Anju Rajan**	Teaching assistant, College of Veterinary and Animal Sciences, Mannuthy, Kerala, India *Corresponding author
S.C. Edwin	Professor and Head, Department of Livestock production and management, Veterinary College and Research Institute, Tirunelveli, India
K. Rajendran	Assistant Professor, Department of Poultry Sciences, Veterinary College and Research Institute, Namakkal, India
N. Murali	Professor and Head, Mecheri sheep research station, Pottaneri, Salem, Tamil Nadu, India
R. Kumar Pramod	Research Associate, Indian Veterinary Research Institute, Izatnagar, Bareilly, U.P., India

ABSTRACT

Heat stress is one of the most important issues affecting poultry production in tropical countries like India. The production performances and biochemical parameters of chicken were severely affected by elevated temperature. The objective of present study was to assess the effect of high environmental temperature on histology of some of the internal organs of four chicken varieties. The experimental birds were subjected to increased heat treatment i.e., 450 C daily, 2 hours for two weeks period (fifth and sixth week) using artificial heating systems. After the heat treatment, organs were collected and histology of these organs was studied. The results of the study demonstrated that high temperature caused pathological lesions in the liver and bursa of Fabricius of broiler, crossbred and assel except the crossbred birds. However, there was no significant changes were observed in other experimental organs.

INTRODUCTION

Poultry is one of the fastest growing segments of the agricultural sector in India. High ambient temperature and humidity are the major stress factors affecting poultry during summer in tropical countries like India. The high temperature results in heat stress and the severity dependent on the strain, feathering, and nutrition and production system. During summer, weight gain, feed conversion ratio (FCR), egg production, eggshell quality and hatchability are all adversely affected and mortality is high (Mashaly et al., 2004; Sohail et al., 2012). Absences of heat dissipating mechanism i.e. sweat glands and high body temperature (41°C) markedly increases bird's susceptibility to heat stress. Management techniques like improving house insulation, adequate ventilation, and installation of roof sprinklers and evaporative cooling systems are developed to make birds more comfortable in elevated temperature conditions. However, most of these techniques are rather complex to implement and are difficult to synchronize with the initiation of heat stress. Several reports are available about the production performances and biochemical parameters of chicken under elevated temperature. However, studies are limited about the effect of high temperature on the histology of this species. Therefore, objective of the present study was to investigate the effect of high environmental temperature on histology of some of the internal organs of four chicken verities.

MATERIALS AND METHODS

Experimental birds

The experiment was carried at the institutional poultry farm, Veterinary College and Research Institute, Namakkal, India. The average minimum-maximum temperature of this area was varied from 16-24^{0}C and 30-35^{0}C, and the average minimum-maximum relative humidity is in the range of 25-53% and 62-83%. Four different chicken varieties viz., commercial broiler (Cobb 400), commercial layer (Hy-Line), Namakkal Chicken-1 (cross bred) and Aseel (pure indigenous breed) were included in this study. Hatching eggs were purchased from different commercial farms and were incubated together as per the standard procedure in order to give same environmental condition even during embryonic stage itself. The study was conducted from day old to 6 weeks of age. Eighty birds from each variety were randomly selected for study purpose. All the experimental birds were reared under same environmental conditions up to fourth week of age. After four weeks, 50% of the birds were exposed to heat stress. Briefly, birds were subjected to increased heat treatment i.e., 45^{0} C daily, 2 hours for two weeks period (fifth and sixth week) using artificial heating systems.

Histopathological analysis

At the end of the experiment (after 6 weeks), one male and one female, totally eight birds from each variety were randomly selected and subjected to slaughter. Liver, brain, bursa of Fabricius, thymus and spleen were collected for histological examination. A small sample from each organ was fixed in 10% buffered neutral formalin, dehydrated in ascending ethanol series, embedded in paraffin and sectioned at 5 µm using standard procedures. The sections were dewaxed, rehydrated and stained with haematoxylin and eosin stain. After staining, slides were mounted with coverslips and observed under 10x objective of a phase contrast microscope (Leica, Switzerland).

RESULTS DISCUSSION

Major histological changes were observed in bursa of Fabricius of broilers at elevated temperature (Fig. 1). Bursa showed the presence of intra follicular and intra epithelial cysts. The presence of shrunken follicles was also detected in the bursa due to proliferation of the surrounding fibrous tissue. Liver of heat stressed broiler exhibited severe congestion and the brain showed a mild congestion. In heat treated layer birds, bursa showed the presence of intraepithelial cyst with sloughed epithelium and mild congestion with perivascular aggregation of mononuclear cells was detected in liver. In aseel birds, due to high temperature, the histology of liver showed moderate hyperplasia of epithelium lining the bile duct with periductular aggregation of mononuclear cells. Liver also had moderate periductular infiltration and perivascular aggregation of mononuclear cells. However, in crossbred variety, after heat treatment, the organs were maintained normal

histological architecture. Spleen and thymus did not show any pathological changes in all the varieties. The study demonstrated normal histology in all the birds under normal ambient temperature.

Earlier, researchers reported thyroid size in chickens varies considerably with season, environmental temperature, diet, age and functional state (Sturkie, 1954). Recently, Tarek et al (2013) observed a decreased weight of bursa of Fabricius in heat stressed broilers. They also observed the same pathological lesions as reported by our study. Aengwanich and Simaraks (2004) demonstrated different abnormal changes in kidney, heart, lung and liver of broilers due to high temperature.

In conclusion, we demonstrated the high temperature causes pathological lesions in the liver and bursa of Fabricius of broiler, crossbred and assel except the crossbred. However, there was no significant changes were observed in other experimental organs.

Figure 1: Histopathology of different chicken varieties under elevated temperature. (a) bursa of broiler showing intra follicular cysts; (b) bursa of layer contained small ruptured intra epithelial cyst with sloughed epithelium; (c) broiler brain showing mild congestion; (d) broiler liver with severe congestion; (e) mild congestion and perivascular aggregation of mononuclear cells in liver of layer; (f) liver showing moderate hyperplasia of epithelium lining the bile duct with perivascular aggregation of mononuclear cells in aseel. (H and E, 10X).

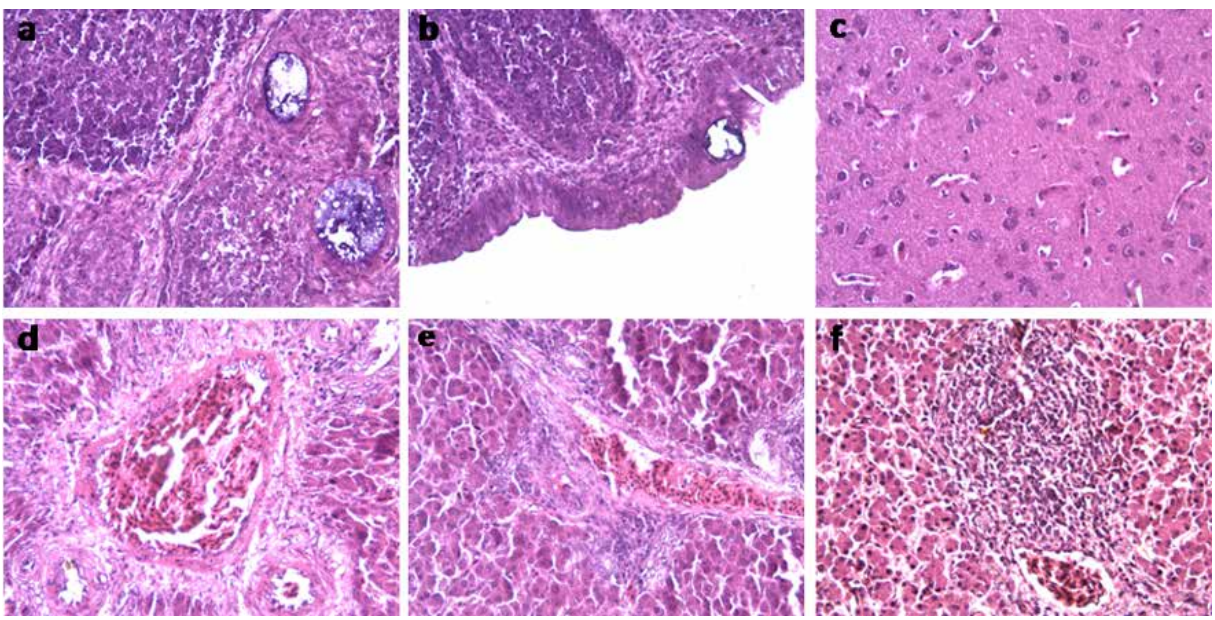

REFERENCE

1. Aengwanich, W. and S. Simarks. 2004. Pathology of heart, lung, liver and kidney in broilers under chronic heat stress. Songklanakarin. J. Sci. Technol. 26:417-424. | 2. Mashaly, M.M., G.L. Hendricks, M.A. Kalama, A.E. Gehad, A.O. Abbas and P.H. Patterson. 2004. Effect of heat stress on production parameters and immune responses of commercial laying hens. Poult. Sci. 83:889–894. | 3. Sohail, M.U., M.E. Hume, J.A. Byrd, D.J. Nisbet, A. Ijaz, A. Sohail, M.Z. Shabbir, H. Rehman. 2012. Effect of supplementation of prebiotic mannan-oligosaccharides and probiotic mixture on growth performance of broilers subjected to chronic heat stress. Poult. Sci. 91:2235–2240. | 4. Sturkie, P.D. 1954. Avian physiology, Comstock Published associated, Ithaca, New York. 423 pp. | 5. Tarek, K. M. Mohamed, B. Hassina and I. Messaouda. 2013. Histological study of the Bursa of Fabricius of Broiler chickens during heat stress. Intl. J. Poult. Sci. 12: 377-378. |