ORIGINAL RESEARCH PAPER

Volume-7 | Issue-4 | April-2018 | PRINT ISSN No 2277 - 8179

INTERNATIONAL JOURNAL OF SCIENTIFIC RESEARCH

# EFFICACY AND SAFETY OF RADIO FREQUENCY ABLATION (RFA) IN TREATMENT OF LIVER TUMOURS: A STUDY OF 52 PATIENTS

Radiology

**Dr Ajay R. Upadhyay** Associate Professor in Radiodiagnosis, Gcs Medical College Hospital & Research Center, Ahmedabad- 380025

**Dr. Digishkumar Umedsinh Vaghela*** Associate Professor in Radiodiagnosis, B.j.medical College, Ahmedabad- 380016 *Corresponding Author

**Dr Nikunj C. Desai** Assistant Professor in Radiodiagnosis, Gcs Medical College Hospital & Research Center, Ahmedabad- 380025

## ABSTRACT

**Aim:** The Aim of study is to prove efficacy of Radiofrequency ablation (RFA) in primary and metastatic liver tumours and treatment planning with coordination of surgeon, oncologist and interventional radiologist.

**Methods:** Fifty two patients were referred for percutaneous image guided RFA to treat unresectable hepatic malignancies. Thirty eight hepatomas and 14 liver metastasis were treated. Patient selection, treatment approach, local recurrence rates following RFA are described.

**Results:** Post-RFA follow-up was done up to 12 months. The morbidity and mortality rates associated with hepatic RFA were low. Local recurrence rates are low in tumour size less than three cm.

**Conclusions:** RFA of hepatic malignancies is a safe and promising technique alternate to surgery and chemo-therapy to produce coagulative necrosis of unresectable hepatic malignancies primary as well as metastatic tumours. This will be of great help to patients who are not fit for surgery and recurrent metastatic tumours not responding to surgery and chemo-therapy.

## KEYWORDS

Coagulation necrosis, Liver cancer, Radiofrequency ablation, Thermal ablation

## INTRODUCTION

Radiofrequency ablation (RFA) is used for treatment of malignant hepatic tumours. It destroys tumour cells by coagulation necrosis. From electrical energy, heat is generated at a specific target. Percutaneous RFA is least invasive. RFA is useful especially for small hepatic primary and secondary tumours when surgery is not feasible. RFA can be combined with radiation therapy, systemic chemotherapy or TACE (transarterial chemoembolization) for multiple or advanced lesions.

### Material and method

Fifty two patients were referred for RFA; 38 having Hepatocellular carcinoma (HCC) and 14 having liver metastasis. Out of later 14, nine were of colorectal metastasis and five were of breast malignancy. The patients selected for RFA did not show extra hepatic spread or portal vein thrombosis. Pre op minor with PT, INR (<1.3), pre-anesthetic checkup and chest x-ray were done. Informed written consent was taken in all. There were 13 patients of 45-55 year age group, 16 patients of 55-65 year age group and 23 patients of 65-75 year age group. The patients themselves and their relatives were explained procedure and prognosis including post procedure complications like bleeding, haemo-peritoneum, liver injury, liver failure and seedling. The requirements for radiofrequency ablation (RFA) procedure are combination of high end ultrasonography, computed tomography (CT), with spinal tray and standby anaesthestic. RFA equipment includes needle electrodes, electrical generator and grounding pads.

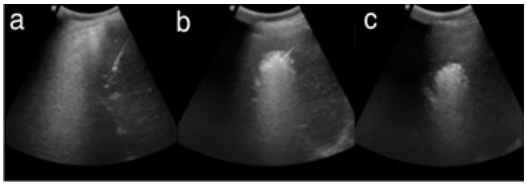


**Figure No. 1: USG-guided RFA of a hepatic tumour (a) electrode localization (b) process of RF ablation (c) immediate post-ablation.**

Procedures were performed by admitting patient on previous day of RFA. All patients were given sedation /short GA. Standard guidelines to prevent operative procedures were followed. The selected local site was infiltrated with local anesthesia and then stab incision was done with surgical blade. The umbrella type RF electrode was inserted into liver under real time ultrasound guidance [figure 1]. After needle tip confirmed into tumour center, prongs were expanded accordingly size of lesion and tip of all prongs confirmed with CT scan [figure 2].

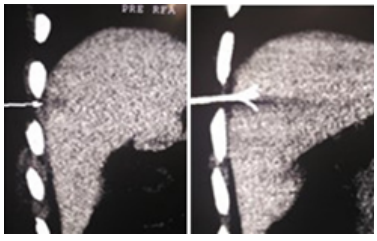


**Figure No. 2: Colo-rectal metastasis (arrow in pre-RFA image); CT image confirming prongs positioning for RFA.**

Ablation was performed for a total of 8-15 min at a targeted temperature of 105 degrees Celsius. In all metastatic lesions peripheral one cm of normal healthy tissue was ablated to prevent recurrence. Post procedure track ablation was done to prevent seedling. Post procedural CECT was performed for any residual non ablated area.

Follow-up CT scan after a month and thee month and also comparison was done with serum alpha fetoprotein in case of HCC and CEA in case of metastatic lesion to calculate success of RFA of above lesion.

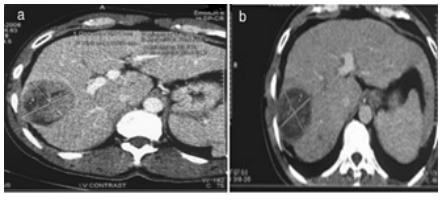


**Figure No. 3: (a) Pre-RFA and (b) one month post RFA follow-up of hepatocellular carcinoma of right lobe of liver in 56 year old male patient.**

### Results:

Procedures were regarded as technically successful if the tip of the RF electrode could be placed within the center of the nidus and prongs cover almost complete lesion and to be heated to the desired temperature. We defined a good response (clinical success) as the complete necrosis and decreasing size of lesion in subsequent follow-up study. We also defined a recurrence as the residual occurrence which shows residual enhancing area in follow-up CECT scan and non-responding tumor which does not alter after RFA and highly aggressive which shows newer nodules in subsequent CT scan.

**Table No. 1: Location of lesions in liver**

| Hepatic Segment | Number of Patients |
|---|---|
| IV | 12 |
| V | 05 |
| VI | 03 |
| VII and VIII | 32 |
| Total | 52 |

The RFA was technically successful in all cases, and there were no procedural or post procedural major or minor complications except pain at local site for few hours. The duration of follow-up ranged from 2-12 months [figure 3]. Only nine patients out of 23 developed recurrence at margin of nodule; 61 % success rate. Five patients out of ten patients with lesion size between three to five cm, developed residual/recurrence at periphery of lesion; 50% success rate. Out of five patients with lesion size above five cm, three patients got recurrence and increase in size of lesion in subsequent follow-up; 40% success rate. Three patients shows ascites and liver failure in subsequent examination.

Out of nine patients having colorectal metastasis, five patients were followed up for 12 months and disease was stable; 55.5% success rate. Two patients of metastatic breast cancer were stable for 12 months but developed multiple liver and lung metastasis later; 40% success rate.

**Discussion:**

Primary hepatoma less than five cm, patient unfit for surgery, inoperable primary liver tumour, debulking for liver tumours, recurrent lesions after surgery, patient waiting for liver transplantation are indications for RFA. Bile duct or major vessel invasion, significant extrahepatic disease, Child class C cirrhosis or active infection, more than three nodules, patients having pacemaker are contraindications. Lesions larger than five cm is a relative contraindication. In our series chief indication for RFA in HCCs was underlying cirrhosis. Five operated patients of colorectal cancer were referred for RFA of segment VII and VIII hepatic lesion. Four secondary liver deposits from colorectal malignancy were referred for RFA due to age and comorbidity of anaesthesia. The operated and post-chemotherapy patients of breast malignancy were referred for RFA of newly developed hepatic lesion.

Ultrasound guidance is used to so due care taken of diaphragm, lung and other vital structures like bowel, gall bladder, portal vein. Here real time capability and no radiation hazard related to USG are helpful. Ultrasonography is typically used to monitor the treatment by RFA which shows area of increased echogenicity at the site of RFA. This increase in echogenicity corresponds to the formation of tissue and water vapor bubbles from the treated tissue and is used as a rough estimate of the size of the ablation site. The size of the ablated area is determined largely by the size of the electrode needle, the temperature of the tissue, and the duration of time the energy is applied. A sharp boundary separates dead tissue and unaffected surrounding tissue.

CT scan is used for purpose of exact localization of prongs of RF electrodes in relation to tumour and in postprocedure follow-up. A hypervascular area around the ablation, which represents increased arterial perfusion and possible inflammatory reaction after RFA, is the most common finding in the immediate postablation period [10]. The postablation area is generally larger than the actual tumor size, for obvious reasons. An ablation area that is smaller than the tumor should be closely followed[11]. The ablated area gradually decreases in size but may also remain stable over the course of time.

Many studies have confirmed that RFA is a relatively low-risk procedure with low morbidity and mortality[7]. Few complications are associated with RFA [8]. Factors related to major complications include tumour size, number of ablation sessions, electrode type (single or cluster), and operator experience. One large study showed that an increased number of RF sessions was related to a higher rate of major complications with no significant relation to tumour size or electrode type [9]. Patients can experience discomfort immediately after the procedure; this normally settles with simple analgesia. The patient may also experience delayed pain as a part of postablation syndrome. The symptoms of postablation syndrome are low-grade fever, delayed pain, malaise, myalgia, nausea, and vomiting. Patients should be informed about post-ablation syndrome and its self-limiting nature before the procedure. Most patients should be able to resume normal activity in 7-10 days. Possible rare complications include shoulder pain, damage to the bile ducts/ bowel, capsular hematoma, hemoperitoneum, pneumothorax, pleural effusion, infection and portal thrombosis and needle tract seeding.

When compared with surgical resection, recurrence rate is higher after RFA, with less time to recurrence [1]. The rate of recurrence is also more with lesions larger than three cm [2]. In a study by Toshimori et al, the local recurrence rates after percutaneous RFA for HCC were 2.2% at 1 year [3]. Factors that predisposed to local recurrence included large tumour size, tumour location adjacent to the major portal branch or hepatic vein and a small ablated margin. Shady et al assessed factors affecting outcome in patients with colorectal cancer liver metastases who were treated with percutaneous RFA[4]. On multivariate analysis, factors predictive of shorter local tumor progression-free survival were a tumor size exceeding 3 cm and a margin size of 5 mm or less; factors predictive of shorter overall survival were a tumour size exceeding 3 cm and the presence of more than one site of extra-hepatic disease. Multiple electrodes seem to be superior to single electrodes with respect to the local recurrence rate for tumours between three and five cm [5].

**Conclusion**

Radiofrequency ablation (RFA) is an alternative therapy for hepatocellular carcinoma (HCC) and liver metastases when resection cannot be performed or in the case of transplant awaited patients. RFA has the advantage of being a relatively low-risk minimally invasive procedure for the treatment of focal liver tumours.

**References**


1. Sutherland LM, Williams JA, Padbury RT, Gotley DC, Stokes B, Maddern GJ. Radiofrequency ablation of liver tumours: a systematic review. Arch Surg. 2006 Feb; 141(2):181-90.
2. Penka I, Kaplan Z, Sefr R, Sirotek L, Eber Z, Ondrak M. Use of radiofrequency ablation in the treatment of malignant liver lesions. Hepatogastroenterology. 2008 Mar-Apr; 55(82-83):562-7.
3. Toshimori J, Nouso K, Nakamura S, Wada N, Morimoto Y, Takeuchi Y, et al. Local Recurrence and Complications after Percutaneous Radiofrequency Ablation of Hepatocellular Carcinoma: A Retrospective Cohort Study Focused on Tumour Location. Acta Med Okayama. 2015 Aug; 69 (4):219-26.
4. Shady W, Petre EN, Gonen M, Erinjeri JP, Brown KT, Covey AM, et al. Percutaneous Radiofrequency Ablation of Colorectal Cancer Liver Metastases: Factors Affecting Outcomes-A 10-year Experience at a Single Center. Radiology. 2015 Aug; 12. 142489.
5. Mulier S, Ni Y, Miao Y, et al. Size and geometry of hepatic radiofrequency lesions. Eur J Surg Oncol. 2003 Dec; 29(10):867-78.
6. Hansler J, Frieser M, Tietz V, et al. Percutaneous ultrasound-guided radiofrequency ablation (RFA) using saline-perfused (wet) needle electrodes for the treatment of hepatocellular carcinoma--long term experience. Ultraschall Med. 2007 Dec; 28(6):604-11.
7. Curley SA. Radiofrequency ablation of malignant liver tumours. Ann Surg Oncol. 2003 May; 10(4):338-47.
8. Radiofrequency ablation. Oncology Net Guide. Available at http://www.oncologynetguide.com/oncology/about.html. Accessed: August 25, 2008.
9. Livraghi T, Solbiati L, Meloni MF, Gazelle GS, Halpern EF, Goldberg SN. Treatment of focal liver tumors with percutaneous radio-frequency ablation: complications encountered in a multicenter study. Radiology. 2003; 226:441–451.