Research Paper

Volume : 5 | Issue : 5 | May 2016 • ISSN No 2277 - 8179 | IF : 3.508 | IC Value : 69.48

Efficacy of Thionin Blue Staining of Apoptotic Nuclei

Medical Science

KEYWORDS : Apoptosis, Thionin, Endometrium, Hyperplasia.

Dr.K. Rekha

Associate Professor, Department of Pathology, Dr ALM PG IBMS, Taramani, University of Madras, Chennai

ABSTRACT

The falling out form of cell death or programmed suicidal phenomenon is an inevitable stage of cell kinetics – apoptosis.

The histological evaluation of apoptosis enables better understanding of the morphological picture of hyperplastic and preneoplastic conditions. Apoptosis indicates a benign and self-limiting status enabling management.

Though advances in technology have reached molecular detection of apoptotic cells, histomorphological evaluation would still be the gold standard method to analyse the cell turn over. The present study is aimed to compare the efficacy of identification of Apoptotic and mitotic cells by Haematoxylin and Eosin and Thionin Blue staining in endometrial tissue of various types. Thionin Blue stain proves to be a simple, easily performable and interpretable in the detection of Apoptotic cells.

Thionine blue is one of the commonly used nuclear stain for conventional light microscopic examination of sections of formaldehyde fixed, paraffin embedded tissue. It gives a blue stain to all nuclei and has a good contrast.

Introduction

Apoptosis, the physiological form of cell death that regulates the cell turnover is essential to sustain homeostasis in tissues. Detection of apoptosis has gained significance in the normal, pre neoplastic & neoplastic tissue.

Though advances in technology have reached molecular detection of apoptotic cells, histomorphological evaluation would still be the gold standard method to analyse the cell turn over.

The present study is aimed to compare the efficacy of identification of Apoptotic and mitotic cells by Haematoxylin and Eosin and Thionin Blue staining in endometrial tissue.

Materials and methods

A random sampling of various endometria from women presenting with history of irregular uterine bleeding were included. The samples were fixed in 10% buffered formalin, subjected to routine paraffin processing and sectioning. The sections stained with the routine H & E and Thionine blue stain.

Thionin Stain - Thionin C - C12H10ClN3S

This stain is specific for DNA and Nissl substance, which is primarily in the ribosomal RNA. Thionin binds to acidic proteins and nucleic acids with a specificity determined by the pH of the final staining solution.

Thionin Blue Staining

Stock Solutions:

Stock 1% Thionin (Sigma T3387.)
Dissolve 1 gm Thionin in 1000 ml distilled water.
Stir and heat gently for 1 hour.
Filter the solution after the dye has dissolved. Store in a glass stoppered bottle.

Working Solution:

Full strength thionin stain (1%) of pH 4.0

Working solutions of Thionin should be filtered periodically and replenished by adding freshly filtered thionin working solution to replace about 10% of the solution in the staining dish.

Fig 1 Hematoxylin Eosin

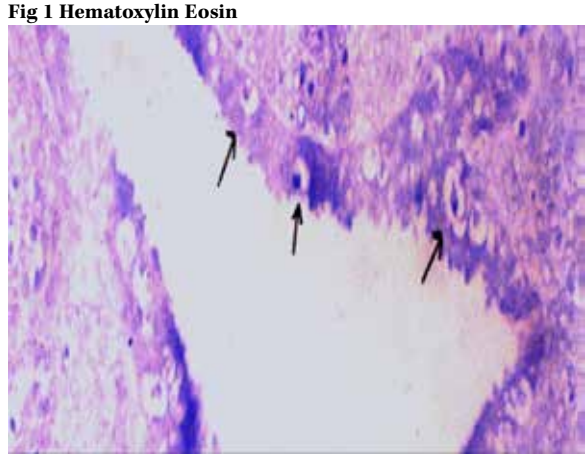

Fig 2 Thionin Blue

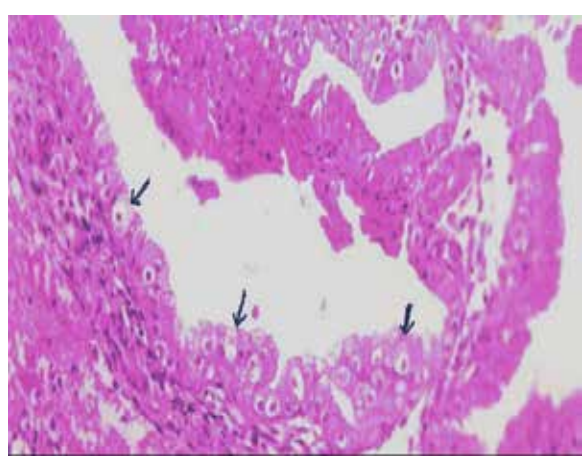

Apoptotic & Mitotic Indexing

The Apoptotic index was calculated in both the thionin blue and hematoxylin and eosin stained sections, by counting the number of apoptotic cells or bodies per 1000 cells in 10 consecutive high power fields of every section in each case.

Similarly the Mitotic index was calculated by counting the number of mitotic figures per 1000 cells in 10 consecutive high power fields.[Graph 1 and Graph 2]

Apoptotic and Mitotic Indices:
Graph 1 Thionin Blue

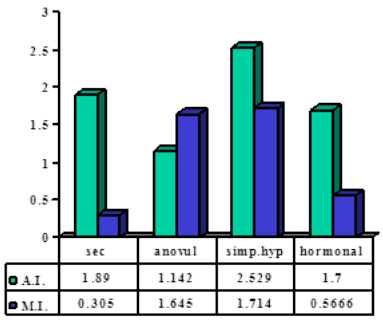

Graph 1I Hematoxylin Eosin

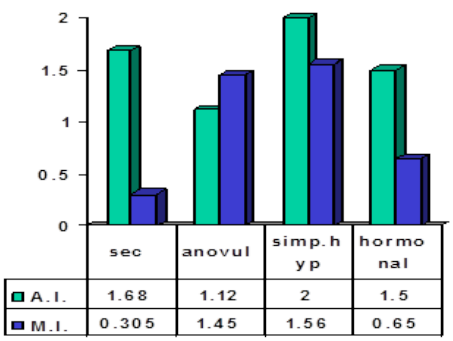

Discussion

Detection and quantification of apoptotic cells enables to assess the activity of the tissue. The need to observe the nuclear features in highly cellular tissues, calls for a stain that would be pleasant to the observer's eye, easy to perform and interpret. This simple, fast and reproducible nuclear stain 'Thionin blue' fulfills the criteria.

The stain can be used for other tissues for similar studies of cell turn over and has the definite advantage of an accurate evaluation in comparison to the other more cumbersome techniques.

References

1. Arends MJ. 1999. Apoptosis in the endometrium. Histopathology
2. Cotran R,Kumar, Collins T.Robbins Pathologic basis of Disease sixth edition W B Saunders &Co.2000.Cell Cycle, Mechanism of Apoptosis in Normal endometrium.Pg1054-1055, 18-25,91-96.