ORIGINAL RESEARCH PAPER

Volume-8 | Issue-1 | January-2019 | PRINT ISSN No 2277 - 8179

INTERNATIONAL JOURNAL OF SCIENTIFIC RESEARCH

# EMPYEMA NECESSITANS: A NOTEWORTHY PRESENTATION OF EMPYEMA- CASE REPORT

**Radiodiagnosis**

**Dr. M. Ajit Chakravarthy** — Resident Department of Radiodiagnosis, Jnmc, Sawangi (Meghe),Wardha

**Dr. Suresh. V. Phatak*** — Professor and HOD, Department of Radiodiagnosis, Jnmc, Sawangi (Meghe), Wardha
*Corresponding Author

## ABSTRACT

***Background:*** Empyema necessitans is an atypical long-term complication of empyema distinguished by the leakage of pus from the pleural space into the proximate chest wall and soft tissues setting up a connection between the pleural infection, and the subcutaneous tissue. We review a case of a 25 year old female presenting with increasing mass on the left side of her back since 1 month. A swelling is noted in the right paraspinal region in the intramuscular plane. Radiological procedures including USG, NECT showed empyema necessitans.
***Conclusion:*** Empyema necessitans is mainly caused by Mycobacterium tuberculosis and Actinomyces israelii.

## KEYWORDS

Empyema, USG, NECT.

## INTRODUCTION:

Collection of pus in the pleural space is called Empyema. Empyema necessitans is an atypical long-term complication of under treated or uncontrolled empyema thoracis distinguished by the dissection of pus from the pleural space into the proximate chest wall and soft tissues setting up a connection between the pleural infection, and the subcutaneous tissue. *Empyema necessitans* is a rare clinical finding nowadays. Mycobacterium tuberculosis and Actinomyces Israelii are common causes but Gram negative bacilli could be a rare cause. The most common non-tubercular etiological agent is Staphylococcus. Other pathogens include Pneumococci, Escherichia coli, Pseudomonas, Klebsiella, and anaerobes(1). We report the case of a young female patient admitted for investigation of an unknown onset posterior chest wall mass, with no accompanying signs or symptoms. Modalities like ultrasound, CT helps in localization and better assessment of the extent and severity.

## CASE REPORT:

A 25 year old female presented with increasing mass on the left side of her back since 1 month with no associated signs and symptoms. She had a history of tuberculosis 1 year and she took anti-tuberculosis medication for 8 months. There were no other systemic symptoms and she is not a known case of any other illness.

On local examination there was a swelling of size 4 x 4 cms in the right paraspinal region. The swelling is soft in consistency , non-fluctuant and immobile. There is absent tenderness and is painless and no local rise of the temperature(Figure 1).

Ultrasonography of the swelling revealed a large fluid collection with internal debris in the right paraspinal region in the intramuscular plane(Figure 2). Provisional diagnosis of cold abscess was made.

Later CT scan showed loculated pleural collection which is noted along the postero -basal segment of the right lower lobe associated with pleural thickening. This collection is seen communicating with the extra thoracic space through a defect in the parietal pleura and inter -coastal muscle(Figure 3A,3B,3C). The collection is seen in the thoracic soft tissue wall along right posterior wall. It measures 10 x 10 x 3 cms (CC x TR X AP).

## DISCUSSION:

Empyema necessitans complicating pleural effusion is rare in our environment. Both immunocompetent and immunocompromised individuals can develop this condition but commonly occurs in immunocompromised individuals. An extension into anterior chest wall between the anterior axillary midclavicular and lines is the commonest location of an extension. the abdominal wall, vertebrae, paravertebral space, esophagus, bronchus, mediastinum, diaphragm, pericardium, flank, breast, and retroperitoneum are other reported locations of extensions (2). inadequately treated empyema can lead to the development of this condition. It presents in patients with underlying pulmonary disease and a swelling over the hemithorax. Pleural cavity decontamination, limiting the infection and draining the fluid are the goals of treatment in this condition which allow the expansion of lung and reinstate its normal function (3).

The extra thoracic collection seen in empyema necessitans can be attributed to thoracoplasty as it causes fragility in the chest wall, promoting a disruption of empyema through neighbouring tissues(4). Treatment of this condition can either be surgical or medical.

Ultrasonography and radiography can provide assistance in diagnosing empyema necessitatis. Appearance of a fluctuant lump together with sonographic and radiographic evidence of empyema can help in assisting the diagnosis of empyema necessitates(5).

HRCT thorax is of vital importance in the diagnosis of empyema necessitans. On CT thorax it is seen as an extra-thoracic mass seen connecting with the pleural effusion. Other CT scan findings include: ribs damage, pleural thickening, and its calcification. Rib thickening is observed routinely. Tracheobronchial fistula is observed many times which can be hardly diagnosed on CT scan(6). CT scan also can provide particulars about functioning parenchyma of lung.

The CECT scan is the investigation of choice with mediastinal and lung windows which shows the nature and extent of the disease like demonstrating an extension of empyema into the subcutaneous tissue. This condition can be prevented by early diagnosis and treatment of empyema(1). Appearance of 'split pleura sign' on CT scan helps in differentiating empyema from lung abscess. Thoracic empyema can also extend through intercostal space into subcutaneous tissues and also into the upper abdomen involving the liver confirming empyema necessitans(7). For successful treatment of this condition proper surgical drainage and antimicrobial therapy are of significant importance(3).

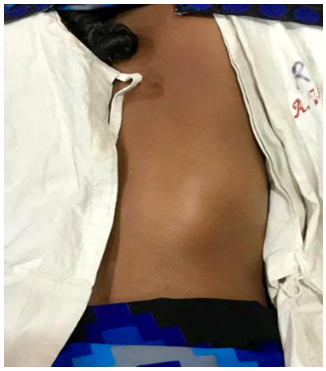

**Figure 1: An elliptical swelling of size 4 x 4 cms seen in the right paraspinal region.**




**Figure 2: USG image revealing fluid collection with internal debris in the intramuscular plane in the right paraspinal region.**

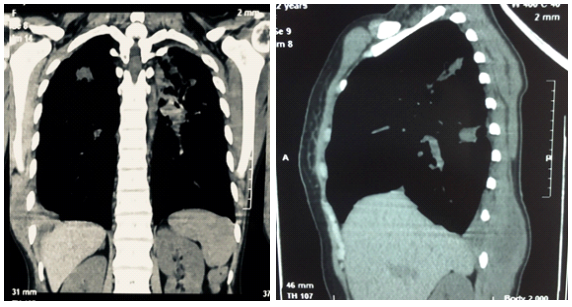


**A)** **B)**

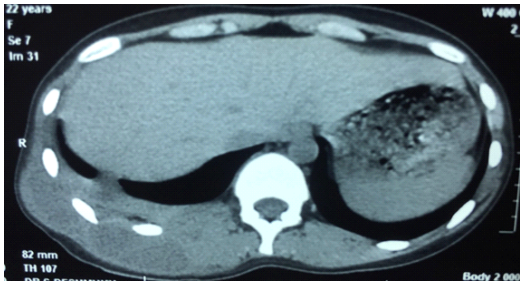


**C)**

**Figure 3: A) Coronal B) Saggital C) Axial NECT sections showing pleural thickening and collection seen in thoracic soft tissue along the right posterior wall.**

## CONCLUSION:

Empyema necessitans is an empyema that extends to extrapleural spaces. Mycobacterium tuberculosis is the commonest cause of empyema necessitans. Our case here indicates an infrequent complication of pleural space infections. CT scan is the imaging modality of choice and has the highest accuracy in diagnosis.

## REFERENCES

1) Yauba MS, Ahmed H, Imoudu IA, Yusuf MO, Makarfi HU. Empyema necessitans complicating pleural effusion associated with proteus species infection: a diagnostic dilemma. Case reports in pediatrics. 2015; Article ID 108174:1-4.
2) Mizell KN, Patterson KV, Carter JE. Empyema necessitatis due to methicillin-resistant Staphylococcus aureus: case report and review of the literature. Journal of clinical microbiology.2008 Oct 1;46(10):3534-6.
3) Bhanja S, Guha A, Samanta A, Mia HA, Kumar N. A Case of Empyema necessitans: An uncommon presentation of Empyema. International Journal of Pediatrics. 2017;5(7):5351-5.
4) Gomes MM, Alves M, Correia JB, Santos L. Empyema necessitans: very late complication of pulmonary tuberculosis. BMJ case reports. 2013 Dec 10; bcr2013202072:1-4
5) Mirza B, Ijaz L, Sheikh A. A rare presentation of empyema necessitatis. Lung India: official organ of Indian Chest Society. 2011 Jan;28(1):73-4.
6) Babamahmoodi F, Davoodi L, Sheikholeslami R, Ahangarkani F. Tuberculous empyema necessitatis in a 40-year-old immunocompetent male. Case reports in infectious diseases. 2016; Article ID 4187108:1-4.
7) Gala F, Patil SH. Tuberculous Thoracic Empyema with Empyema Necessitans. URL: http://www.eurorad.org/case.id=13537