ORIGINAL RESEARCH PAPER

Volume-8 | Issue-4 | April-2019 | PRINT ISSN No 2277 - 8179

INTERNATIONAL JOURNAL OF SCIENTIFIC RESEARCH

EVALUATION OF BREAST MASSES WITH MAMMOGRAPHY AND SONO-MAMOGRAPHY WITH HISTOPATHOLOGY (FNAC/BIOPSY) CORRELATION.

Radiodiagnosis

Peeyush Kumar Dhagat — Col., Professor & Senior Advisor (Radiodiagnosis), Base Hospital Delhi Cantt, New Delhi 110010

Sumeet Arora* — Col., Associate Professor & Senior Advisor (Radiodiagnosis), Base Hospital Delhi Cantt, New Delhi 110010. *Corresponding Author

Major Narendra Yadav — Senior Resident, (Radiodiagnosis), Base Hospital Delhi Cantt, New Delhi 110010.

Surg Cdr Satyendra Narayan Singh — Associate Professor & Classified Specialist, Dept of Radiodiagnosis, Base Hospital Delhi Cantt, New Delhi 110010

ABSTRACT

Introduction: Breast cancer is the most commonly occurring female cancer in the world with an age-standardized incidence rate (ASR) of 39.0 per 100,000, which is more than twice that of the second ranked cancer (cervical cancer ASR=15.2 per 100,000). In India, carcinoma of breast is the second most common cancer (after cervical cancer) with an estimated 115,251 new diagnoses and the second most common cause of cancer-related deaths with 53,592 breast cancer deaths in 2011. In India, breast cancer accounts for 22.2% of all new cancer cases and 17.2% of all cancer deaths among women. Breast cancer in urban areas of India is three times higher than in rural regions of the country. In the past decades, great strides have been made in breast cancer screening 6 in the form of triple assessment. Given its inherent limitation and disadvantages, efforts have been made to develop several adjuvant-imaging techniques for breast cancer screening.

Aim and Objectives: To evaluate the validity and accuracy of mammography and sonomammography as a tool for categorizing breast masses.If the present study justifies, then USG and mammography of breast could be included in the standard screening of the breast lump, especially in suspected cases of breast cancer. This could avoid painful interventional procedures like FNAC and core biopsy.

Material and Methods: The present study was carried out at a tertiary care Hospital at New Delhi. Females more than 30 years referred to us with complaints of breast masses for mammographic and sonomammographic examination were included in the study. Patients were selected based on the inclusion and exclusion criteria. Whole-breast sonography with high resolution, 7.5 – 12 MHz, linear array transducer of GE LOGIQ P5 were performed Mammography was performed with Siemens Mammomat Novation DR Equipment in two views (i.e., cranio-caudal & medio-lateral oblique views). Finally FNAC of the lesion for cystic lesion and the histo-pathological report assessment for rest of the lesion was done. Assesment was done using BI-RADS US Assessment Category.Results: Results were corroborated using statistical analysis

Conclusion: Our results indicate that breast density is important predictors of the accuracy of mammography. Breast ultrasound is more accurate than mammography in symptomatic. The accuracy of mammograms increased as women's breasts became fattier and less dense. In women with dense breasts, ultrasound appears superior to mammography, and may be an appropriate initial imaging test in those women. However, Sono mammographic correlation is best in both.

KEYWORDS

Abbreviations: Breast Conservation Surgery (BCS),BI-RADS,Breast Imaging and Reporting Database System (BI-RADS), Ductal Carcinoma In-Situ (DCIS), Fast Low Angle Shot (FLASH), Invasive Ductal Carcinoma (IDC), Ultrasonography (USG)

1. INTRODUCTION:

Breast cancer is the most commonly occurring female cancer in the world with an age-standardized incidence rate (ASR) of 39.0 per 100,000, which is more than twice that of the second ranked cancer (cervical cancer ASR=15.2 per 100,000).[1,2]

In India, carcinoma of breast is the second most common cancer (after cervical cancer) with an estimated 115,251 new diagnoses and the second most common cause of cancer-related deaths with 53,592 breast cancer deaths in 2011. Furthermore, the age-standardized incidence rate for breast cancer in India is 22.9 per 100,000, which is one-third that of Western countries and the mortality rates are disproportionately higher in India.[3,4,5]

In India, breast cancer accounts for 22.2% of all new cancer cases and 17.2% of all cancer deaths among women. Breast cancer in urban areas of India is three times higher than in rural regions of the country. These variations are considered to exist because more and more women in India are beginning to work outside their homes, which allow the various risk factors of breast cancer to come into play. These include late age at first childbirth, fewer children and shorter duration of breast-feeding and so on.

Despite of medical advances and assuring treatment regime, morbidity and mortality due to breast cancer has seen no significant changes in India. This may possibly be due to lack of systematic screening and early detection of the condition. Thus it is considered that early detection by imaging modality comes handy in determining the progression of the disease.

In the past decades, great strides have been made in breast cancer screening [6]. The combination of imaging, clinical examination and needle biopsy- known as triple assessment, is the considered standard for breast diagnosis [7,8]. Although various studies have shown the benefits of screening mammography, there are limitations on X-ray mammography that needs to be accounted to [9,10,11]. Given its inherent limitation and disadvantages, efforts have been made to develop several adjuvant-imaging techniques for breast cancer screening [12,13,14].

In the present study the sensitivity of the mammography and ultrasound of breast were compared. In this study, USG of breast was compared with the mammography in detecting the outcome of a breast lump. If the present study justifies, then USG and mammography of breast could be included in the standard screening of the breast lump, especially in suspected cases of breast cancer. This could avoid painful interventional procedures like FNAC and core biopsy.

2. AIM AND OBJECTIVES:

- To evaluate the validity and accuracy of mammography and sonomammography as a tool for categorizing breast masses.
- To characterize the breast masses into benign and malignant based on mammographic and sonomammographic findings.
- Compare the imaging findings of sonomammography and mammography and correlate with histopathology as gold standard.

3. MATERIAL AND METHODS:

The present study was carried out at a tertiary care Hospital at New Delhi, North India from June 2015 to June 2017. Females more than 30 years referred to us with complaints of breast masses for mammographic and

sonomammographic examination were included in the study. The present study was carried out as a prospective diagnostic study where validity and accuracy of mammography and USG in evaluating breast masses was assessed. Convenient sampling technique were used to select study participants from all the eligible patients who visit the department of Radio diagnosis and the minimum required sample size was calculated to be 102.Patients were selected based on the inclusion and exclusion criteria. Informed written consent was obtained from each patient under the study. Women above 30 years of age with breast mass who give consent to the imaging modalities were included in this study. Females with previously diagnosed case of breast carcinoma, fungating mass in breast and mass adherent to chest wall where performing mammography was difficult were excluded from this study. Females with post-traumatic and post inflammatory breast swellings were not also not included. The pregnant and lactating women were dropped from this study due to radiation exposure.

Whole-breast sonography with high resolution, 7.5 – 12 MHz, linear array transducer of GE LOGIQ P5 were performed with axial and sagittal scanning of both breasts.The USG findings were recorded on the performa which included Location (Side, Quadrant), Size, Shape (Round, Oval, Lobulated, Irregular), Margin (Smooth, Irregular, Spiculated and Angular), Pseudocapsule, Longitudinal axis versus Anterio posterior diameter, Posterior Echo Intensity (Post acoustic Enhancement and Shadowing), Echogenicity (Anechoic, Hypoechoic, Isoechoic and Hyperechoic), Internal Structure (Cystic, Complex, Homogenous and Heterogenous), Calcification, surrounding breast parenchyama, overlying skin, underlying muscle and chest wall, contralateral breast, bilateral axillary and supraclavicular regions for lymph nodes, Colour Doppler (Appearance of Blood Vessels and there Pattern of Distribution) & Spectral Waveform (Resistive index).

Mammography was performed with Siemens Mammomat Novation DR Equipment in two views (i.e., cranio-caudal & medio-lateral oblique views) and findings were recorded on the performa on almost similar lines as USG with additional comments on density.

Finally FNAC of the lesion for cystic lesion and the histo-pathological report assessment for rest of the lesion was done. Assesment was done using BI-RADS US Assessment Category.

BI-RADS US Category	Assessment and Management
0	Incomplete: additional imaging evaluation needed
1	Negative
2	Benign
3	Probably benign: short-interval follow-up recommended
4 4a 4b 4c	Suspicious: biopsy Low suspicion Intermediate suspicion Moderate suspicion
5	Highly suggestive of malignancy: biopsy
6	Known malignancy: treatment ongoing

Statistical Analysis:
Means and proportions were calculated for continuous variables and categorical variables respectively.Chi square test was used for finding statistically significant difference in proportions.Independent student t test was used for finding statically significant difference between means.The sensitivity, specificity, positive predictive value and negative predictive value of mammography, sonomammography and combined mammography and sonomammography were assessed.P value < 0.05 was considered to be statistically significant.Data entry was done using MS Excel 2013.IBM SPSS Version 22.0 was used for statistical analysis.

Ethical Considerations: Institute ethical committee clearance certificate was sought and obtained before the study was started.

Conflict of interest: Nil
Financial assistant : Nil

RESULTS:
:Majority of the patients with benign tumors were in the age group of 30-40 years, whereas patients with malignant tumors were in the age group of 30-50 years.

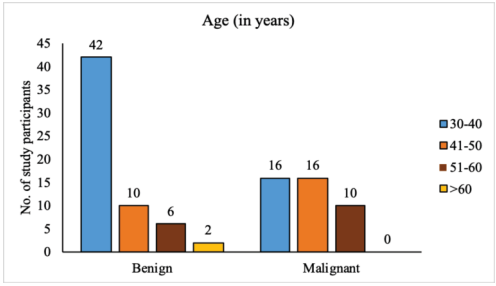

Table/Fig 1- Distribution of study participants with lesions based on age (n=102).

Table/Figure 2 of study participants based on mammographic tissue density			
Breast Parenchymal Density	**No. of palpable abnormalities**	**Lesions in US**	**Lesions in Mammography**
Scattered fibro glandular Density	34	B+M+PB+PM	B+M+PB+PM
Predominantly Fatty	24	M+B	M+B
Heterogenously Dense	16	B+M	I+B
Dense	28	B+PB	I+B
Result: Majority of the breast masses on evaluation were showing scattered fibro glandular density.			
B-Benign; PB- Probably Benign; M-Malignant; PM-Probably Malignant; I-Inconclusive.			

RESULT: Fibroadenomas were the most common etiology presenting as breast mass among our study participants (31.4%), followed by breast malignancies (25.5%).

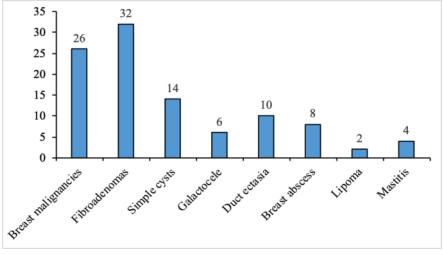

Table/Fig 3: Distribution of study participants based on breast pathologies:

Table/Fig 4: Distribution of study participants based on lesion type and finding in diagnostic modality			
Lesion	**HPR**	**Mammography**	**USG**
Benign	60	24(40%)	34(56%)
Malignant	42	30(71%)	26(61%)
Total	102	54	60

Table/Fig 5:Distribution of study participants based on suspicious lesion types and finding in diagnostic modality		
Suspicious lesion	**Mammography**	**USG**
Probably Benign	6	12
Probably Malignant	20	30
Inconclusive	22	0
Result: Mammography images of eleven patients were inconclusive of any diagnosis, images suggestive of probable malignancy was seen in ten patients. USG diagnosis of probable malignancy was observed in 30 patients.		

Table/Fig 6:Comparison of US classification with pathologic findings			
US	**Pathologic Findings**		**Total**
	Benign	**Malignant**	
Benign (B+PB)	46	0	46
Malignant (M+PM)	14	42	56
Total	60	42	102
Result: Breast lesions evaluated by ultrasonography for malignancy had a sensitivity of 76%, specificity of 100%, positive predictive value 100% and negative predictive value 75%.			
B-Benign; PB- Probably Benign; M-Malignant; PM-Probably Malignant			

Table/Fig 7:Comparison of Mammography classification with pathologic findings.

Mammography	Pathologic Findings		Total
	Benign	Malignant	
Benign (B+PB)	28	2	30
Malignant (M+PM)	16	34	50
Total	44	36	80
Result: Malignant breast lesions evaluated by Mammography had a sensitivity of 63%, specificity of 87%, positive predictive value 93% and negative predictive value 46%.			
B-Benign; PB- Probably Benign; M-Malignant; PM-Probably Malignant			

Table/Fig 8:Comparison of validity and reliability of US and Mammography

Parameter	USG	Mammography
Sensitivity	76%	63%
Specificity	100%	87%
Positive Predictive Value	100%	93%
Negative Predictive Value	75%	46%
Result: Our data indicate that sensitivity and specificity of ultrasound was greater than mammography in patients with breast symptoms for the detection of breast cancer and benign lesions particularly in dense breast women.		

DISCUSSION

Because of the low sensitivity of the mammography in younger women due to dense breast tissue and also low incidence of breast carcinoma in women less than 35years,[15] we have included in our study only women who are 35 and over 35 years of age with palpable abnormalities of breast. Breast carcinoma has been reported in only 4% of patients with breast symptoms, and even among palpable lesions undergoing biopsy, a large number of lesions turned out to be benign.[16,17.] The role of mammography in patients with palpable breast lumps is to show a benign cause for palpable abnormality and to avoid further intervention, to support earlier intervention for a mass with malignant features, screen the remainder of the ipsilateral and contralateral breast for additional lesions, and to assess the extent of malignancy when cancer is diagnosed.[18]

However the false negative rate of mammography for breast cancer in patients with palpable abnormalities of the breasts has been reported to be as high as 16.5%.[19] Multiple studies have shown that the false negative rate for a combined mammographic and sonographic evaluation varies from 0% to 2.6%.[20-21]Additional imaging with sonography is appropriate in most instances, with the exception of lesions that are mammographically benign as noted above or lesions that are highly indicative of malignancy, in which sonographic imaging would not add any additional information. Sonography may obviate the need for intervention by showing benign causes of palpable abnormalities such as cysts, benign intra mammary lymphnodes, extravasated silicon and superficial thrombophlebitis of Mondor disease of the breast.

In our study, 12 (40%) of the 51 lesions were categorized as benign in mammography and 17 (56%) in sonographic evaluation, clearly showing the value of imaging in helping avoid unnecessary biopsies. In these patients Sonography was able to categorise palpable lesions obscured by dense tissue on mammograms. Moss et al[22] reported that sonography increased cancer detection by 14% in symptomatic patients who were evaluated with both mammography and sonography. In retrospective analysis of 293 palpable malignant lesions, sonography detected all cancers; 18(6.1%) of these 293 cancers were mammographically occult.[23] In study of 411 palpable abnormalities by Georgian-Smith D [23], 66(16%) of the 165 palpable abnormalities were mammographically occult. In this study 11 of the 51 lesions were mammographically occult and were seen only on ultrasound. Of these 5 were fibroadenoma, 3 were benign cysts and 3 were duct ectasia. Sonography therefore is complimentary to mammography in patients with palpable abnormalities; its superiority over mammography is in being able to show lesions obscured by dense breast tissue and in characterizing palpable lesions that are mammographically visible or occult.

Mammography is complimentary to sonography because of its ability to screen the reminder of the ipsilateral and contra lateral breast for clinically occult lesions. It has been reported that the accuracy of sonography is comparable with that of mammography as a screening modality for breast cancer. However the role of sonographic screening for additional lesions in the symptomatic patients has not been reported.

Summary:

- The present study was carried out as a Diagnostic study where validity and accuracy of mammography and USG in evaluating breast masses was assessed among females more than 30 years of age.
- FNAC was considered the Gold Standard test for confirmation of diagnosis
- Majority of the patients with benign tumors were in the age group of 35-45 years.
- Fibroadenomas were the most common etiology presenting as breast mass among our study participants (31.4%), followed by breast malignancies (25.5%).
- Breast lesions evaluated by ultrasonography for malignancy had a sensitivity of 76%, specificity of 100%, positive predictive value 100% and negative predictive value 75%.
- Malignant breast lesions evaluated by Mammography had a sensitivity of 63%, specificity of 87%, positive predictive value 93% and negative predictive value 46%.

CONCLUSION:

Our results indicate that breast density is important predictors of the accuracy of mammography. Breast ultrasound is more accurate than mammography in symptomatic. The accuracy of mammograms increased as women's breasts became fattier and less dense. In women with dense breasts, ultrasound appears superior to mammography, and may be an appropriate initial imaging test in those women. However, Sono mammographic correlation is best in both.

REFERENCES:

1. Fearlay J, Bray F, Pisani P, Parkin D. Cancer incidence, mortality and prevalence worldwide. Version 1.0. IARC Cancer Base No. 5. IARC Press, Lyon; 2001.
2. GLOBOCAN 2008: Cancer Incidence and Mortality Worldwide. 2010. at https://www.iarc.fr/en/media-centre/iarcnews/2010/globocan2008.php.)
3. Agarwal G, Ramakant P. Breast cancer care in India: the current scenario and the challenges for the future. Breast care 2008;3:21-7.
4. Agarwal G, Ramakant P, Forgach ER, et al. Breast cancer care in developing countries. World J Surg 2009;33:2069-76.
5. Ali R, Barnes I, Kan S, Beral V. Cancer incidence in British Indians and British whites in Leicester, 2001–2006. British journal of cancer 2010;103:143-8.
6. Raza S, Goldkamp AL, Chikarmane SA, Birdwell RL. US of Breast Masses Categorized as BI-RADS 3, 4, and 5: Pictorial Review of Factors Influencing Clinical Management 1. Radiographics 2010;30:1199-213.
7. Berg WA, Blume JD, Cormack JB, Mendelson EB. Operator dependence of physician-performed whole-Breast US: lesion detection and characterization 1. Radiology 2006;241:355-65.
8. Lazarus E, Mainiero MB, Schepps B, Koelliker SL, Livingston LS. BI-RADS lexicon for US and mammography: interobserver variability and positive predictive value 1. Radiology 2006;239:385-91.
9. Abdullah N, Mesurolle B, El-Khoury M, Kao E. Breast Imaging Reporting and Data System Lexicon for US: Interobserver Agreement for Assessment of Breast Masses 1. Radiology 2009;252:665-72.
10. Berg WA, Gutierrez L, NessAiver MS, et al. Diagnostic accuracy of mammography, clinical examination, US, and MR imaging in preoperative assessment of breast cancer 1. Radiology 2004;233:830-49.
11. Graf O, Helbich TH, Fuchsjaeger MH, et al. Follow-up of Palpable Circumscribed Noncalcified Solid Breast Masses at Mammography and US: Can Biopsy Be Averted? 1. Radiology 2004;233:850-6.
12. Fischer U, Baum F, Obenauer S, et al. Comparative study in patients with microcalcifications: full-field digital mammography vs screen-film mammography. European radiology 2002;12:2679-83.
13. Kristoffersen Wiberg M, Aspelin P, Perbeck L, Bone B. Value of MR imaging in clinical evaluation of breast lesions. Acta radiologica (Stockholm, Sweden : 1987) 2002;43:275-81.
14. Kriege M, Brekelmans CT, Boetes C, et al. Efficacy of MRI and mammography for breast-cancer screening in women with a familial or genetic predisposition. The New England journal of medicine 2004;351:427-37.
15. Bennett I, Fentiman I. Diagnosis of breast cancer in young women. Australian and New Zealand Journal of Surgery 1991;61:284-9.
16. Barton MB, Elmore JG, Fletcher SW. Breast symptoms among women enrolled in a health maintenance organization: frequency, evaluation, and outcome. Annals of internal medicine 1999;130:651-7.
17. Perdue P, Page D, Nellestein M, Salem C, Galbo C, Ghosh B. Early detection of breast carcinoma: a comparison of palpable and nonpalpable lesions. Surgery 1992;111:656-9.
18. DB. K. Palpable abnormalities and breast imaging. In: Breast Imaging. 2nd Edition ed: Lippincott williams& Wilkins; 1998.
19. Coveney E, Geraghty J, O'Laoide R, Hourihane J, O'Higgins N. Reasons underlying negative mammography in patients with palpable breast cancer. Clinical radiology 1994;49:123-5.
20. Weinstein S, Conant E, Orel S, Zuckerman J, Czerniecki B, Lawton T. Retrospective Review of Biopsies of Palpable Breast Lesions after Negative Mammography and Sonography. JOURNAL OF WOMENS IMAGING 2000;2:15-8.
21. Soo MS, Rosen EL, Baker JA, Vo TT, Boyd BA. Negative predictive value of sonography with mammography in patients with palpable breast lesions. American Journal of Roentgenology 2001;177:1167-70.
22. Moss HA, Britton PD, Flower CD, Freeman AH, Lomas DJ, Warren RM. How reliable is modern breast imaging in differentiating benign from malignant breast lesions in the symptomatic population? Clinical radiology 1999;54:676-82.
23. Georgian-Smith D, Taylor KJ, Madjar H, et al. Sonography of palpable breast cancer. Journal of clinical ultrasound 2000;28:211-6.