ORIGINAL RESEARCH PAPER

Volume-8 | Issue-1 | January-2019 | PRINT ISSN No 2277 - 8179

INTERNATIONAL JOURNAL OF SCIENTIFIC RESEARCH

EVALUATION OF PAINLESS HEMATURIA USING MDCT UROGRAPHY: A PROSPECTIVE STUDY IN TERTIARY CARE CENTRE IN NORTH INDIA

Radiodiagnosis

Manik Mahajan* Lecturer, Department of Radio-Diagnosis & Imaging, Government Medical College, Jammu *Corresponding Author

Poonam Sharma Demonstrator, Department of Pathology, Government Medical College, Jammu

Sumeet Sabharwal Medical Officer, Department of Radio-Diagnosis & Imaging, Government Medical College, Jammu

Ghanshyam Dev Gupta Professor and Head, Department of Radio-Diagnosis & Imaging, Government Medical College, Jammu

ABSTRACT

Background:
Hematuria is common urological condition and may originate in any site in the urinary tract. Gross hematuria is alarming and has a high predictive value for malignancy while definition of microscopic hematuria is controversial. UB and renal masses are the commonest cause of painless hematuria. MDCT provides comprehensive non invasive evaluation of the urinary tract and is the modality of choice for evaluation of painless hematuria.

Aim/Objectives:
To evaluate the role of MDCT urography in patients with painless hematuria and to describe the MDCT findings of common etiologies causing it.

Material and Methods:
One Hundred and Twenty eight patients presenting with painless hematuria were included. Detailed history and findings of clinical examination were recorded. Non contrast, contrast enhanced and urographic phase images were obtained. Positive findings were recorded in detail and tabulated. Histopathological and cystoscopic correlation was performed wherever indicated.

Results:
Maximum cases were seen in 6th decade with male preponderance (3:1). Positive MDCT findings were seen in 92% cases. The commonest findings were UB mass (75.8%), renal masses (11.7%) and BPH (2.3%). Two cases each of retrocaval/circumcaval ureter and partial PUJ obstruction were also seen. No cause was identified in 8% cases. MDCT was 100% sensitive in diagnosing UB mass while it was 92.9 % sensitive in diagnosis and characterisation of renal neoplastic masses.

Conclusions:
MDCT urography should be considered as first line imaging modality in patients with painless hematuria and can also diagnose congenital urinary tract anomalies with fair accuracy.

KEYWORDS

Painless; Computed Tomography; Hematuria; Mass

INTRODUCTION:

Hematuria is common urological condition in young adults and reported in 0.3–38.7% of adults in population-based studies [1–3]. Hematuria may be gross or microscopic and may originate from any site along the urinary tract. Gross hematuria is alarming and has a high predictive value for malignancy while definition of microscopic hematuria is quite controversial and several factors contribute to its definition including the urine collection method, hematuria detection method, number of positive results, and patient characteristics [4].

Hematuria may be painful or painless. Painful hematuria is mostly associated with renal calculi and urinary tract infection while painless hematuria is quite frequently associated with underlying malignancy. UB and renal masses account for the commonest cause of painless hematuria in young adults as well as elderly individuals [5].

Evaluation of hematuria includes detailed history and physical examination. Complete evaluation includes cytology, cystoscopy, and upper tract imaging [5]. Common imaging modalities to evaluate hematuria include intravenous urography (IVU), ultrasonography (USG) and Computed Tomography (CT). IVU and USG were the initial imaging modalities used in valuation of hematuria. IVU has poor sensitivity and specificity in diagnosis of neoplastic lesions and is a time consuming procedure. USG is safe and reasonably accurate modality for the evaluation of the kidneys and UB but has poor ability to detect calculi and small renal and UB masses [5]. MDCT provides single comprehensive non invasive evaluation of the urinary tract and is the first line imaging modality of choice for evaluation of hematuria [5]. CT urography combines the benefits of excretory urography and cross sectional imaging, thus depicting the renal parenchyma, collecting system, ureters and bladder in a single study and allowing detection of small neoplasms which are an important cause of painless hematuria [6]

So the purpose of the study was to evaluate the role of MDCT in patients with painless hematuria and to describe the MDCT features of various common etiologies causing it.

MATERIAL AND METHODS:

This prospective study was performed in tertiary care centre in north India. One Hundred and twenty eight patients who presented with painless hematuria (gross or microscopic) were included in the study. Patients with painful hematuria, history of trauma, altered renal functions, history of allergy to contrast media and pregnant and lactating patients were excluded from our study. Detailed clinical history and relevant investigations were recorded. MDCT examination was performed after at least 6 hours of fasting with 64 slice-MDCT scanner (Somatom Definition AS+ scanner from Siemens Healthcare). Patients were scanned in the supine position using a three-scan CT protocol, including an unenhanced scan, a nephrographic phase scan and excretory phase scan of the abdomen and pelvis after contrast injection. Additional delayed scans were also obtained in some patients depending upon findings observed during nephrographic and excretory phase. Findings of the examinations were recorded and source of hematuria was determined. In patients with UB and renal mass, histopathological evaluation was also performed wherever possible.

RESULTS:

Total of 128 patients with painless hematuria were included. Majority of the patients were seen in 6th decade of life followed by 5th decade (Table 1). Most of the patients were males with male to female ratio of 3:1 (Table 1). Youngest patient was 3 years old while oldest patient was 84 years old.

Cause of hematuria was seen in approx. 92% cases while no cause could be identified in approx. 8% cases. UB mass was the most common cause seen in 75.8 % cases followed by renal lesions (11.7%) and BPH (2.3%) (Table 2).

All the cases of UB mass were transitional cell carcinoma. Majority of patients with UB malignancy were seen in sixth decade with a marked male preponderance. History of Smoking was present in >80% of the cases and all the cases were proved as TCC. Majority of them appeared as focal enhancing wall thickening (72.2%) (Figure 1) followed by enhancing discrete nodule or mass (26.8%) (Figure 2). Abnormal focal hyperenhancement was also seen in a solitary case. MDCT was 100% sensitive in diagnosing UB malignancy.

Majority of the renal lesions included renal cell carcinoma (11 cases). Two cases of Angiomyolipoma and solitary case of wilms tumour and parapelvic cyst were also seen. In two cases, cause of hematuria was attributed to renal calculi and patient had no history of pain. Four cases of ureteral anomalies were also seen including circumcaval/retrocaval (2 cases) and PUJ obstruction (partial or complete) (2 cases) (Table 2). Out of 11 cases of RCC, 10 were diagnosed correctly while solitary case of wilms tumour was also correctly diagnosed. All cases of RCC showed heterogeneous enhancement with areas of necrosis (Figure 3). Renal vein invasion was also seen in 2 cases. Hemorrhage or calcifications were not seen in any case. In one case, two small heterogeneously enhancing masses were seen in right kidney (Figure 4). Patient had undergone nephrectomy on left side for RCC one year back. So on MDCT possibility of metastasis was given as patient had multiple small nodular lesions in lung also. However on histopathology the lesions proved as RCC. Solitary case of wilms tumour was also seen in 3 year old child. Necrosis with heterogeneous enhancement was seen (Figure 5). Both cases of Angiomyolipoma had areas of macroscopic fat along with enhancing soft tissue component (Figure 6). Diagnosis was correctly made on MDCT. So MDCT was 92.9 % sensitive in diagnosis and characterisation of renal neoplastic masses.

Solitary case of parapelvic cyst was also seen in our study. The lesion appeared as thin walled cystic lesion without any enhancing solid component and seen extending into renal hilum with minimal mass effect over renal pelvicalyceal system (Figure 7).

Three cases of BPH were also detected as the cause of painless hematuria. These cases showed enlargement of prostate with median lobe protruding in to the bladder in 2 patients. Sagittal and Coronal reformatted images were helpful in differentiating enlarged prostate from polypoidal bladder growth (Figure 8).

Two cases each of circumcaval/retrocaval ureter (Figure 9) and partial PUJ obstruction (Figure 10) were also seen. These patients presented with painless microscopic hematuria detected incidentally on urine routine examination. Similarly two patients with renal calculi were also seen in the study. Patient denied any history of flank pain and presented with increased frequency of micturation. Diagnosis was established on MDCT urography and surgical repair undertaken in one case each of retrocaval ureter and partial PUJ obstruction. Rest two case were lost to follow up.

DISCUSSION:

American Urologic Association for the evaluation of adults with hematuria published the practice guidelines in 2001 and recommend the initial upper urinary tract imaging with either excretory urography or CT urography, in addition to cystoscopy of the UB and urine cytology [5,7]. MDCT has better diagnostic accuracy for diagnosing urinary calculi, renal and UB masses, renal and perirenal infections, and unsuspected extra-urinary diseases as compared to excretory urography [8–11]. Also CT urography has been recommended over excretory urography by the American College of Radiology in the evaluation of hematuria [11].

Painless hematuria is classically associated with the underlying malignancy and prevalence of urinary tract carcinomas in patients with macroscopic hematuria has been reported to be as high as 19% [12]. CT urography has been established as the overall most sensitive modality for determining the cause of hematuria and is the gold standard in the detection of renal parenchymal masses, urinary tract urothelial tumors, and extrinsic lesions [6].

In our study, majority of cases were seen in 6th decade of life with marked male preponderance as reported by Yaman Ö et al [12] and Tyagi N et al [6]. UB masses accounted for majority of the cases in our study (75.8 % cases) as in previously published studies [6]. Majority of cases were smokers and thus justifying the association of smoking with UB malignancy as reported in previous studies [13,14]. TCC was the commonest type seen in our study, similar to findings of previously published studies [6,15]. In our study MDCT was 100 % sensitive in diagnosing UB masses and also provided information regarding its extension and staging.

Renal neoplastic lesions were the 2nd commonest cause of painless hematuria in our study (11.7%). Majority of these were renal cell carcinoma (11 cases) with one case of wilms tumour and two cases of angiomyolipoma. Single case of RCC was falsely diagnosed as metastasis on MDCT but was later proved as RCC on histopathology. MDCT was 91.6% sensitive in detecting and characterizing renal masses and differentiating benign from malignant lesions similar to other studies [6,16].

Solitary patient of wilms tumor was below the age of 5 years similar to previous studies [6,17]. In our study, wilms tumor was seen as large heterogeneously enhancing renal mass with necrosis. No evidence of renal vein invasion and metastasis were noted.

Solitary case of parapelvic cyst, three cases of BPH and two cases each of circumcaval/retrocaval ureter and partial PUJ obstruction were also seen. Diagnosis was established clearly on MDCT urography.
The potential disadvantages of MDCT include cost and its inability to detect bladder carcinoma in situ and metaplasia. Another significant concern regarding the use of MDCT is the radiation exposure. The mean effective dose of CT urography is 14.8 mSv which is to approximately 1.5 times the radiation risk from IVU [18]. This radiation exposure is significantly higher and thus judicious and cautious use of MDCT is required especially in evaluation of hematuria in young adults.

CONCLUSIONS:

Painless hematuria is associated with the underlying malignancies in significant cases. MDCT urography is the first line imaging modality in these patients for detection of neoplastic masses with high sensitivity and specificity. MDCT provides detailed information about local infiltration of the tumor, lymphadenopathy and metastasis and thus has important role in staging also. Further MDCT can guide the clinician regarding appropriate treatment strategy and thus aid in prognostic evaluation. Only limitation is the radiation exposure associated with MDCT and thus judicious use is advocated.

Conflicts of Interest: Nil
Source of Funding: Nil
Acknowledgements: Nil

Tables

Table 1: Age & Sex Distribution (n=128)

Age Group	Number of Patients	Number of Males	Number of Females
0-10	3	3	-
11-20	2	2	-
21-30	4	2	2
31-40	9	7	2
41-50	26	16	8
51-60	44	34	10
61-70	34	27	7
>70	8	5	3
Total	128	96	32

Table 2: Sources of Painless Hematuria Identified on MDCT (n=76)

Category	No. of Patients
Life Threatening A) Vesical Mass	97
B) Renal Mass	15
Significant and Requiring Treatment	3
A) Benign Prostatic Hyperplasia	2
B) Renal and/or ureteral calculus	2
C) Circumcaval/Retrocaval Ureter	2
D) Partial PUJ obstruction	

No cause seen	8
Total	128

Table 3: Renal Masses Causing Hematuria (n=15)

Lesion	No. of Patients
A) Renal Cell Carcinoma	11
B) Angiomyolipoma	2
C) Parapelvic Cyst	1
D) Wilms Tumour	1
Total	15

Figures:

Figure 1:



Axial (A&C) and Coronal (B&D) Contrast Enhanced and Urographic images reveal enhancing plaque like thickening along right lateral posterior UB wall

Figure 2:



Axial (A&C) and Coronal (B&D) Contrast Enhanced and Urographic images reveal enhancing polypoidal lesion along left posterolateral UB wall.

Figure 3:

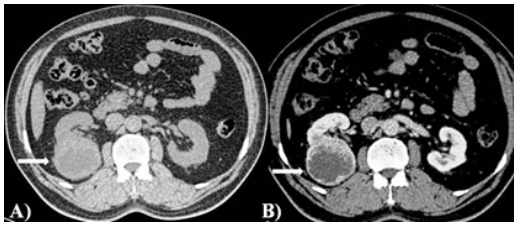

Axial Non Contrast (A) and Contrast Enhanced (B) MDCT images reveal heterogeneously enhancing mass lesion involving the mid pole of right kidney (white arrows).

Figure 4:



Axial Non Contrast (A), Axial and Coronal Contrast Enhanced (B & C) and Urographic phase images reveal two small heterogeneously enhancing mass lesions involving the upper pole of right kidney. Left Kidney is not seen (post nephrectomy status).

Figure 5:

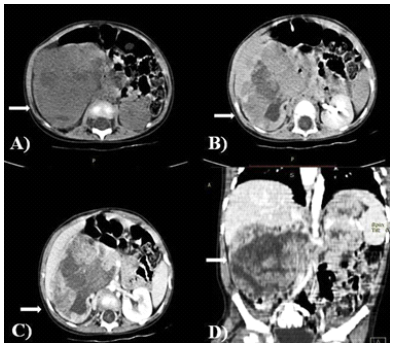

Axial NCCT and Axial and Coronal CECT images reveal large ill defined heterogeneously enhancing lesion with necrosis involving right kidney and crossing midline with displacement of renal vessels.

Figure 6:

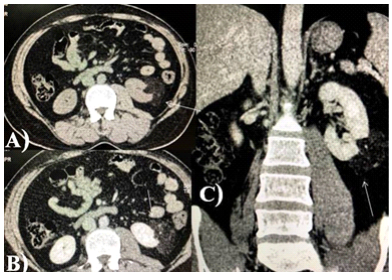

Axial Non Contrast (A) and Axial and Coronal Contrast Enhanced (B & C) images reveal fat density lesion arising from mid pole of left kidney.

Figure 7:

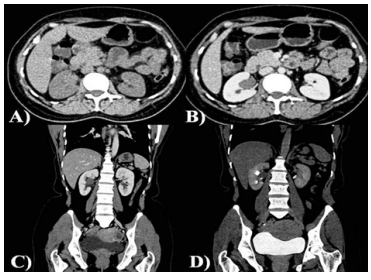

Axial NCCT (A), Axial and Coronal (A&B) CECT and Urographic (D) images reveal non-hypodense lesion extending into renal hilum with minimal mass effect over renal pelvicalyceal system

Figure 8:

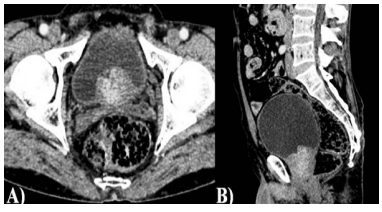

Axial CECT images reveal enlarged median lobe projecting into UB lumen in a case of BPH

Figure 9:

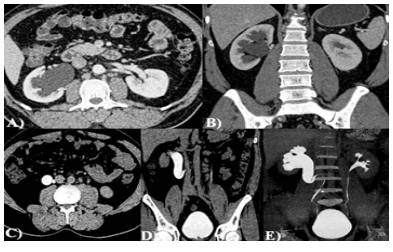

Axial and Coronal (A&B) CECT and Urographic (C,D,E) images

show presence of circumcaval ureter on right side with moderate proximal ureterohydronephrosis.

Figure 10:



Axial Non Contrast (A), Axial and Coronal CECT (B&C) and Urographic images show presence of partial PUJ obstruction on right side