ORIGINAL RESEARCH PAPER

Volume-8 | Issue-1 | January-2019 | PRINT ISSN No 2277 - 8179

INTERNATIONAL JOURNAL OF SCIENTIFIC RESEARCH

EVALUATION OF RESULTS OF PERONEUS LONGUS GRAFT IN PRIMARY A.C.L RECONSTRUCTION : A PROSPECTIVE STUDY

Orthopaedics

Dr Sarthak Mohanty MS Senior Resident All India Institute of Medical Sciences, Bhubaneswar.

Dr Atanu Mohanty* MS, Mch Associate Professor, SCB Medical College, Cuttack. *Corresponding Author

Dr Abhisek Mishra Junior Resident SCB Medical College, Cuttack

Anuraag Mohanty 3rd year MBBS IMS and SUM Hospital SOA University, Bhubaneswar

ABSTRACT

Objective: To study the scope of Peroneus Longus Tendon (PLT) as an autologous graft in primary ACL reconstruction surgeries and evaluate its possible effect on foot and ankle function.

Material and Methods: Prospective study on 42 patients undergoing a primary ACL reconstruction with a Peroneus Longus Tendon autograft. Post-operative knee function was evaluated by the International Knee Documentation Committee (IKDC) and Modified Lysholm Knee Scoring Scale. The functional status of ankle in follow up visits was evaluated by the Foot and Ankle Disability Index (FADI) score and American Orthopaedic Foot and Ankle Society Score (AOFAS). Foot imprints were obtained by a baropedometer and Staheli's plantar arch index was calculated to evaluate any loss of integrity of the arches of the foot.

Results: The average diameter and length of the doubled harvested tendon was 8.5mm and 13.5 cm respectively. The mean IKDC scores at 6 months follow up was 86.98 and at 1 year follow up was 93.4 showing an improvement of 50 points from pre-op values. At 6 months follow up, the Lysholm score grading showed 'Excellent' in 39 cases and 'Good' in 3 case, becoming 'Excellent' in all 42 of the cases after 1 year. The mean 6 months and 1 year follow up AOFAS scores were 97.7 and 100 respectively and it remained unchanged thereafter. The mean FADI scores showed similar results. Foot mapping with the use of a Baropedometer and calculating the Staheli's arch index showed no evidence of loss of integrity of foot arches.

Conclusion: This study showed the efficiency of peroneus longus can be used as a graft for primary A.C.L reconstructions considering its excellent post-operative knee scores. It also established that removing the PLT has no effect on the functioning of the ankle and the foot.

KEYWORDS

INTRODUCTION:

Multiple graft options exist for primary ACL reconstruction with their unique advantages and disadvantages. These are basically of two main types: allograft and autograft, of which autografts are more widely used.

The two main autografts used for ACL reconstruction are bone patellar bone (BPB) and the hamstrings. Main disadvantages of BPB are risks of patellar fracture, knee extension weakness, and anterior knee pain [4, 3, and 16].

Hamstring tendons having a good mechanical strength and lower donor site complications rate is the most widely used autograft. However in many situations, the hamstrings grafts fall short in diameter and length. Also the resulting post-operative hamstring weakness makes the knee susceptible to an unprotected anterior drawer force [17, 23, 7, and 21]. So the choice of a suitable alternate graft is still a matter of debate.

It has been opined by various researchers that the Peroneus Longus tendon (PLT) is a suitable choice for autograft because of its biomechanical properties, but studies about its side effects are insufficient [18, 13].

In this research, we evaluated the efficacy of Peroneus Longus tendon as a graft for primary ACL reconstruction and studied the possible effects of it on foot and ankle function.

Material and Methods:

Source of Data:

The study was conducted on patients with injuries of the ACL confirmed by clinical examinations and MRI studies during a period of 3 years and 7 months, from December 2014 to June 2018 in the Department of Orthopedics, S.C.B Medical College and Hospital, Cuttack, Odisha, India.

Inclusion Criteria:

1. Patients with primary injuries of the ACL.

Exclusion Criteria:

1. Multi-ligamentous injury.
2. Patients with pre-existing flat foot, ankle deformity, paralytic conditions, poliomyelitis or previous significant injuries to ankle.
3. Age > 60 years.
4. Patients with overlying skin infections over the knee or the ankle.
5. Patients with chronic systemic medical diseases.

The follow up was at 6 weeks, 8 weeks, 3 months, 6 months, 1 year and then annually up to 3 years. Out of 42 cases, 14 cases had more than 3 year follow up period, 17 cases had up to 2 years and 11 cases had up to 1 year follow up.

Pre-Operative Evaluation:

All patients were assessed clinically and functionally as per the International Knee Documentation Committee (IKDC) Score and Modified Lysholm Scores.

The functional ankle morbidity was evaluated in all patients according to the Foot and Ankle Disability Index (FADI) score and American Orthopaedic Foot and Ankle Society Score (AOFAS).

Preoperative digital foot imprints of both feet were taken in all the patients to evaluate the plantar arches and were kept as a control for comparison with post-operative foot prints to assess changes, if any. The presence of a flat foot was assessed by calculating the Staheli's Plantar Index [20].

For obtaining footprints, we selected a Baropedometer (Harrismat) and was then digitally processed it to scan for pressure areas and to compare any changes in them post operatively.



Fig 1: Foot imprints being taken by a Baropedometer

Operative Procedure:
In all the cases, Peroneus longus was harvested from the ipsilateral leg. With patient in supine position and table tilted to the opposite side, a 1 cm incision was given just behind the lateral malleolus, protecting the sural nerve, the tendon was harvested using an open or closed tendon stripper. The peroneus longus was identified by great toe movement on giving a tug to the tendon and absence of muscle attachment at the inscision site. Double stranded tendon of the harvested peroneus longus was used for reconstruction of ACL.



Fig 2: The peroneus longus is isolated



Fig 3: Tendon doesn't retract back after it is cut.



Fig 4: A graft length of about 32 cm was obtained

The surgical steps of ACL reconstruction was carried out as per the standard procedure of single bundle reconstruction. Standard post-operative rehabilitation protocol was followed.

We hypothesized that the tibial jig placement during creation of tibial tunnel might damage the pes anserinus and hence losing the advantage of hamstrings preservation. To address this issue, we did post-operative magnetic resonance imaging in 9 of our cases to look for any evidence of injury to the pes anserinus.

Results:
This is a prospective study of 42 patients who underwent ACL reconstruction using peroneus longus tendon as a graft. The majority of patients were from the age group of 31-35 years, accounting for 42% of cases. The mean age was 34.38 years.

The average diameter and length of the doubled harvested tendon was 8.5mm and 13.5 cm respectively.

The International Knee Documentation Committee (IKDC) and Modified Lysholm Knee Scoring Scale were used to assess the results of ACL reconstruction in our study.

The mean IKDC scores at 6 months follow up was 86.98 and at 1 year follow up was 93.4 showing an improvement of about 50 points from the pre-operative values (53.6). It further improved to 97.5 at 2 years and remained unchanged thereafter.

The mean Lysholm score at 6 months follow up was 93.1 and at 1 year follow up was 96.2 showing an improvement of 64 points from pre-op values. It further increased to a mean of 98.8 at 2 years and stayed unchanged thereafter.

At 6 months follow up, the Lysholm score grading showed 'Excellent' in 39 cases and 'Good' in 3 case. At 1 year follow up, it was 'Excellent' in all 42 of the cases.

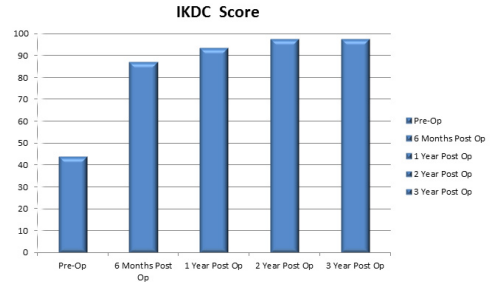

Fig 5: International Knee Documentation Score

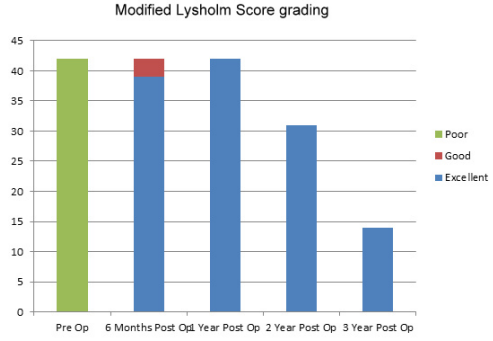

Fig 6: Modified Lysholm Score grading

The post-operative MRI done in 9 cases of our study group showed intact pes anserinus and no evidence of any injury to it.

Donor site Evaluation:
The mean 6 months and 1 year follow up AOFAS scores were 97.7 and 100 respectively and it remained unchanged thereafter. The mean FADI scores at 6months and 1 year follow up were 99.53 and 100 respectively and remained constant in the subsequent follow ups. The pre-operative AOFAS and FADI scores were 100 in all the cases. The mean AOFAS and FADI scores at 1 year and thereafter showed no difference from the pre-op values.

Foot mapping with the use of a Baropedometer showed no increase in pressure areas from the pre-op tests showing an intact arch of the foot. It was further confirmed by calculating Stahli's Plantar Arch Index on the foot prints. It showed no difference in pre-op and 6 month post-op values. There was no evidence of loss of integrity of plantar arch in any of the successive follow ups.

Discussion:
The focus of much of the research in ACL reconstruction surgery has been related to graft selection and its impact on clinical outcomes. An ideal graft would be one that has similar structural and biomechanical characteristics of the native ligament, allow for secure fixation, permit rapid biologic incorporation, and have limited donor site morbidity [9, 22].

The graft sources available to the surgeon can be broadly categorized into autografts and allografts, of which autografts are most commonly used. Autologous grafts are can be harvested from the patellar tendon, the semitendinosus-gracilis tendons, the quadriceps tendon with or without a bone plug and the peroneus longus tendon.

Bone patellar tendon bone (BTB) autograft and hamstring autograft are conventionally two of the most popular graft sources for ACL reconstruction. Several studies with regard to BTB graft have reported donor site morbidity, like anterior knee pain, quadriceps weakness, risk of patellar tendon rupture and patellar fractures. [17, 16, 1] The drawbacks of hamstring tendon graft have been observed to be a

demonstrated weakness of the hamstring muscle strength postoperatively leading to an increased susceptibility of the reconstructed ligament against an anterior drawer force. [17, 23, 7, 21]

Peroneus longus tendon has been reported by several studies to be an appropriate graft for sports medicine reconstructive procedures including ACL reconstruction. [18, 13] Pearsall et al in 2003 did a comparative study of biomechanical properties of tendoachilles(TA), tibialis posterior(TP), and peroneus longus(PL) tendons and concluded that doubled TA, TP, and PL tendons demonstrated excellent tensile strength, stiffness, and cross sectional area compared to currently used grafts for ligamentous knee reconstruction. [13]

Graft fixation can be of two types, suspensory and aperture fixation. Out of them, the aperture fixation by Interference screw technique has been found to be more successful in many aspects including avoidance of suture stretch, graft tunnel pistoning, and windshield-wipering and thereby preventing the complications such as delayed incorporation of the graft in the tunnel, tunnel enlargement, and subsequent failure. [8, 15, 14]

For an ideal reconstruction, the diameter of the graft must be thick enough to approximate the diameter of the native ACL which is around 11mm. Moreover, it has been documented that, for an aperture fixation in tibia, the length of the graft must approximate 13cm. [10, 19]

Stergios et al in 2012, referring to hamstrings graft diameter in their study, found the majority of patients (86.7%) had a quadrupled graft diameter of 7 to 8 mm and 10% of patient's grafts were inadequate (less than 7 mm). Referring to female patients, this percent increases to 25%. Only 2 patients (3.3%) had an adequate graft diameter of greater than 8 mm. They also concluded that the length of semitendinosus tendon, is usually inadequate in order to be used alone as a four-strand graft for aperture fixation in tibia. [12] The augmentation with gracilis tendon though adds to its length, but however compromises with post-operative knee rehabilitation due to unprotected anterior drawer force.[1]

Our results showed the average diameter to be 8.5mm. The average length was found to be 13 mm which was adequate for aperture fixation in all cases. This also puts a question mark on the requirement of an all inside ACL technique which uses a retro reamer costing heavily to the patients.

Kerimoglu *et al*. evaluated the results of ACL reconstruction using a PLT autograft. The results in the form of post-operative Lachman test showed normal findings in 12 patients (41.4%) while 9 patients had 1+, 5 patients had 2+, and 3 patients had 3+ laxities [5] which are comparable to the results obtained in our study.

The post-operative MRI studies done in 9 of our cases showed an intact pes anserinus, hence proving our hypothesis regarding possibility of injury to pes anserinus during tibial jig placement to be untrue.

Studies comparing the evertor mechanisms of the peroneus brevis and peroneus longus muscle have concluded that Peroneus brevis is a more effective evertor than peroneus longus and harvesting of peroneus longus doesn't jeopardize the evertor function. [11]

Kerimoglu *et al*. used full-thickness PLT to reconstruct ACL and observed that their patients did not report any complaints about the ankle joint dysfunction or in sports activities. [5] The biomechanical testing of ankle function pre and post operatively have shown no significant difference. [18] It has shown no untoward effect on gait parameters or even stability of the ankle. [6]

In our study, we assessed the power around the ankle joint, especially the plantar flexion and eversion. There were no significant differences in the preoperative and post-operative values suggesting no objective loss of ankle strength. Our findings did correspond to all the previous studies described above.

To study the effect on arches of the foot, we took Digital Foot Mapping pre and post operatively in all of the patients and it showed no effect on integrity of the arch as evidenced by no increase in pressure areas on the imprint. This observation was further reinforced by estimating the Staheli's Plantar Arch Index and comparing the pre and post-operative values. No significant difference was found in preoperative and postoperative values. To our knowledge till date there are no reports as yet comparing the effect of loss of peroneus longus tendon on arch of foot.

Kerimoglu et al in 2009, in their MRI studies of follow up cases (average follow up of 52 months), showed the regenerative capacity of peroneus longus after harvesting for ACL reconstructions [5]. However we did not perform the follow up ankle MRIs to substantiate this claim.

In view of cosmetic concerns, the harvesting of a PLT graft conceals the tendon harvesting scar behind the lateral malleolus and also the scar around the tibial tunnel is significantly smaller. Hence it provides a cosmetic advantage to athletes who often need to have their legs exposed in their profession.

As far as complications are concerned, we encountered 2 cases of sural nerve neuropraxia, manifested as numbness over the lateral aspect of the foot, which subsequently recovered by treatment with neurovitamins. We feel that injury to sural nerve is less likely to occur as the course of the sural nerve is significantly away from the incision site for the graft harvesting.

Although the recent trend of ACL reconstruction is heading towards quadriceps tendon but it has its own disadvantage of requirement of specialized instrumentation for harvesting. [2]

So overall, the PLT provides yet another graft option with the advantage of an increased diameter and length making it most suitable for an aperture fixation, Its method of harvesting is simple and does not affect the function or biomechanics of the ankle jointwithout affecting the biomechanics of the ankle joint while simultaneously providing an improved cosmetic outcome. Moreover the graft harvesting technique is relatively simple, fast and has a short learning curve.

Conclusion:

This study showed the efficiency of peroneus longus to be used as a graft for primary ACL reconstruction, ease of harvest , adequate size considering excellent post-operative knee scores, it is established that removing the PLT has no effect on the function of the ankle and the foot a whole on the gait parameter.

REFERENCES:

1. Gobbi A1, Tuy B, Mahajan S, Panuncialman I. Quadrupled bone-semitendinosus anterior cruciate ligament reconstruction: a clinical investigation in a group of athletes. Arthroscopy. 2003 Sep;19(7):691-9. [PubMed]
2. Harris S. Slone, M.D., William B. Ashford, M.D., and John W. Xerogeanes, M.D. Minimally Invasive Quadriceps Tendon Harvest and Graft Preparation for All-Inside Anterior Cruciate Ligament Reconstruction. Arthrosc Tech. 2016 Oct; 5(5): e1049–e1056. [PMC]
3. Järvelä T1, Kannus P, Järvinen M, Anterior knee pain 7 years after an anterior cruciate ligament reconstruction with a bone-patellar tendon-bone autograft, Scand J Med Sci Sports. 2000 Aug;10(4):221-7. [PubMed]
4. Kartus J1, Stener S, Köhler K, Sernert N, Eriksson BI, Karlsson J., Is bracing after anterior cruciate ligament reconstruction necessary? A 2-year follow-up of 78 consecutive patients rehabilitated with or without a brace, Knee Surg Sports Traumatol Arthrosc. 1997;5(3):157-61. [PubMed]
5. Kerimoğlu S1, Koşucu P, Livaoğlu M, Yükünç I, Turhan AU. Magnetic resonance imagination of the peroneus longus tendon after anterior cruciate ligament reconstruction. Knee Surg Sports Traumatol Arthrosc. 2009 Jan;17(1):35-9. doi: 10.1007/s00167-008-0626-7. Epub 2008 Sep 26.
6. Khalilallah Nazem, Mohammadreza Barzegar, Alireza Hosseini,1 andMohammadtaghi Karimi2 Can we use peroneus longus in addition to hamstring tendons for anterior cruciate ligament reconstruction? Adv Biomed Res. 2014; 3: 115. Published online 2014 May 19. [PMC]
7. Kobayashi A1, Higuchi H, Terauchi M, Kobayashi F, Kimura M, Takagishi K. Muscle performance after anterior cruciate ligament reconstruction. Int Orthop. 2004 Feb;28(1):48-51. Epub 2003 Aug 26. [PubMed]
8. Kurosaka M, Yoshiya S, Andrish JT. A biomechanical comparison of different surgical techniques of graft fixation in anterior cruciate ligament reconstruction. Am J Sports Med. 1987 May-Jun;15(3):225-9. [PubMed]
9. Miller SL, Gladstone JN. Graft selection in anterior cruciate ligament reconstruction. Orthop Clin North Am 2002;33:675-683.
10. Naiyer Asif, Rahul Ranjan, Sohail Ahmed, Aamir B Sabir, Latif Z Jilani, andOwais A Qureshi. Prediction of quadruple hamstring graft diameter for anterior cruciate ligament reconstruction by anthropometric measurements. Indian J Orthop. 2016 Jan-Feb; 50(1): 49–54. [PMC]
11. Otis JC1, Deland JT, Lee S, Gordon J. Peroneus brevis is a more effective evertor than peroneus longus. Foot Ankle Int. 2004 Apr;25(4):242-6. [PubMed].
12. Papastergiou G. Stergios,1 Konstantinidis A. Georgios,1 Natsis Konstantinos,2 Papathanasiou Efthymia,2 Koukoulias Nikolaos,1 and Papadopoulos G. Alexandros1. Anatomy Research International Volume 2012, Article ID 424158.
13. Pearsall AW 4th1, Hollis JM, Russell GV Jr, Scheer Z. A biomechanical comparison of three lower extremity tendons for ligamentous reconstruction about the knee. Arthroscopy. 2003 Dec;19(10):1091-6. [PubMed]
14. Pinczewski LA1, Thuresson P, Otto D, Nyquist F. Arthroscopic posterior cruciate ligament reconstruction using four-strand hamstring tendon graft and interference screws. Arthroscopy. 1997 Oct;13(5):661-5.
15. Robbe R, Paletta GA., Jr Soft-tissue graft fixation in anterior cruciate ligament reconstruction. Oper Tech Sports Med. 2004;12:188–194. doi:

10.1053/j.otsm.2004.07.010.
16. Sachs RA1, Daniel DM, Stone ML, Garfein RF, Patellofemoral problems after anterior cruciate ligament reconstruction, Am J Sports Med. 1989 Nov-Dec;17(6):760-5. [PubMed]
17. Savio L-Y Woo, Changfu Wu, Ozgur Dede, Fabio Vercillo, and Sabrina Noorani. Biomechanics and anterior cruciate ligament reconstruction. J Orthop Surg. 2006; 1: 2. [PMC]
18. Shi FD1, Hess DE2, Zuo JZ3, Liu SJ1, Wang XC1, Zhang Y1, Meng XG1, Cui ZJ1, Zhao SP1, Li CJ1, Hu WN1. Peroneus Longus Tendon Autograft is a Safe and Effective Alternative for Anterior Cruciate Ligament Reconstruction. J Knee Surg. 2018 Sep 11. doi: 10.1055/s-0038-1669951. [PubMed]
19. Snæbjörnsson, Thorkell & Hamrin Senorski, Eric & Ayeni, Olufemi & Alentorn-Geli, Eduard & Krupic, Ferid & Norberg, Fredrik & Karlsson, Jon & Samuelsson, Kristian. (2017). Graft Diameter as a Predictor for Revision Anterior Cruciate Ligament Reconstruction and KOOS and EQ-5D Values: A Cohort Study From the Swedish National Knee Ligament Register Based on 2240 Patients. The American Journal of Sports Medicine. 45. 036354651770417. 10.1177/0363546517704177.
20. Staheli LT, Chew DE, Corbett M. The longitudinal arch. A survey of eight hundred and eighty-two feet in normal children and adults. J Bone Joint Surg Br. 1987;69A:426–428. [PubMed]
21. Tosetti M, Linsalata S, Battini R, et al. Muscle metabolic alterations assessed by 31-phosphorus magnetic resonance spectroscopy in mild Becker muscular dystrophy. Muscle Nerve. 2011; 44:816–9. [PubMed]
22. West RV, Harner CD. Graft selection in anterior cruciate ligament reconstruction. J Am Acad Orthop Surg 2005;13:197-207
23. Yasuda K1, Tsujino J, Ohkoshi Y, Tanabe Y, Kaneda K. Graft site morbidity with autogenous semitendinosus and gracilis tendons. Am J Sports Med. 1995 Nov-Dec;23(6):706-14. [PubMed]