Original Research Paper

VOLUME-6 | ISSUE-1 | JANUARY-2017 • ISSN No 2277 - 8179 | IF : 3.508 | IC Value : 78.46

Evaluation of White matter diseases by Magnetic Resonance Imaging.

Radiology

KEYWORDS: Magnetic Resonance Imaging; White matter diseases; Demyelinating diseases; Dysmyelinating diseases.

Dr. Richa Arora — Assistant Professor, Department of Radiology and Imageology, Nizam's Institute of Medical Sciences, Hyderabad – 500082

Dr. Abhishek J. Arora — Assistant Professor, Department of Radiology and Imageology, Nizam's Institute of Medical Sciences, Hyderabad – 500082 Corresponding Author

ABSTRACT

The white matter diseases of the central nervous system constitute a complex group of diseases. Neuroimaging, in particular, Magnetic Resonance Imaging has made major contribution to the clinical evaluation & understanding of the white matter diseases. The pathological processes that prevents the normal formation and maintenance of myelin or that selectively destroy the oligodendrocytes or myelin sheath causes white matter disease, which can be categorized as Inherited or dysmyelinating disease and Acquired or demyelinating disease. Dysmyelination refers to the formation of intrinsically abnormal myelin, resulting in poor myelination or early myelin degeneration, whereas, demyelinating disease refers to degradation of normal myelin due to disease process.

Aims and Objectives:
This study was carried out at our institute from June 2014 to June 2016 with the following aims and objectives:

1. To determine the sensitivity and specificity of MRI in detecting white matter diseases.
2. To identify, localize and characterize the white matter abnormality.
3. To monitor the natural progression of various white matter disorders and response to therapy.

Inclusion Criteria:
Twenty patients with a strong clinical suspicion of white matter diseases were evaluated by Magnetic Resonance Imaging of brain and as and when required spine during the above mentioned period. No selection bias was exercised in terms of patients' age, gender and pathology.

Exclusion Criteria : All the patients with age related vascular/ischemic causes were excluded from the study group.

All the patients were followed up till 17 months inorder to reach therapeutic diagnosis. The symptomatic response of the patients to medical therapy was noted which helped in the retrospective confirmation of diagnosis. Brain biopsy was not done in any of the cases.

Materials and Methods:
The following technique was adapted for the examination. MRI scan was performed using 1.5 T GE scanner using standard head coil for acquisition of images. Axial and sagittal scans were obtained using multislice multiecho sequences with slice thickness of 5 mm. The data acquisition was done using a matrix of 256 x 192. For T_1W images pulse sequence used were TR/TE of 596/15 msec and for T_2W images, TR/TE was of 4500/100 msec was used. Special sequence like FLAIR was obtained in all cases with TR/TE of 6000/100 msec in the coronal plane.

Contrast (Gadolinium-DTPA) at dose of 0.1mmol/kg body weight was given wherever necessary. None of the patients had any adverse reactions following Gadolinium injections. In order to prevent head movements in children, sedation was given to pediatric patients.

Observations and Analysis
The study consisted of 20 patients, 12 males and 8 females between age group of 1-55 years. Maximum number of patients were between age group of 11-30 years. The average age of patients was 24.7 years with overall gender ratio of 1.5:1.

The disease profile of various age groups in our study was as follows:

Table no 1

	0-10	11-20	21-30	31-40	41-50	51-60
Multiple Sclerosis	1	2	3	2	1	-
Acute disseminated encephalomyelitis	-	1	1	-	-	-
HIV Encephalopathy	-	-	-	-	-	1
Periventricular leukomalacia	1	-	-	-	-	-
Cental pontine myelinolysis	-	-	1	-	-	-
Subacute combined degeneration	-	-	-	1	-	-
Dysmyelinating (One case each of Hurlers and Adrenoleukodystrophy)	2	2	-	1	-	-

Demyelinating diseases were more common than dysmyelinating disease and among the demyelinating pathologies, the commonest etiology encountered in our study was inflammatory etiology. Among the inflammatory diseases, multiple sclerosis is the commonest accounting for 45% of all white matter diseases and 60% of all demyelinating diseases. The commonest symptom of presentation in patients with white matter diseases was weakness. All white matter lesions appeared iso-hypo intense on T_1W images and hyperintense on T_2W and FLAIR images.

Dysmyelinating lesions were usually bilateral, symmetrical and confluent in nature whereas, in demyelinating lesions the distribution of lesions depended on the underlying pathology and the lesions were usually discrete. Dysmyelinating lesions were common in younger age groups between 0-20, however, one case presented at the age of 40 yrs. On evaluating the site of involvement within brain it was observed that Deep white matter involvement accounted for the highest number of cases, with total of 13 cases out of 20. Multiple sclerosis lesions were common in periventricular, corpus callosum and brainstem region. Deep gray matter involvement along with periventricular, subcortical and brain stem involvement was diagnostic of ADEM. Central pontine myelinolysis was confined to central pons only with extrapontine lesion found in thalamus. Dysmyelinating lesions were commonest in deep white matter and periventricular location. Subcortical U fibres were only involved with Dysmyelinating diseases. Corpus callosal involvement was much specific for multiple sclerosis lesions. No other pathology showed predilection for corpus callosum in our study [1-5].

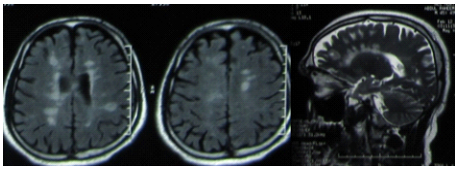

Figure 1: Axial and Sagittal T2W images showing oval, hyperintense, periventricular white matter lesions in a case of Multiple Sclerosis.

Perilesional edema and mass effects were rare findings in patients with white matter diseases. In clinically suspected cases of multiple sclerosis, paraclinical tests like MRI, evoked potentials and CSF analysis helps in confirmation of diagnosis. MRI provided the temporal metabolic map of the various lesions. Most common sites of involvement in patients with multiple sclerosis were periventricular white matter, brainstem and corpus callosum. Clinical suspicion of multiple sclerosis in age group of 20-40 years with long tract signs, spinal cord or optic nerve involvement with MRI findings of white matter hyperintensity involving the periventricular region, corpus callosum or brainstem was confirmatory for diagnosis of multiple sclerosis. Callosal septal interface had highest sensitivity and specificity for multiple sclerosis. Multiple, discrete, ovoid lesions which are perpendicular to ventricular axis and known as Dawson's fingers are pathognomic for multiple sclerosis and ruled out other differential of periventricular hyperintensity [6-11].

In pediatric multiple sclerosis, brainstem involvement was more common along with periventricular involvement. Involvement of both brain and spinal cord imaging greatly increased sensitivity and specificity to almost 100% for multiple sclerosis. Chronic plaques were hypointense on T_1WI while active plaques were isointense on T_1WI [11-14].

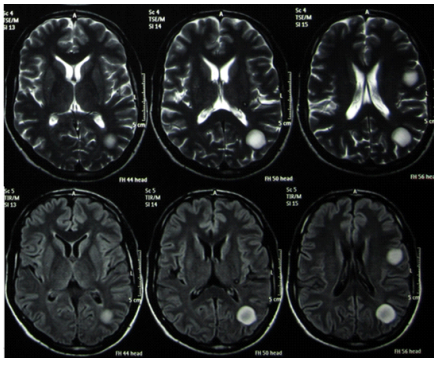

Figure 2: A case of Acute demyelinating encephalomyelitis showing multiple rounded T2Whyperintense lesions in the deep/subcortical white matter appearing hyperintense on FLAIR sequence, showing no perilesional mass effect.

In patients with Acute Demyelinating Encephalomyelitis (ADEM), the common clinical presentation was of seizures with weakness preceded by a history of viral prodrome. Along with white matter, involvement of deep gray matter greatly increased the specificity of ADEM [15-20].

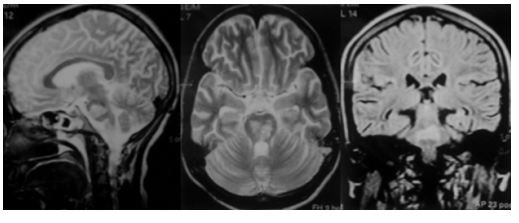

Figure 3: T2W sagittal, axial and coronal images in a case of central pontine myelinolysis, showing hyperintensity in the pons with sparing of peripheral subpial white matter.

Central pontine myelinolysis in our study was characterized by involvement of central pons with sparing of peripheral pial and ventricular surface, with extrapontine involvement and T2 hyperintensity of thalamus [12, 21-23].

Periventricular leukomalacia, in our study occurred in a preterm infant with perinatal asphyxia, presenting characteristically as spastic diplegia. MRI findings showed periventricular white matter hyperintensities with white matter volume reduction and scalloping of the ventricular surface[17, 24-27].

Subacute combined degeneration was characterized by hyperintensity involving posterior as well as anterior columns of cervicothoracic spinal cord on T_2WI [24-26].

In HIV positive patients, chronic illness and history of dementia with MRI findings of multiple lesions involving the periventricular and deep white matter with associated atrophy helped in differentiating it from progressive multifocal encephalopathy [28,29].

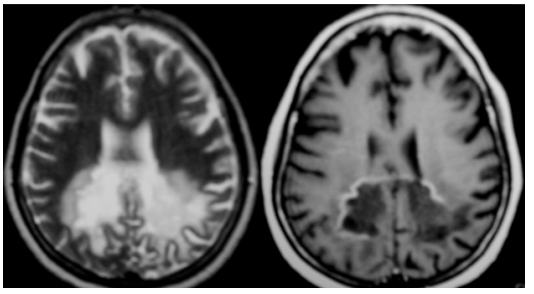

Figure 4: In a paediatric case of adrenoleukodystrophy, bilaterally parieto occipital white matter hyperintensities are seen on T2W images, showing peripheral enhancement on the T1W post contrast images.

Hurler's disease was diagnosed by clinical presentation of patient with skeletal manifestations and supported by MRI findings of atrophy and focal white matter hyperintensity on T_2WI. Involvement of parieto-occipital white matter and splenium of corpus callosum with peripheral rim enhancement was characteristic of Adrenoleukodystrophy [27-30].

Conclusion: In our study, we observed that a correct diagnosis could be made in majority of the patients based on MR findings and clinical history alone. Confirmation by brain biopsy thus is not essential in all patients except in indeterminate conditions. We thus conclude that MR, in conjunction with clinical findings, played a significant role in establishing the diagnosis and in the further follow up of patients with white matter diseases.

References:

1. Alias D. Gean-marton, L. Gilbert Vezina, Keith I. Marton, Gary K. Stimac, Robert G. Peyster, Juan M. Taveras et all. Abnormal Corpus Callosum: A sensitive and specific indicator of Multiple Sclerosis. Radiology 1991; 180:215-221.
2. Ashikaqa R, Araki Y, Ishida O. MR FLAIR imaging of herpes simplex encephalitis. Radiat Med 1996; 14(6): 349-352.
3. Barkhof F., Filippi M, J.H.T.M.van Waesberghe, A Campi, D.H.Miller, H.J.Ader. Interobserver agreement for diagnostic MRI criteria in suspected multiple sclerosis. Neuroradiology 1999; 41:347-350
4. Barkovich James A. MR of the Normal Neonatal Brain: Assessment of Deep structures. Am J Neuroradiology 1998; 19:1397-1403
5. Barkovich James A. Concepts of Myelin and Myelination in Neuroradiology. Am J Neuroradiology. 2000; 21:1099-1109
6. Barkovich James A, Gilles Lyon and Phillippe Evrard. Formation, Maturation and Disorders of White matter. American J of Neuroradiology. 1992; 13:447-461
7. Barkhof F, Filippi M, Miller DH, et al: Comparison of MRI criteria at first presentation to predict conversion to clinically definite multiple sclerosis. Brain 1997 Nov; 120(Pt 11): 2059-69
8. Bassi S S, Bulundwe K K, Greeff G P, Labuscangne J H, Gledhill R F MRI of the spinal cord in myelopathy complicating vitamin B12 deficiency: two additional cases and review of the literature. Neuroradiology 1999; 41:271-274.
9. Blake Johnson. Practical approach to white matter disease. MRI from head to toe-2002:1-4
10. Bot J C, Frederik Barkhof, Geert Lycklama, Dirkjan van Schaardenburg, Alexandre E Voskuyl, Herman J Ader et al. Differentiation of Multiple Sclerosis from other inflammatory disorders and Cerebrovascular Disease: value of spinal MR imaging. Radiology 2002; 223:46-56.
11. Brex P A, J I Riordan, K A Miszkiel, L F Mosoley, A J Thompson, G T Plant, D H Miller. Multisequence MRI in clinically isolated syndromes and the early development of MS. Neurology; 1999:53:1184-1190.
12. Burneo J, Vizcarra D, Miranda H. Central pontine myelinolysis and pregnancy: a case report and review of literature Rev Neurol. 2000 Jun 1-15; 30(11):1036-40.
13. BN Lakhkar, M Aggarwal, JR John MRI in White Matter Diseases – Clinico Radiological Correlation Ind J Radiol Imag 2002 12:1:43-50
14. Campi A, Filippi A, Comi G, Scotti G, Gerevini A, Dousset N Magneisation transfer

VOLUME-6 | ISSUE-1 | JANUARY-2017 • ISSN No 2277 - 8179 | IF : 3.508 | IC Value : 78.46

ratios of contrast enhancing and nonenhancing lesions in multiple sclerosis. Neuroradiology 1996; 38:115-119.
15. Cheon Fung Eun, In-one Kim, Yong Seung Hwang, Ki Foong Kim, Kyu-Chang Wang, Byung-Kyu Cho et all. Leukodystropphy in children-a pictorial review of MR imaging features. Radiographics 2002; 22:461-476.
16. Chopra JS, Radhakrishnan K, Sawhney BB, Pal SR, Banerjee AK. Multiple sclerosis in India. Acta Neurol Scand 1980; 62: 312-321.
17. Christophe C, Johanson A, Massez A, Ziereisen F, Avni F Importance of echocardiography and MRI in periventricular leukomalacia Rev Med Brux. 2003 Jun;24(3):154-61
18. Chua GC, Sitoh YY, Lim CC, Chua HC, Ng PY. MRI findings in osmotic myelinolysis Clin Radiol. 2002 Sep; 57(9): 800-6
19. Coban O, Bahar S, G Akman-Demir, B Taser, S Yurdakul, H Yazici, P Serdaroglu Masked assessment of MRI findings: is it possible to differentiate neuro-Benchet's disease from other central nervous system. Neuroradiology 1999 41:255-260.
20. Daiel A Finelli, Greg C Hurst, Philip Amantia, Rao P Gulapali, Anthony Apicella. Cerebral white matter: technical development and clinical applications of effective magnetization transfer power concepts for high power thing section, quantiatative MT examination. Radiology 1996; 199:219-226.
21. De Stefano N, Narayanan S, Francis GS, et al: Evidence of axonal damage in the early stages of multiple sclerosis and its relevance to disability. Arch Neurol 2001 Jan; 58(1): 65-70
22. Demaeral P, Faubert C, Wilms G. MR findings in leukodystrophy. Neuroradiology 1991; 33: 368-371.
23. Dominques RB, Fink MC, Tsanaclis AM et al. Diagnosis of herpes simplex encephalitis by magnetic resonance imaging and polymerase chain reaction assay of cerebrospinal fluid. J Neurol Sci 1998; 157 (2): 148-153.
24. Elisabeth Bergers, Frederik Barkhof. Multiple Sclerosis. Neuroradiology 2002; 235-246.
25. Fazekas F, Offenbacher H, Fuchs S, et al: Criteria for an increased specificity of MRI interpretation in elderly subjects with suspected multiple sclerosis. Neurology 1988 Dec; 38(12): 1822-5
26. Francis GS, Evans AC, Arnold DL. Neuroimaging in multiple sclerosis. Neurologic Clinics 1995; 13(1): 147-171.
27. Glasier C M, Mark B R, Patrica C D, Elizenda C, and Stephen R B. Clinical, Neurodiagnostic, and MR findings in Children with Spinal and Brain Stem Multiple Sclerosis. American J of Neuroradiology.1995 16;87-95.
28. Gary S Gronseth and Eric J Ashman. Practice parameter: the usefulness of evoked potentials in identifying clinically silent lesions in patients with suspected multiple sclerosis (an evidence based review). Neurology 2000;54:1720-1725.
29. Grossman Robert I and Joseph C McGowan. Perspectives on Multiple Sclerosis. American J of Neuroradiology. 1998;1251-1264.
30. Hans-Peter Hartung, Robert I Grossman.ADEM: Distinct disease or part of the MS spectrum? Neurology 2001; 56:1257-1260.