Original Research Paper

Volume : 5 | Issue : 9 | September 2016 • ISSN No 2277 - 8179 | IF : 3.508 | IC Value : 69.48

Expression of p16 in ASCUS/ASCH Smears and Their Biopsies

Medical Science

KEYWORDS : ASCUS,ASCH, CIN

*** Dr.Neha Tyagi**	Senior Resident, Department of Pathology VMMC and Safdarjung Hospital New Delhi * Corresponding Author
Dr.Anuradha Kusum	Professor, Department of Pathology, Himalayan Institute of Medical Sciences ,HIHT University, Dehradun, Uttarakhand
Dr.Dushyant Singh Gaur	Professor, Department of Pathology, Himalayan Institute of Medical Sciences ,HIHT University, Dehradun, Uttarakhand
Dr. Meena Harsh	Professor, Department of Pathology, Himalayan Institute of Medical Sciences ,HIHT University, Dehradun, Uttarakhand

ABSTRACT

Introduction

Cervical cancer is the second most common cancer among women worldwide. Screening with Pap smear has dramatically reduced the incidence of cervical cancer despite its limitations. In recent years various biomarkers are used for efficient triage of mildly abnormal pap cytologic results. Most intensely studied marker is p16 protein which is overexpressed in dysplastic cervical lesions.

Aims and objective

To determine the pattern of epithelial cell abnormality on pap smear and the utility of p16 immunostaining for predicting CIN II in pap smear specimen with ASC-US /ASC-H and in their biopsies.

Material and methods

Standard techniques were used for processing and morphological study of pap smears over a 12 month period.Smears reported as ASCUS/ ASCH and their corresponding biopsies wherever available were immunostained with Monoclonal p16 antibody (Biogenex Limited).Scoring of p16 positive cells was done.

Results

The study included 515 pap smears with maximum cases in 31-40 years age group. Vaginal discharge was the most common complain and erosion seen in per speculum examination in maximum cases. NILM was found in 88.44% cases.ASCUS was the most common epithelial cell abnormality.p16 immunostain showed high grade positivity in biopsies of ASCH than ASCUS.

Conclusion

This study highlights that women aged 45 years or above harbour the bulk of premalignant and malignant lesions in pap smears probably because of lack of knowledge of screening programme. For mildly abnormal pap results, such as ASCUS/ASCH ,p16 immunostain may be useful for predicting CIN II. With increasing severity of CIN, p16 expression increased progressively.

Introduction

Carcinoma of the cervix uteri is an important cause of morbidity and mortality amongst women especially in developing countries. Cervical cancer ranks seventh in overall frequency, but the second most common cancer among women worldwide.[1] In India, cervical cancer is most frequent cancer among females between 15 and 44 years of age. Current estimates indicate that every year 132,082 women are diagnosed with cervical cancer and that 74,118 die from this disease in India alone. Having said this, however, no form of cancer better documents the remarkable effects of prevention, early diagnosis and curative therapy on the mortality rate than does cancer cervix.[2]

Screening with pap smear has been seen to dramatically reduce the incidence of invasive cervical cancer in different countries of the world.[3] Cervical epithelial cell abnormalities in the Pap smear represent a spectrum of intraepithelial lesions that lie along the pathway, from mild to severe dyskaryosis to invasive cancer[4] However, the Pap test is not very accurate due to subjective variation in smear making. This limits the present screening programmes and emphasizes the need for the identification of specific biomarkers for dysplastic epithelial cells to aid in primary screening and lesion diagnosis.[5]

In recent years, various molecular markers have been proposed as potential candidates for the efficient triage of equivocal and mildly abnormal Pap cytologic results. One of the most intensely studied marker is the cellular p16 protein.[5] p16 is a tumor suppressor protein that inhibits CDK4 and CDK6 which phosphorylates pRb.[6] p16 specifically inhibits the formation of cyclin D/CDK4,6 complexes by interacting with CDK4 and 6 which in turn counteracts the activity of pRb by phosphorylation. The pRb regulates the cell cycle at the G1/S restriction point by complexing with and inhibiting the activity of E2F,which serves as a transcription-dependent promoter of cell cycle progression. The E2F-pRb complex dissociates activating E2F,which in turn initiates the transcription of genes required for DNA replication.[7] Because this protein is not expressed in the normal cervical epithelium, p16 over expression allows to specifically identify dysplastic lesions and reduces interobserver disagreement of conventional histological or cytological tests.[2]

Standardization of pap smear reporting by the use of the revised Bethesda System has unified various overlapping terminologies and has included specific statement regarding specimen adequacy, general categorization, interpretation and results. Hence, we have undertaken this study using the Revised Bethesda system with the intention of finding out the prevalence of epithelial cell abnormality in pap smear of women visiting Gynae OPD of our hospital. As per many previous studies p16 is a good predictors of grade as well as prognosis. Therefore this study is being undertaken to determine the expression of p16 marker in ASC-US and ASC-H cases and its possible benefits in prognosis for patients.

Materials and Methods

An observational descriptive study was carried out in the Department of Pathology, Himalayan Institute of Medical Sciences, Dehradun, India from the months of January 2012 to January 2013 after approval from ethical committee. Detailed history (regarding parity, menstrual history, duration of married life, complaints and recording the findings of per vaginal examination of the patients) was taken. Written informed consent was taken followed by the Pap smear was collection with the help of a wooden Ayer's spatula. Then pap staining was done followed by slide interpretation. A total of 515 smears were examined and reported as per Revised Bethesda System(8).Epithelial cell abnormality was detected in a total of 57 patients. Follow-up biopsies were available in 70 cases and histopathological correlation was done.p16 immunostaining was carried out on ASCUS/ASCH smears and their follow up biopsies using monoclonal mouse antibody of Biogenex limited. Immunostaining for p16 was done using Citrate buffer epitope retrieval method with Avidin-Biotin-Peroxidase complex method. One uterine cervix squamous cell carcinoma with diffuse and strong immunoreactivity with p16 was used as a positive control.Two independent pathologist carried out a semiquantification of the p16 immunostaining with both the staining intensity (0- no staining;1-weak staining intensity;2-intermediate staining intensity and 3-strong staining intensity) and the percentage of positively stained tumor cells(0-no positive cells; 1-<25%;2-26 to 50%;3-51 to 75%;4-76 to 99% and 5-100% positive tumor cells). After multiplication of both values, the immunostaining results were graded from 0(no reactivity in tumor cells) to 15 (100% positive tumor cells with strong staining intensity). [7] Scoring of 0 to 15 was divided into mild (0-4),moderate(5-9) and strong (10-15) grades for analysis of data.

Results

There were 515 smears screened during the study period. Out of these 493 smears (95.72%) were satisfactory for opinion and were further evaluated. There were 287 (55.73%) patients from reproductive age group i.e 21 to 50 years. Maximum number of cases were in 21-30 age group i.e 168(32.62%).Most common complaint was vaginal discharge seen in 332 cases (64.49%), followed by irregular bleeding in 73 cases (14.19%).On per speculum examination cervical erosion was seen in 171 (33.20%) , normal cervix in 157(30.49%), bleeding in 50(9.70%), discharge in 34(6.60%) and suspicious in 24 cases (4.67%). Out of 493 smears, 436 (88.44%) were categorized as NILM (Negative for Intraepithelial lesion or Malignancy) and 57 (11.56%) had Epithelial cell abnormality. Further analysis of pap smears was done as per Revised Bethesda 2001 System (Table 1).

Table 1: Cytomorphology of Adequate smears as per Revised Bethesda 2001 (n=493)

Category	Number	Percentage
NILM	436	88.43%
ASCUS	20	4.06%
ASCH	12	2.43%
LSIL	08	1.62%
HSIL	05	1.01%
AGC	07	1.41%
SCC	03	0.62%
Adenocarcinoma	02	0.42%
Total	493	100%

On further categorisation 436 smears reported as NILM, 377(86.46%) were RCC with inflammation, 32(7.34%) were atrophic, 15(3.45%) showed radiational changes, bacterial vaginosis in 11(2.52%) and only 1(0.23%) patient had candida infection. The most frequent epithelial cell abnormality was ASCUS.Age wise distribution showed highest incidence of ASCUS (42.85%) in 4th decade and LSIL (28.57%) in 3rd decade, However ASCH, HSIL,AGC, SCC and Adenocarcinoma were more common after 5th decade. Epithelial cell abnormality showed significant results according to parity (Table 2).

Table 2: Distribution of Epithelial cell abnormalities according to Parity

Parity	Number of patients with ECA	ASC-US	ASC-H	LSIL	HSIL	AGC	SCC	Adeno-carcinoma
Nulliparous	01	0	0	01(100%)	0	0	0	0
Para 1	06	03(50%)	0	01(16.66%)	01(16.66%)	01(16.66%)	0	0
Para 2	21	07(33.33%)	04(19.04%)	05(23.81%)	0	02(9.52%)	0	0
Para 3 and above	29	10(34.48%)	08(27.58%)	01(3.44%)	04(13.79%)	04(13.79%)	03(10.34%)	02(6.89%)
Total	57	20	12	08	05	07	03	02

Out of 515 cytology cases subsequent biopsies were available in 70 cases. Out of 22 inadequate cytology smears biopsy was done in 2 cases, in 35 cases out of 436 NILM smears, 12 out of 20 ASCUS smears, 10 out of 12 ASCH smears, 4 out of 7 AGC smears, 2 out of 3 SCC smears and 1 out of 2 adenocarcinoma smears. Histo-cyto correlation of ASCUS and ASCH smears is as shown in Table 3.p16 staining scoring on follow-up biopsies was done and results are shown in Tables 4 and 5.

Table 3: Histo correlation of ASCUS/ASCH cyto smears

Cyto Δ Histo Δ	ASCUS	ASCH
LSIL	09(75%)	0
HSIL	01(8.33%)	03(30%)
CIS	01(8.33%)	02(20%)
SCC	00	03(30%)
Adenocarcinoma	01(8.33%	02(20%)
Total	12	10

Table 4: p16 scoring on follow up biopsies of ASCUS cases (n=12)

Histological diagnosis	Number of cases	Mild (1-4)	Moderate (5-9)	Strong (10-15)
LSIL	09	09 (100%)	0	0
HSIL	01	0	01(100%)	0
CIS	01	0	0	01(100%)
Adenocarcinoma	01	0	0	01(100%)
Total	12			

Volume : 5 | Issue : 9 | September 2016 • ISSN No 2277 - 8179 | IF : 3.508 | IC Value : 69.48

Table 5: p16 scoring of follow up biopsies of ASCH smears (n=10)

Histological diagnosis	Number of cases	Mild (1-4)	Moderate (5-9)	Strong (10-15)
LSIL	0	0	0	0
HSIL	03	01(33.33%)	0	02(66.67%)
CIS	02	0	0	02(100%)
Adenocarcinoma	02	0	01(50%)	01(50%)
SCC	03	0	0	03(100%)
Total	10			

Discussion

Till date there are no published data from Uttarakhand concerning the pattern of epithelial cell abnormality in pap smear. In this study, we have applied the Revised Bethesda System, which will obviously, to some extent, provide an idea about the overall picture of epithelial cell abnormality in the pap smear cytology of a developing country.

In the present study 515 cervical pap smear were studied from March 2012 to March 2013 after detailed history. The Revised Bethesda system 2001 was used for reporting. Whenever available, histopathological examination with correlation to the cytological examination was done.

1.Photomicrograph 1 ASCUS smear (p16 immunostain) – Negative

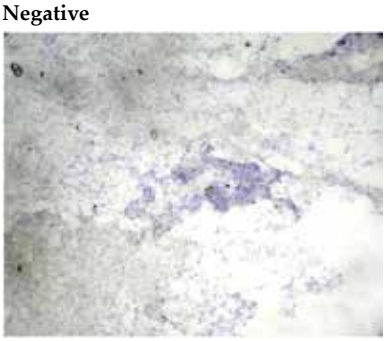

2. Photomicrograph 2 LSIL (p16 immunostain IRS 4;200X)



3. Photomicrograph 3 HSIL(p16 immunostain IRS 12;200X

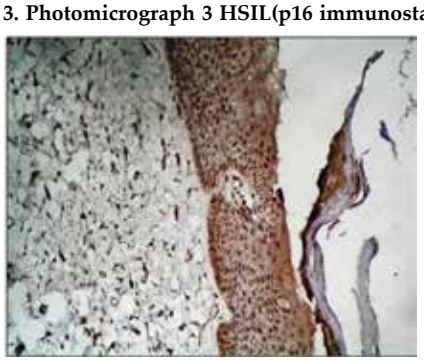

4. Photomicrograph 4 SCC(p16 immunostain IRS 15;100X)

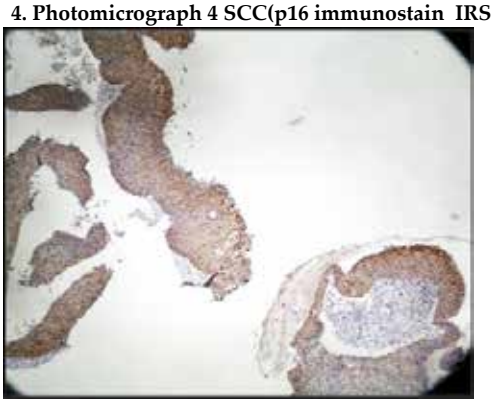

5. Photomicrograph 5 Adenocarcinoma(p16 immunostain IRS 15;200X)

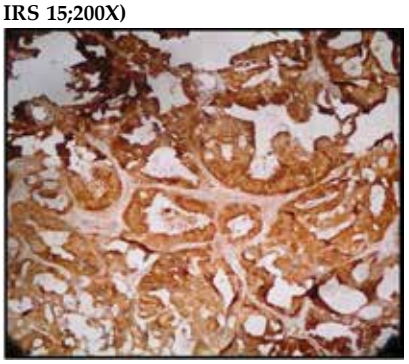

In the present study, out of 515 cases maximum number of patients (168,32.62%) were in 31- 40 year age group, followed by 119(23.10%).cases in 41 -50 year age group with a mean age of 42 years.Our findings were similar to the study by Dhiraj et al and Shrivastava et al with 36.50% and 36.76% cases in 31-40 year age group respectively. [9,10] This suggests that Pap testing is delayed in many women in our setup. This is primarily attributed to lack of education and awareness about good health, especially in female sector of our society.

Most common complain our study was vaginal discharge (350, 67.97%) similar to study done by Shrivastava et al (35%) and Dhruva et al (46.5%).[10,11] This may be because of poor genital hygiene.The present study had 4.28% of unsatisfactory smears which was similar to study by Misra et al(8.1%) and Mulay et al(15.6%) respectively.[12,13]The number could have been on the lower side if Thin Prep or Liqui prep techniques were used instead of conventional smears.

As per Revised Bethesda Classification 2001, 436(88.43%) were NILM, 20 (4.06%) were ASCUS, 12(2.43%) were ASCH, 8(1.62%) LSIL, 5(1.01%) HSIL, 7 (1.41%) AGC, 3 (0.62%) SCC and 2 (0.42%) were Adenocarcinomas. Similar findings were seen in the study done by Shrivastava et al who reported NILM in 81.44%, ASCUS in 4.96%, AGUS in 1.72%, LSIL in 7.36%, HSIL in 3.52% and SCC in 1.60% (10).Ghazal Aswad et al reported 95% NILM, 2.9% ASCUS, 1.1% LSIL, 0.9% HSIL and no cases of SCC and Adenocarcinoma in their study.[14]

In study by Urmila Banik et al the following scenario was revealed: 0.18%ASCUS, 0.12% AGC, 6.36% LSIL, 1.18% HSIL and 0.35% malignancy.[3] Dhiraj et al revealed 5.8% epithelial cell abnormality in their study with 0.96% ASCUS, 0.96%LSIL, 1.98% HSIL,0.40% AGC and 1.60% SCC cases.[9] In the present study there were

57 samples (11.56%) reported as having epithelial cell abnormality. Out of these samples,20 (35.08%) smears were ASCUS, 12 (21.05%) were ASCH,8 (14.04%) were LSIL,5 (8.78%) were HSIL,AGC in 7 (12.29%),SCC in 3 (5.25%) and Adenocarcinoma in 2 (3.50%) samples. One of the significant disconcordance between our study and the previously published data from other countries is the slightly higher rate of ASCUS and lower rate of LSIL. We assume that as the women included in our study were routinely screened, they presented with borderline changes that fell short of definitive SIL interpretation in the cervical smear and thus ASCUS was higher. Most probable reason for the disconcordance with the studies quoted may be due to the fact that the criteria for ASCUS might differ subtly among laboratories due to technical differences in the slide preparation.[3]

Menon Devi et al had found that incidence of dysplasia increased with parity.[15] Present study showed concordance with the above study. Majority of patients in our study had 2 children(201,39.02%) and high parity(children 3 and above) was associated with higher occurrence of ASCUS(4.78%), ASC-H(3.82), HSIL(1.91%), AGC(1.91%),SCC (1.43%) and Adenocarcinoma (0.9%). This might be due to the events related to the second and third trimesters of pregnancy such as increased hormone levels and impaired immune response. It has also been shown that transformation zone remains on the ectocervix for longer in multiparous women thereby facilitating direct exposure to HPV and potential cofactors.

In our study p16 immunostaining was done on 20 ASCUS and 12 ASCH pap smears. All the 32 smears were negative (photomicrograph 1) Even the positive control which was SCC cervix was found to be negative. A study done by Ming Guo et al on SurePath slides of 78 cases (65 ASCUS and 13 ASCH) who had follow-up biopsy specimens available, showed 47% (37/78) positivity for p16. p16 immunostain showed low sensitivity and specificity and published studies stated that utility of p16 immunostain in pap specimens with ASCUS are controversial.[16]

There were 70 cases in which subsequent biopsy was done and correlation between cytology and histopathology could be established.In present study out of 20 ASCUS and 12 ASCH smears only 22 follow up biopsies (12 ASCUS and 10 ASCH cases) were available. p16 immunostaining was done on these 22 biopsies. 9/12 ASCUS smears were reported as LSIL on histology showed mild p16 immunostain positivity in 100% cases 9/9 (photomicrograph 2) .1/12 ASCUS smears reported as HSIL on histology showed moderate p16 positivity.1/12 ASCUS smears reported as CIS and 1/12 ASCUS smear reported as Adenocarcinoma on histology showed strong p16 positivity.Out of 10 ASCH smears 3 were reported as HSIL on histology.1/3 (33.33%) HSIL showed mild p16 positivity and 2/3(66.67%) showed strong p16 positivity (photomicrograph 3) cases reported as CIS showed strong p16 immunostain.1/2 cases reported as adenocarcinoma 1(50%) showed moderate p16 positivity and 1(50%) showed strong (photomicrograph 5) cases reported as SCC on histology, 3/3(100%) showed strong p16 (photomicrograph 4). A Study by Klaes and associates showed p16 (INK4a) protein overexpression in all cases of CIN 2 (n = 32) and CIN 3 (n = 60), as well as 58 of 60 (97%) invasive cervical carcinomas. As such, these results suggest that overexpression of p16 (INK4a) assists in the identification of high-risk HPV-related cervical squamous lesions.[17]

Conclusion

In the present study pattern of epithelial cell abnormality was studied on pap smear and also expression of p16 in ASCUS/ASCH smears and their biopsies. ASCUS was found to be most common epithelial cell abnormality. It was found that epithelial cell abnormality was associated with high parity.Expression of p16 was not of much help on conventional pap smears. However, on subsequent biopsies expression of p16 was found to be increased with increasing severity of cervical disease. It was also seen to be expressed in glandular cells as well. The utility of p16 immunostain as a predictive marker for CIN II in pap smears of ASCUS and ASCH cases could not be established due to small sample size in these groups.

ACKNOWLEDGEMENTS

None

DISCLOSURES

None

CONFLICT OF INTEREST

None

References

1. Mehmetoglu HC, Sadikoglu G, Ozcakir A, Bilgel N. Pap smear screening in the primary health care setting: A study from Turkey. North Am J Med Sci 2010; 2: 468-72.
2. Supriya Srivastava. An immunohistochemical expression in preneoplasia and neoplasia of the cervix. Indian Journal of Pathology and Microbiology 2010; 53 : 518-24.
3. Urmila Banik, Pradip Bhattacharjee et al.Pattern of epithelial cell abnormality in pap smear: A Clinicopathological and demographic correlation. Cyto Journal 2011; 8: 8.
4. Toews HA. The abnormal pap smear: A rationale for follow up. Can Fam Physician.1983; 29: 759-62.
5. Karin J Denton. The Sensitivity and specifity of p16 cytology vs HPV Testing for detecting high – grade cervical disease in the triage of ASCUS and LSIL Pap cytology Results. Am J Clin Patho 2010; 134: 12-21.
6. Cho NH, Kim YT, Kim JW. Alteration of cell cycle in cervical tumor associated with human papillomavirus: cyclin-dependent kinase inhibitors. Younsie Med J 2002;43:722-28.
7. Nabiha Missaoui. p16INK4A overexpression and HPV infection in uterine cervix adenocarcinoma. Virchows Arch 2006; 448: 597-603.
8. Nayar R, Solomon D.The Bethesda System for Reporting Cervical Cytology.2nd ed.USA; Springer;2004.pp 21-2.
9. Dhiraj B Nikumbh, RD Nikumbh, VD Dombale, S V Jagtap, SR Desai. **Cervicovaginal Cytology: Clinicopathological and Social Aspect of Cervical Cancer Screening in Rural (Maharashtra) India. International Journal of Health Sciences and Research. 2011; 1: 21-7.**
10. Shrivastava M, Shrivastava O P, Jaiswal S S. Pattern of Cervical Smear Cytology in Rural Medical College. Pravara Med Rev. 2011;6 : 12-7.
11. Dhruva GA, Agravat AH, Bhojani KR. Analysis of cervical cancer in Rajkot population. Electronic Journal of Pharmacology and Therapy.2011; 4: 15-20.
12. Misra JS, Srivastava S, Singh U, Srivastava AN. Risk's factors and strategies for control of carcinoma cervix in India: Hospital based cytological screening experience of 35 years. Indian Journal of Cancer. 2009; 46 : 155-9.
13. Mulay K, Swain M, Patra S, Gowrisshanker S. A comparative study of cervical smears in an urban hospital in India and a population-based screening program in Mauritius. Indian Journal of Pathology and Microbiology. 2009; 52 : 34-7.
14. Ghazal-Aswad S, Gargash H, Badrinath P. Cervical smear abnormalities in the United Arab Emirates. A pilot study in the Arabian Gulf. Acta Cytologica. 2006; 50: 41-97.
15. Menon KMK, Devi PK, Rao KB. Post graduate obstetrics and gynecol-

Volume : 5 | Issue : 9 | September 2016 • ISSN No 2277 - 8179 | IF : 3.508 | IC Value : 69.48

ogy. 3rd ed. Longman Ltd ; 1986. pp 287.

16. Ming Guo, Irfan Warriage, Bramara Mutyala, Shobha Patel, E. Lin, Yun Gong, et al. Evaluation of p16 Immunostaining to Predict High-Grade Cervical Intraepithelial Neoplasia in Women with Pap Results of Atypical Squamous Cells of Undetermined Significance. Diagnostic Cytopathology. 2010; 39 : 482-7.
17. Klaes R, Friedrich T, Spitkovsky D. Overexpression of p16 (INK4A) as a specific marker for dysplastic and neoplastic epithelial cells of the cervix uteri. Int J Cancer. 2001; 92: 276-84.