VOLUME-6 | ISSUE-2 | FEBRUARY-2017 • ISSN No 2277 - 8179 | IF : 3.508 | IC Value : 78.46

Extranodal Castleman's Disease Of the Extremities: a case report .

Pathology

KEYWORDS: Castleman's disease, lymphadenopathy, extranodal.

DR.BHARTI DEVI THAKER — SENIOR RESIDENT, DEPATMENT OF PATHOLOGY GMC JAMMU.

DR.SUBHASH BHARDWAJ — ASSOCIATE PROFESSOR ,DEPARTMENT OF PATHOLOGY GMC JAMMU.

ABSTRACT

Castleman's disease is a rare lymphoproliferative disorder of unknown etiology with two identified forms, the hyaline vascular type and the plasma cell type. It usually presents as localized or generalized lymphadenopathy or rarely as an extra nodal mass and may give rise to different differential diagnosis. It is uncommon for castleman's disease to present in the extremities.We report a rare case of extranodal castleman's disease presenting as a soft tissue mass in back of right thigh.

Introduction

Between 1954 and 1956, Benjamin Castleman(1,2) reported a series of 13 unusual patients with enlarged mediastinal lymph nodes resembling,and erroneously classified as thymoma. Castleman eloquently described the histological distinction of these tumours from other lymphoproliferative disorders (2) and neoplasms . Since this original description,the lymphoproliferative disorder now known as Castleman disease(CD)has been called follicular lymphoreticuloma, giant lymph node hyperplasia, angiomatous lymphoid hamartoma and Angiofollicular lymph node hyperplasia(3).Castleman disease is a rare benign disorder and may present as nodal or extranodal mass .Microscopically two distinct histological patterns have been described, the hyaline vascular(HV)type and plasma cell type(PC)(4).Here we present a case of castleman hyaline vascular type involving back of right thigh in a 18 year old male.

CASE REPORT

An 18 year old male presented with a history of soft tissue mass in the right side back of thigh, gradually increasing since 6 months. On examination the mass measured 10x8 x 2cm,was firm and non tender .Routine laboratory investigations showed no abnormality .There were no systemic symptoms, draining lymph nodes were not enlarged and no other organomegaly was found. Fine needle aspiration cytology was done and smear were found cellular showing mixed population of small and large lymphoid cells with prominent vascularity and hyalinized capillaries. No epitheliod cells, giant cells or necrosis was seen. A presumptive diagnosis of castleman's disease was made and excision was advised. Then we received soft tissue mass after surgical excision. On gross the soft tissue mass was of size 8x6x2 cm, well circumscribed and grey white. Necrosis was not seen. On microscopy sections showed skeletal muscle fragments within which were present many hyperplastic follicles of variable size,some of which were vascularized and had amorphous eosinophilic material. Parafollicular zone contained branching capillaries,mature lymphocytes and plasma cells.These findings confirmed the castleman disease hyaline vascular type .

Discussion

Castleman disease is a well recognized entity, uncommonly seen in the extremities. This patient presented with a soft tissue mass which displayed the gross and histopathological features typical of hyaline vascular type(HVCD).When extranodal castleman disease occurs it is almost always seen in the mediastinum or retroperitoneum(5,6). Other locations of exranodal castlemans disease reported in literature include vulva,nasopharynx,larynx and pancreas(7,8). Castleman disease presenting as an isolated soft tissue mass in the extremities is extremely uncommon. There have been only few cases reported in the literature. The mean age of the previously reported cases was 18 years, range from 15 months to 29 years. Mostlly patients were females and the majority cases were involving lower extremity as compared to upper extremity(9). Microscopically as stated above two distinct histological forms have been described— Hyaline vascular or angiofollicular type and plasma cell(PC)type. However depending on the clinical presentation they can be divided into solitary or localized and multicentric or systemic type.More than 90% of the solitary type is HV disease and almost all of the multicentric is histologically PC type.

However multicentric HV has also been reported. Microscopically, the characterstic features are increased number of scatterd large follicles, many of which with hyalinization and marked vascular proliferation oftheir germinal centers. The interfollicular area shows marked proliferation of postcapillary venules.

The treatment for localized castlemans disease is surgical resection,which is usually curative(10).so a correct diagnosis earlier in the course of clinical evaluation is important.Additionaly it is also important to recognize castlemans disease early as it has tendency to get transformed into follicular dendritic cell sarcoma.

In summary, extranodal castlemans disease can be a challenging diagnosis to make esspecially when it presents in an unusual location. This case report is being presented for its rarity and it is hoped that this report will stimulate the consideration of castlemans disease when atypical soft tissue masses of the extremities are encountered.



Gross photograph of the excised specimen containing skeltal muscle along with the lesion

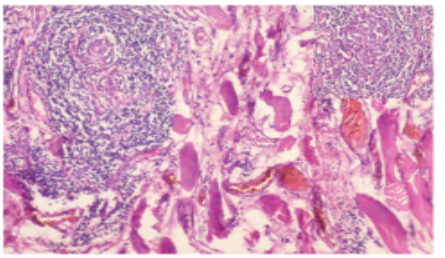

Photomicrograph showing skeltal muscle fragments within which are present lymphoid follicles with prominent germinal centers. showing Hyalinized Capillaries with plump endothelial cells. (H&E) (40x)

References

1. Castleman B, Towne VW. Case records ofthe Massachusetts general hospital;case no.40231. N EnglJ 1954:250;1001—05.
2. Castleman B, lverson L,Menendez VP. Localized mediastinal lymph node hyperplasia resembling thymoma. Cancer 1956; 92822-30.
3. Olscamp G,Weisbrod G,Sanders D,Delarue N,Mustard R.Castleman disease:unusual manifestation of an unusual disorder.Radiology 1980:135(1):43—48.
4. Rosai J. Lymph NODES.ln :Rosai J,editor.Ackermans Surgical Pathology.9th ed.St.Louis: Mosby;2003.p1877-2017.
5. Frizzera G.Castlemans disease:More questions than answers.Hum Pathol 1985;16:201—05.
6. Shahidi H,Myers JL, Kvale PA. Castlemans disease Mayo clin proc1995;70:969-77.
7. TD VW, G A ,T YD.Rare case of castlemans disease involving pancreas.Am Surg 2007;73(12):1284-87.
8. Chen TC, Kuot. Castlemans disease presenting as a pedunculated nasopharyngeal tumour simulating angiofibroma.Histopathology1993;23:485-88.
9. Kernen JA, Morgan ML. Benign lymphoid hamartoma of vulva.A case report. Obstet Gynaecol 1970;35:290-92.
10. Keller AR, Hochhholzer L, Castleman b. Hyaline vascular and plasma cell types giant lymph node hyperplasias ofthe mediastinum and other locations.Cancer 1972;29:670-83.