Research Paper

Volume : 4 | Issue : 3 | March 2015 • ISSN No 2277 - 8179

EXTRAPULMONARY TUBERCULOSIS- A HISTOPATHOLOGAL STUDY.

Medical Science

KEYWORDS : Extra pulmonary tuberculosis, histopathology, ZN staining, granuloma, lymphadenopathy.

DR. QADIR FATIMA	ASSOCIATE PROF, DEPT OF PATHOLOGY, SPMC, BIKANER
DR. RASHMI JAIN	M.O SATTELITE HOSPITAL BIKANER
DR. SHARANBASU	RESIDENT, DEPT OF MEDICINE, SPMC BIKANER
DR. LA GAURI	SENIOR PROF AND UNIT HEAD, DEPT OF MEDICINE, SPMC BIKANER.

ABSTRACT

Tuberculosis is a chronic granulomatous disease caused by tubercle bacillus or Koch's bacillus. Out of various pathogenic strains for human disease, mycobacterial tuberculosis hominis (human strain) is responsible for most cases M. tuberculosis bovis is another pathogen which causes infection due to consumption of unpasteurized milk but presently constitutes a small number of human cases.6,7,8

Pulmonary TB is a major public health problem, but extra pulmonary TB represents another extra burden in developing countries.Tuberculosis that affects any site/organ outside lung parenchyma K/a extra pulmonary tuberculosis (EPTB).

(i) Tubercular lymphadenitis
(ii) Pleural TB
(iii) Osteoskeletal TB
(iv) Abdominal TB
(v) Genitourinary TB
(vi) TB of pericardium
(vii) Severe form of EPTB (Disseminated TB & tubercular meningitis)
(viii) Other rarer forms of EPTB

Conventional ZN staining for AFB demonstration has several limitation and is often unhelpful in establishing the diagnosis of EPTB. Histopathology remains one of most important methods for diagnosis of EPTB and in a high TB prevalent area HPE is the reliable and a gold standard.

Introduction:

Tuberculosis (TB) is a public health problem worldwide; it is second deadliest disease in world.1 Extra pulmonary TB comprises 15-20% of all cases of TB in immuno competent patients and accounts for more than 50% in HIV infected patients. It affects females more commonly than males.9,2,10,11

Lymph node is the m.c. site of involvement in various EPTB lesions in our country followed by pleura and virtually any site of body can be affected. 9,10,11,12,13,14,15

Although conventional microscopy & culture of organism are cornerstone methods for diagnosis of TB, but diagnosis of EPTB still faces many challenges due to its wide spectrum of clinical presentation and low sensitivity of these traditional methods in paucibacillary samples of EPTB cases and culture of organism is too much time consuming.13,3,6

Histopathology remains one of important method for diagnosis but it also depends upon bacillary load of specimen material.3

The present study was conducted to investigate the morphological patterns of various EPTB lesions as well as to assess the reliability of conventional Ziehl-Neelsen (ZN) staining in diagnostic yield of EPTB.

Materials and Methods:

The diagnosis of EPTB was made on criteria of well formed epithelioid cell granuloma with or without caseation and demonstration of acid fast bacilli by ZN staining method.

Histopathological Criteria:

Granuloma -ill defined /well defined
Presence/absence of caseation necrosis
Presence/absence of multinucleated giant cell and its type
Presence of surrounding granulomatous inflammation in which inflammatory cells e.g. neutrophils, plasma cells, lymphocytes, histocytes & fibrosis.

Tissue processing :

Specimen were fixed in 10% formalin and subsequently processed as per technique given below. Paraffin sections were then cut and stained by H&E stain:

10% formalin	:	24 hrs fixation
70% alcohol	:	½ hour dehydration
80% alcohol	:	1 hour dehydration
90% alcohol	:	1 hour dehydration
95% alcohol	:	1 hour dehydration
Absolute alcohol	:	1 hour dehydration
Absolute alcohol	:	1 hour dehydration
Xylene	:	1/2 hour cleaning
Xylene	:	1 hour clearing
Paraffin wax	:	2 hour embedding

Section cutting:

Paraffin embedded tissue were blocked in paraffin with the help of moulds

Staining Technique :

Haematoxylin and Eosin (H&E) stain - stain prepration :

Harris haematoxylin -

Prepared as follows :

Haematoxylin	-	2.5gm
Absolute alcohol	-	25 ml
Potassium alum	-	50 gm
Distill water	-	500 ml
Mercuric oxide	-	1.25 gm

Eosin Stain -

Stock 1% aqueous eosin solution :
Eosin. Y, water soluble 10gm,
Distill water - 1000 ml.
Glacial acetic acid -2ml
Working eosin stain;
Eosin 1% stock solution in distill water.

Results :

Nuclei	:	Blue Black
Cytoplasm	:	Pink to Red.
Most other structures	:	Pink to Red.

Conventional ZN staining for tubercle bacilli
Fixation-formalin, section-paraffin
Control - any tissue contain acid fast organism
Reagents -1.Carbol fuchsin 2. Acidified methylene blue

Stain Preparation:
Carbol Fuchsin -
1 gm of basic fuchsin is dissolved in 10ml of absolute alcohol, and 100ml of 5% aqueous phenol solution is added. Mix well; filter before use.

Acidified methylene blue -
0.25% methylene blue in 1% acetic acid.

Staining Procedure :
Method
- Dewax in xylene and hydrate through graded alcohols to water.
- Flood sections with carbol fuchsin & heat by intermittent flaming for 15 minutes.
- Rinse in distill water & differentiate in 1% acid alcohol for 10 minutes.
- Rinse in 25% aqueous sulphuric acid.
- Place in 25% aqueous sulphuric acid for 3 minutes or longer until section is decolorised.
- Wash in running tap water for at least 3 minutes.
- Counterstain lightly in acidified methylene blue for ½ to 1 min.
- Rinse in tap water.
- Dehydrate & continue to differentiate in alcohols till section is pale blue.
- Clear and mount.

Results:
- Acid fast bacilli - red
- Background - pale blue

Results and Discussions:
The index study highlighted the following findings :
- Maximum number of cases were in third decade.
- Mean age was 32.28±17.24 yrs.
- Female were more commonly effected than males, male to female ratio was 7/9 = 0.77.
- Lymph node was most common site of EPTB; followed by abdomen.
- In TB of lymph node cervical lymph node was most frequently involved followed by axillary LN.
- Tubercular lymphadenopathy was also more common in females.
- In TB small gut was most frequently involved followed by terminal ileum
- Mesentric lymph node were also frequently affected in various type of intestinal TB.
- Omentum, liver, spleen were other sites of abdominal TB.
- Genital TB was more common in females as compared to males.
- In skin TB, lupus vulgaris was m.c.
- Histopathologically out of 80 cases of EPTB, caseating granuloma (most specific for TB) was found in 72.5% cases, while AFB demonstration by conventional ZN staining was possible only in 4 cases (5%), while more 2 cases showed weak positivity.
- These AFB were more commonly found in epithelioid cells as compared to other area of granuloma.
- Our results were similar to most other studies in India and abroad except that in our study caseating granuloma (72.5%) were slight higher from other studies and other is abdominal TB which was 2nd m.c. site of EPTB in our study while in other studies pleural or osteoskeletal TB was m.c. site of EPTB after lymph node. In our study only one case of pleural TB was found.

In conclusion, this study yielded some useful information and suggested that although pulmonary TB is a major public health problem, but extra pulmonary TB represents another extra burden in developing countries.

Conventional ZN staining for AFB demonstration has several limitation and is often unhelpful in establishing the diagnosis of EPTB. Histopathology remains one of most important methods for diagnosis of EPTB and in a high TB prevalent area HPE is the reliable and a gold standard.

However, it gives only presumptive evidence of infection because it can't differentiate changes caused by M. tuberculosis, non tubercular mycobactria and other chronic granulomatous disease.

Therefore, for definitive diagnosis a combined approach e.g. history, clinical examination, histopathology, AFB smear/ culture and newer modalitis like PCR and immunohistochemistry (in doubtful cases) should be made.

Tables:

Table 1: Distribution of different EPTB lesions according to site (n=80)

Site	Number	Percentage
Lymph node TB	34	42.5
Abdominal TB	15	18.75
Genito Urinary TB	12	15
Bone & Joint TB	07	8.75
Skin & Subcutaneous Tissue TB	04	5
Tubercular Abscess	03	3.75
Female Breast TB	03	3.75
Pleural TB	01	1.25
Miliary TB	01	1.25

Table 2: Distribution of different EPTB lesions according to gender (n=80)

Gender	Number	Percentage
Male	35	43.75
Female	45	56.25
Total	80	

Table 3: Distribution of different EPTB lesions according to Sex (n=80)

Site	Male	Female	Total	Percentage
Lymph node	09	25	34	42.5
Abdominal	10	05	15	18.75
Genito Urinary	04	08	12	15
Bone & Joint	05	02	07	8.75
Skin & S.C.	02	02	04	5
Tub. Abscess	03	0	03	3.75
Breast	0	03	03	3.75
Pleural	01	0	01	1.25
Miliary	01	0	01	1.25
Total	35	45	80	

Volume : 4 | Issue : 3 | March 2015 • ISSN No 2277 - 8179

Table 4: Age distribution of different EPTB lesions (n=80)

Site	0-10	11-20	21-30	31-40	41-50	51-60	>60	Total
Lymph node	1	12	10	7	1	3	-	34
Abdominal	1	2	3	4	2	2	1	15
GUT	-	2	5	1	2	-	2	12
Bone, Joint	1	2	1	2	-	1	-	7
Skin & S.C.	-	-	2	-	-	-	2	4
Tub. Absc.	-	1	1	-	-	1	-	3
Breast	-	-	1	1	1	-	-	3
Pleural	-	1	-	-	-	-	-	1
Miliary	-	-	-	-	-	-	1	1
Total	3	20	23	15	6	7	6	80

Table 5: Age distribution of different EPTB lesions in male (n=35)

Site	0-10	11-20	21-30	31-40	41-50	51-60	>60	Total
Lymph node	1	2	4	2	-	-	-	9
Abdominal	1	-	1	4	1	2	1	10
GUT	-	-	-	1	1	-	2	4
Bone, Joint	1	2	1	-	-	1	-	5
Skin & S.C.	-	-	1	-	-	-	-	2
Tub. Abscess	-	1	1	-	-	1	1	3
Breast	-	-	-	-	-	-	-	0
Pleural	-	1	-	-	-	-	-	1
Miliary	-	-	-	-	-	-	1	1
Total	3	6	8	7	2	4	5	35

Table 6: Age distribution of different EPTB lesions in females (n=45)

Site	0-10	11-20	21-30	31-40	41-50	51-60	>60	Total
Lymph node	-	10	6	5	1	3	-	25
Abdominal	-	2	2	-	1	-	-	5
GUT	-	2	5	-	1	-	-	8
Bone, Joint	-	-	-	2	-	-	-	2
Skin & S.C.	-	-	1	-	-	-	1	2
Tub. Absc.	-	-	-	-	-	-	-	0
Breast	-	-	1	1	1	-	-	3
Pleural	-	-	-	-	-	-	-	0
Miliary	-	-	-	-	-	-	-	0
Total	0	14	15	8	4	3	1	45

Table 7: Distribution of site in TB lymph node (n=34)

Site	Number	%
Cervical	24	70.58
Axillary	5	14.70
Supraclavicular	3	8.82
Infra-auricular	1	2.94
Inguinal	1	2.94
Total	34	100

Table 8: Distribution of site in TB intestine (n=11)

Site	Number	Percentage
Small gut	6	54.55
Terminal Ileum	3	27.27
Colon	2	18.18
Total	11	100

Table 9: Mean age distribution in different EPTB lesions (n=80)

Site	Number	Minimum age in yr	Max. age in yr.	Mean age in yr.	SD	% of total
Lymph node	34	1	60	27	13.62	42.5
Abdominal	15	9	68	35.67	18.09	18.75
GUT	12	17	68	35.67	16.80	15
Bone & Joint	7	4	55	28.43	17.43	8.75
Skin & S.C.	4	25	72	48.0	23.93	5
Tub. Abscess	3	20	57	35.0	19.47	3.75
Breast	3	30	48	33.33	5.77	3.75
Pleural	1	20	20	20.0	0	1.25
Miliary	1	85	85	85.0	0	1.25
Total	80	01	85	32.28	17.24	100

Table 10: Distribution of histological finding in different EPTB lesions (n=80)

Histological finding	Number	Percentage
Well defined granuloma	68	85
Caseation necrosis	67	83.75
Epithelioid cells	44	55
Caseating granuloma	58	72.5
Giant cells	70	87.5

Table 11: Correlation of histological finding with AFB status in different EPTB lesions (n=80)

Histological finding	AFB positive	AFB negative
Caseating granuloma +nt	3	55
Caseating granuloma –nt	1	21
Total	4	76

Table 12: Rate of AFB demonstration in histological proven TB (n=80)

Histological proven TB sample	80
AFB positive sample	4
% Positivity	5%

Figures:

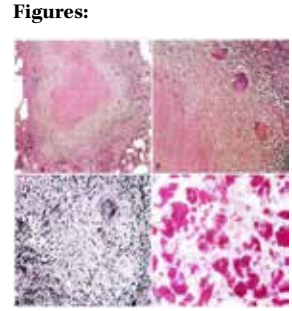

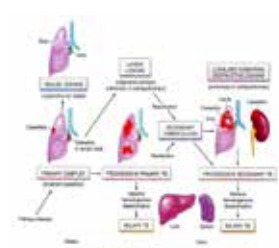

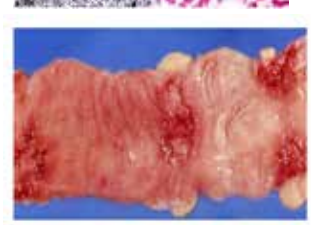

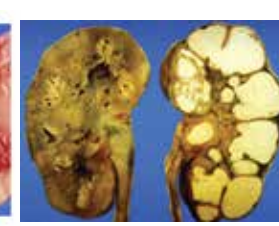

REFERENCE

1. Nancy a. Knechel. Tuberculosis: Pathophysiology, clinical features and diagnosis; April 2009; 29(2): 34-43. | 2. Shafi Ullah, Humayu S, Rehan A, Kamal A, Begum N, Khan G. Extrapulmonary TB in a lady reading Hospital, Peshwar, NWFP, Pakistan J Ayub Med. Coll Abbotabad, 2008; 20 (2) : 43-46. | 3. Kaur Avneet, Ruchi B, Beena J, Singh V, mahajan N.E. Extrapulmonary TB in M.I.M.S.R. Maulana Ambala: A microbiological & Histopathological study, Sept. 2012; 139-142. | 4. Saeed Nadia, Islam A. UL, Hazrat B.B., Nizamuddin S. Clinical Manifestation of extrapulmonary TB, 2012; Vol. 18 (1): 80-83. | 5. Jaylakshmi P, Malik A. K. , SOO H.S., Histopathology of lymph node TB, University Hospital Experience, Malaysian J Patho 1994; 16 (1): 43-47. | 6. Robbins & Cotran – Pathological basis of disease, eight edition, 2012; 366-67. | 7. Harshmohan – Textbook of pathology, sixth edition 2010; 149-152. | 8. Nadia Ait Khalid and Anarson d. Tuberculosis – A Manual for medical students (WHO) 2003; 27-30, 45-50. | 9. Sharma S.K., Mohan A. Extrapulmonary tuberculosis. Indian J Med Res 2004; 120: 316-53. | 10. Hussain M.W. Haque A, Bani A, Ekram S, Rehman F. Extrapulmonary TB. An experience in Rajashahi chest disease clinic and chest disease hospital, Taj June 2004; Vol. 17 (1): 16-19. | 11. Purohit Manju R, Mustafa T., Wicker H.G. et al ng mycobacterial TB complex specific antigen MPT 64 Sept. 2007; 1746-1596-2-36. | 12. Abdurrehman Eshete, Ahmed Zeyindin, Solomen A & Mohammed, Tuberculosis in lymph node biopsy parafin embedded section, Oct. 2011. | 13. Ahmed H.G.E. Nassar AS and Ginawi I, "Screening for tuberculosis and its histological pattern in patients with enalrged lymph node" 2011; Art. ID-417365. | 14. M.P. Golden, H.R. Vikram. Extrapulmonary TB: An overview. Am Fam physician. 2005 Nov. 1; 72 (9): 1761-1768. | 15. Makaju R, Mohammed A, Thakur N.K. Scenario of extrapulmonary tuberculosis in tertiary care centre, J Nepal Health Res. Counc. 2010; 8 (16) : 48 |