ORIGINAL RESEARCH PAPER

Volume-8 | Issue-3 | March-2019 | PRINT ISSN No 2277 - 8179

INTERNATIONAL JOURNAL OF SCIENTIFIC RESEARCH

FAHR'S SYNDROME: A RARE CASE OF IDIOPATHIC BASAL GANGLIA CALCIFICATION

Radiodiagnosis

Dr. Aishwary Ambashikar

Junior Resident, Grant Medical College And Sir J.J. Group Of Hospital Mumbai- 400008

ABSTRACT

Fahr's syndrome (or Fahr's disease) involves progressive calcific deposition in the wall of blood vessels of the basal ganglia and dentate nuclei of the cerebellum in young and middle-age persons. It is occasionally associated with mental retardation and extrapyramidal symptoms. Clinically it may present with an array of movement disorders, dementia and other behavioural disturbances1. We report a case of 29-year-old female with increasing frequency of seizures. Brain CT showed symmetrical calcification in basal ganglia The clinical and radiological features in our case point towards this uncommon disorder.

KEYWORDS

Extrapyramidal, Parkinson'sdisease, intracerebral calcinosis, dysarthria.

INTRODUCTION

Fahr's syndrome also known as idiopathic basal ganglion calcification (IBGC)[2], cerebrovascular ferrocalcinosis,Fahr's intracerebral calcinosis, Fahr's disease,or Morbus Fahr is a rare neurological disorder of unknown aetiology, characterised by neuropsychiatric abnormalities, Parkinsonian or choreoathetotic-type movement disturbances, and extensive symmetrical calcification of basal ganglia and dentate nuclei in the cerebellum[2].Fahr Disease is a rare degenerative neurological disorder characterized by the presence of abnormal calcium deposition and associated cell loss in the areas of brain that control movement, including basal ganglia and cerebral cortex. It was first noted by the German neurologist Karl Theodore Fahr in 1930. The disease is often familial with autosomal dominant inheritance, but a few cases have been reported to have autosomal recessive inheritance and even sporadic cases have been reported in the literature[3]. It is believed to have autosomal dominant inheritance but a few cases have been reported to have autosomal recessive inheritance and even some sporadic cases have been reported in literature. The association between the abnormal phenotypes and abnormal genes remain unclear despite the recent mapping to chromosome 14q of a susceptible locus for Fahr Disease.

Case Report

A 29-year-old female, presented with a history of epicodic headaches in occipitals-temporal region since 3 months. Headache was intermittent, lasting 1-2 hours, Usually occurred when stressed and relieved with rest and pain killers and not associated with nausea, vomitting, photophobia and photophobia. History of hyper tension since 3 months. History of PIH 5 years ago.

On examination, the patient was hypertensive but had abnormal mental functions. He had dysarthria with cognitive impairment. The patient was conscious, but had inconsistency regarding orientation to time, place, and person. Sometimes he did not obey verbal commands and lay still with a mask-like expressionless face. Ataxia and rigidity of all four limbs was present.

There was no cranial nerve dysfunction. Motor system examination showed normal muscle mass and power with normal tendon reflexes. There was no sensory deficit. On investigation; the patient's renal profile, blood glucose, serum calcium, serum phosphorous, serum parathyroid hormone and alkaline phosphatase levels were normal. Electrocardiogram and chest radiograph did not show any abnormality. Fundus examination of the eye did not show any evidence of raised intracranial tension. Computerised tomography (CT) of brain showed symmetrycal dense calicoication in the bilateral lentiform uncle and bilateral anteroinferior cerebellar parchyama. On MRI areas symmetric blooming are noted in the bilateral basal ganglia (lentiform nucleus), bilateral cerebellar semispheres and dental nucleus on SW1 images. On the basis of history, clinical features, CT findings, and normal blood biochemistry, a diagnosis of Fahr's syndrome was made.

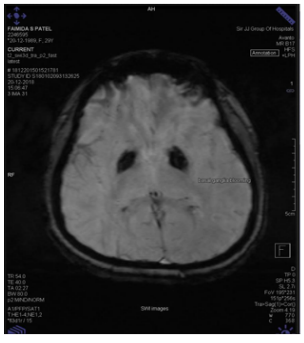

FIG 1: Basal Ganglion Blooming

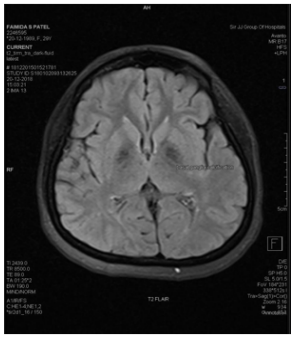

FIG 2: Basal Ganglion Calcification

DISCUSSION

Fahr's syndrome is a very rare disease with unknown prevalence, characterised by symmetrical intracranial calcification with a predilection for the basal ganglia and dentate nuclei. As the basal ganglia and dentate nuclei are always involved in a symmetrical pattern, the term Bilateral Striopallidodentate Calcinosis (BSPDC) was suggested[4].

The most common site of calcification is the globus pallidus . However additional areas of calcification are putamen, caudate nucleus, internal capsule, dentate nucleus, thalamus, cerebellum and cerebral white matter.

It is not clear whether the calcification in Fahr Disease is a metastatic deposition, secondary to local disruption of blood brain barrier, or is due to disorder of neuronal calcium metabolism.

Typical age of presentation is in middle-age between the 4th - 6th decades of life (as seen in our case), although an early onset type may also occur[5]. Symptoms of this disorder may include-deterioration of motor function, dementia, seizures, headache, dysarthria, spasticity, visual impairments, and athetosis. Fahr's syndrome can also include symptoms of Parkinson's disease such as tremors, muscle rigidity, mask-like facial appearance, shuffling gait, and a “pin-rolling” motion of the fingers.

Our case presented with cognitive impairment, speech disorder, extrapyramidal features like rigidity and mask- like face, and psychotic features.

Benke *et al*[6] studied the brain metabolism in a person with Fahr's disease who presented with predominant frontal lobe syndrome and dementia. There was a massive reduction in the glucose metabolism in both the basal ganglia and frontal lobes which correlated with the clinical picture of disinhibition and personality change. The involvement of frontal-subcortical circuits provides a hypothetical framework for the interpretation of cognitive and psychotic problems in Fahr's disease.

Making a clinical diagnosis of Fahr's syndrome relies on the combination of clinical features, brain imaging, and exclusion of other causes of intracranial calcification. Symmetrical and extensive calcification of basal ganglia, dentate nuclei, and centrum semiovale are typical and conspicuous of Fahr's syndrome.

Normal serum levels of calcium, phosphorus, alkaline phosphatase, and parathormone can help in differentiating it from the endocrine disorders like hyperparathyroidism, pseudo-hypoparathyroidism, and pseudo-pseudo-hypoparathyroidism as happened in our case. Other rare causes of scattered basal ganglia and dentate nuclei calcification are tuberous sclerosis, toxoplasmosis, syphilis, and inflammatory illness such as systemic lupus erythematosus and all these must be ruled- out in suspected cases.

There is no cure for Fahr's syndrome, nor is there a standard course of treatment. Treatment targets symptomatic support. The response to Levodopa in those with Parkinson's features is reportedly poor. Antipsychotics may be indicated in those with psychotic symptoms and behavioural problems, an anticonvulsants for the control of seizures as was done in our case.

CONCLUSION

Though Fahr's syndrome is a rare idiopathic neurodegenerative disorder, yet, with proper knowledge of its clinical manifestations and more vigilant approach, a diagnosis can be made in time. More research is required to locate and understand the action of the genes involved in this disorder. Finding these genes could lead to effective ways to treat and prevent Fahr's syndrome.

REFERENCES

1. Modrego PJ, Mojonero J, Serrano M et al. Fahr's syndrome presenting with pure and progressive presenile dementia. Neurological Sciences 2005; 26 (5); 367-9.
2. Shoyama M, Ketabata Y, Kaku T, Shinosaki K. Evaluation of regional cerebral blood flow in Fahr's disease with schizophrenia like psychosis; A case report. Am J Neuroradiol 2005; 26: 2527-9.
3. Malik R, Pandya VK, Naik D. Fahr's Disease: a rare neurodegenerative disorder. Ind J Radiol Imag 2004; 14 (4): 383-4.
4. Manyam BV. Bilateral strio-pallido-dentate calcinosis: a proposed classification of genetic and secondary causes. Mov Disorder 1990; 5 (supl): 94S.
5. Lam JSP, Fong SYY, Yiu GC, Wing YK. Fahr's disease: a differential diagnosis of frontal lobe syndrome. Hong Kong Med J 2007; 13: 75-7.
6. Benke T, Karner E, Sappi K et al. Subacute dementia and imaging correlates in a case of Fahr's disease. J Neurol Neurosurg Psychiatry 2004; 75: 1163-5.