ORIGINAL RESEARCH PAPER

Volume-7 | Issue-8 | August-2018 | PRINT ISSN No 2277 - 8179

INTERNATIONAL JOURNAL OF SCIENTIFIC RESEARCH

FETUS ACARDIUS AMORPHOUS AT TERM – A RARE ENTITY

Gynecology

Dr. Priyanka Dahiya

Assistant Professor, Kalpana Chawla Government Medical College, Karnal, Haryana.

ABSTRACT

Fetus acardius amorphous is a rare fetal malformation occurring as a consequence of TRAP sequence. Prenatal diagnosis of acardiac twin is difficult. The main differential diagnosis is with placental teratoma and is based on the degree of skeletal organization and umbilical cord formation. A 32-year old woman delivered a healthy newborn at term gestation. An oval well defined mass, covered with normal looking skin, was connected to the placenta with a two vessel umbilical cord. X-ray examination of the mass revealed the presence of vertebral column. The rarity of fetal monsters without a functioning heart is emphasized.

KEYWORDS

acardius amorphous, TRAP sequence, twin pregnancy, monochorionic

INTRODUCTION

Acardiac twin syndrome is a rare entity complicating 1% monozygotic twin pregnancies. Its incidence is 1 in 35,000 births [1] and occurs as a result of twin-to-twin transfusion syndrome occurring in monochorionic twin pregnancies with perinatal mortality as high as 50-70 % without treatment. [2] Mortality is usually due to cardiac failure or preterm labour as a result of polyhydramnios of 'pump fetus'. The pump-twin which is anatomically normal generally shows features of congestive cardiac failure. The recipient-twin exhibits lethal anomalies like acardia and is generally underdeveloped. Among various subtypes of acardiac fetuses as described by Simmonds and Gowen (acardius acephalus, acardius anceps, acardius amorphous, acardius myelancephalus and acardius acormus), acardius amorphous is rare and contributes merely 5% of cases. [3] Acardiac twin at term without any complication is generally unknown.

CASE REPORT

An unbooked 28-year old woman (G2P1L1) presented to our hospital in active labour at term. Her antenatal period was unsupervised and no investigations were avilable. On admission she was conscious oriented, her blood pressure was 130/88 mm Hg, pulse was 92 per minute, respiratory and cardiovascular examination were normal, the abdomen was overdistended with good intensity uterine contractions. Her per vaginum examination revealed fetus with vertex presentation, absent membranes with clear liqour, at +3 station. A healthy male baby weighing 2.6 kg was delivered vaginally. But even after delivery of the baby, the fundal height was corresponding to 28 weeks size uterus. Keeping the possibility of undiagnosed twin in mind, the abdominal examination was conducted but it failed to reveal fetal presentation and a smooth, regular, firm feel was present throughout. Fetal heart sound could not be heard. The per vaginum examination revealed a fully dilated cervix with absent membranes, liquor drained out, firm fleshy mass receding down with maternal bearing down efforts. Patient's bladder was catheterized and urgent ultrasonography was planned. With good maternal bearing down efforts in lithotomy position and a liberal episiotomy, a fleshy oval amorphous mass measuring 16 x 27 centimeters, with a thin cord attached in the center was delivered vaginally. A single placenta without any intervening membrane with two cords attached over fetal surface of placenta, weighing 700 grams was delivered soon after. The co-twin represented by an amorphous soft tissue mass with no cephalic or caudal structures was covered with normal skin (sparse black hair at one end) weighed 990 grams and was connected by a two-vessel umbilical cord to the placenta. Small soft tissue and cystic projections near umbilical cord insertion could not be categorized. The X-ray examination revealed few small calcified shadows arranged in linear fashion appeared like rudimentary vertebrae, single largest bone near umbilical cord insertion, was connected distally with few calcific shadows which showed no characteristic features. The ultrasound revealed that this calcified structure was surrounded by amorphous soft tissue mass. The head, heart and intra-abdominal viscera were absent. Few central echogenic shadows within tubular structures possibly showing bowel loop segment were present. Autopsy confirmed the diagnosis.

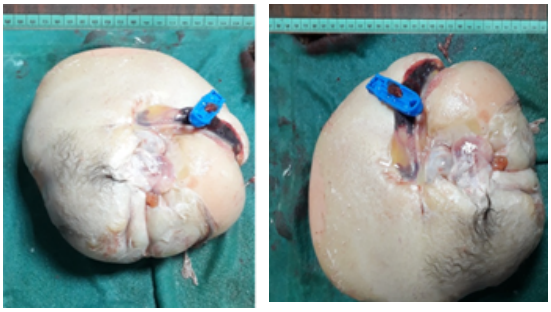

Fig 1 & 2: Showing the fetus acardius amorphous.

DISCUSSION

Acardiac anomaly sequence is a rare malformation occurring in the setting of monozygotic monochorionic twin pregnancies. Fetus acardius amorphous is the least differentiated form. Twin-reversed arterial perfusion (TRAP sequence) carries a poor prognosis with a high mortality rate of over 50% in the 'pump' twin. [7] The increased cardiac load on the normal pump twin leads to its high perinatal mortality. Serial scanning is indicated for its earlier detection with 2D/3D scans along with Doppler studies of umbilical arteries for prognostification.

Antenatal diagnosis of acardiac twin fetus though challenging, is possible as early as 9 weeks but care must be taken to not mistake an acardiac twin for a dead twin in first trimester. They look like an amorphous lump of tissue that is easily mistaken for a hydropic dead fetus, however they tend to twitch and move, despite the absence of cardiac activity. The more severe forms of acardiac twin have been misdiagnosed antenatally as placental or uterine masses or teratoma by ultrasonography. Diagnostic criteria by ultrasound usually include: absent cardiac motion, poorly defined head and trunk, increase in soft tissue mass and existence of reverse blood flow through the umbilical cord. In some cases, the diagnosis of acardia was established at autopsy.[5]

On histological analysis, only bones, cartilage, muscles and fat, blood vessels, and stroma can be identified. A single artery in the umbilical cord is seen in 50% of cases.[5] Diagnosis of fetus amorphous acardius largely depends on the presence of an umbilical cord and of cranio-caudal skeletal organization (confirmed on radiology), as was proposed by Fox and Butler-Manuel.[4]

Due to the parasitic hemodynamic dependence of the acardiac twin on the pump twin, it is important to monitor the pump twin for signs of decompensation and, if indicated, intervene by interrupting vascular supply to the acardiac twin. The goal of treatment is to maximize the pump-twin's chance of survival. The first line of treatment should be ultrasound-guided laser coagulation or radiofrequency ablation of the intrafetal vessels.[3]

Rohilla M et al reported that after exclusion of chromosomal

aberrations and malformations of the pump twin, close sonographic follow-up may be initiated.[6] If the estimated weight of the acardiac twin is less than one fourth of the pump twin, the prognosis is excellent without further therapy. The weight of an acardius may be calculated using the formula : Weight in grams = (1.2 * longest length 2)- (1.7 * longest length). This may be useful for predicting the outcome. [8]

Fetal echopsy which is a non-invasive method of fetal autopsy using ultrasound, illustrated by Balakumar et al [9] to avoid procedural obstacles for obtaining parents consent for fetal autopsy is enhancing the research methodology. Karyotyping is usually not indicated, as the condition is sporadic.

CONCLUSION

Prenatal diagnosis of acardiac twin is difficult. The possibility of a complicated acardiac twin should be considered when a malformed second twin is present even at term to prevent unsuccessful attempts at destructive procedures during labour. Placental teratoma considered in the differential diagnosis, lacks the segmental organization and umbilical cord.

REFERENCES :

[1] Moore TR, Gale S, Benirschke K. Perinatal outcome of forty-nine pregnancies complicated by acardiac twinning. Am J Obstet Gynecol 1990; 163: 907-912.
[2] Chanthasenanont A, Pongrojpaw D. Acardiac twin. J Med Assoc Thai. 2005 Nov;88(11):1721-4
[3] Wong AE, Sepulveda W. Acardiac anomaly: current issues in prenatal assessment and treatment. Prenat Diagn. 2005 Sep;25(9):796-806. 6. Schwarzler P, Ville Y, Moscosco
[4] Fox H, Butler-Manuel R. A teratoma of the placenta. J Pathol Bacteriol 1964; 88: 137-140.
[5] Kamitomo M, Kouno S, Ibuka K, Oku S, Sueyoshi K, Maeda T et al. First-trimester findings associated with twin reversed arterial perfusion sequence. Fetal Diagn Ther. 2004;19:187-190.
[6] Rohilla M, Chopra S, Suri V, Aggarwal N, Vermani N. Acardiac-acephalus twins: a report of 2 cases and review of literature. Medscape J Med. 2008;10 (8):200.
[7] Hanafy A, Peterson CM. Twin-reversed arterial perfusion (TRAP) sequence : Case reports and review of literature. Aust N Z Obstet Gynaecol 1997; 37:187.
[8] Moore TR, Gale S, Benirschke K. Perinatal outcome of forty-nine pregnancies complicated by acardiac twinning. Am J Obstet Gynecol. 1990;163:907–12.
[9] Balakumar K, Milind K, Misha K. Fetal echopsy (ultrasonographic autopsy) of an acardius myelancephalus and its correlation with antenatal ultrasonographic findings. Indian J Radiol Imaging. 2015 Oct-Dec; 25(4): 471–473.